

Isolated Complete Rupture of Left Main Bronchus after Blunt Chest Trauma

Kalliopi Athanassiadi^{1*}, Dickgreber N², Rahe-Meyer N³, Akyari P¹, Bagaev E¹, Tudorache I¹ and Haverich A¹

¹Department of Thoracic & Cardiovascular Surgery, Medical School of Hannover, Hannover, Germany

²Department of Pulmonology, Medical School of Hannover, Hannover, Germany

³Department of Anesthesiology, Medical School of Hannover, Hannover, Germany

Abstract

Blunt chest trauma resulting in rupture to the trachea and major bronchi without any concomitant vascular injury is very rare.

We present an unusual case with a complete left main bronchus rupture in a 23-year-old man after blunt chest trauma without any vascular injury and we review the literature of the last decade.

The patient was admitted at our hospital hemodynamically stable with a left tension pneumothorax. His general condition became worse after the insertion of a chest drainage and CT scan and bronchoscopy were performed on an urgent basis. After bronchoscopic confirmation of the complete transection of the left main bronchus an intubation with a double lumen tube followed and the patient was submitted on emergency thoracotomy and an end-to-end anastomosis was performed of the transected bronchial ends. The postoperative course was uneventful and in a follow up of 6 months the patient developed no complication.

In conclusion, prompt recognition of the injury, skillful airway management and early treatment greatly reduce morbidity and increase the chances of restoring normal pulmonary function.

Keywords: Complete bronchial rupture; Blunt chest trauma

Introduction

Blunt chest trauma resulting in rupture to the trachea and major bronchi without any concomitant vascular injury is very rare [1].

We report a case with a complete left main bronchus rupture in a 23-year-old man after blunt chest trauma without any vascular injury. On emergency thoracotomy an end-to-end anastomosis was performed of the transected bronchial ends.

Case Report

A 23-year-old man was admitted to a district hospital after a car accident, where he rapidly developed respiratory insufficiency concomitant with subcutaneous emphysema, but he remained hemodynamically stable. The chest X-ray demonstrated a left tension pneumothorax and a chest tube were inserted into the left pleural space without amelioration. A second chest tube was inserted without any improvement on the contrary the general condition of the patient became worse. These findings were confirmed with by a chest CT scan which revealed a collapsed left lung and a complete rupture of the left main bronchus along with rib fractures, pleural effusion and pneumomediastinum (Figure 1). The patient was intubated with a right single lumen tube and was transferred to our institution. Upon arrival the patient was hemodynamically stable. The upright PA chest X-ray showed a tension pneumothorax on the left side with a slight contra lateral deviation of the mediastinum. The superior border of the collapsed lung had fallen below the level of the left main stem bronchus, the image was interpreted as being characteristic of complete left main bronchus rupture. Based on both clinical picture and the radiological findings the patient was taken to the operating room for immediate surgical exploration and repair.

A flexible bronchoscopy through an endotracheal tube showed a complete disruption of the left mainstem bronchus approximately 2cm of the carina and avulsion of the central rings. Surgical procedure

A right double lumen tube is inserted under bronchoscopic guidance and through a left posterolateral thoracotomy along the 5th intercostal

space the left mainstem bronchus was exposed after mobilization of the left lung, the aortic arch and the left main pulmonary artery (Figure 2).

The proximal bronchial stump was 1.5cm beyond the mediastinal pleural reflection. The other hilar structures were normal. After the excision of the two non-viable rings an end to end anastomosis took place by using interrupted 4/0 PDS extramucosal sutures. The anastomosis was reinforced with parietal pleura and fibrin glue. After completion of the anastomosis the patient was ventilated via the oro-tracheal tube. A left lung laceration was also repaired. Filling saline fluid

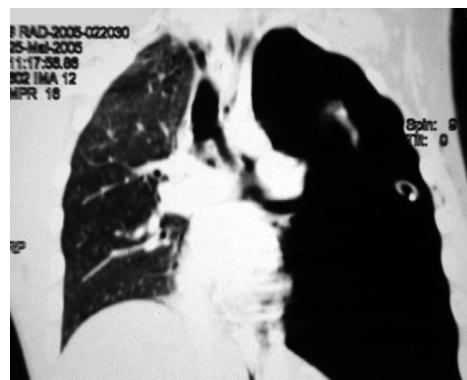

Figure 1: Computed tomography of a traumatic rupture of the left main stem bronchus.

***Corresponding author:** Kalliopi Athanassiadi, Department of Thoracic & Cardiovascular Surgery, Medical School of Hannover, Hannover, Germany, E-mail: kallatha@otenet.gr

Received August 17, 2013; **Accepted** September 17, 2013; **Published** September 19, 2013

Citation: Athanassiadi K, Dickgreber N, Rahe-Meyer N, Akyari P, Bagaev E, et al. (2013) Isolated Complete Rupture of Left Main Bronchus after Blunt Chest Trauma. Emergency Med 3: 155. doi:10.4172/2165-7548.1000155

Copyright: © 2013 Athanassiadi K, et al. This is an open-access article distributed under the terms of the Creative Commons Attribution License, which permits unrestricted use, distribution, and reproduction in any medium, provided the original author and source are credited.

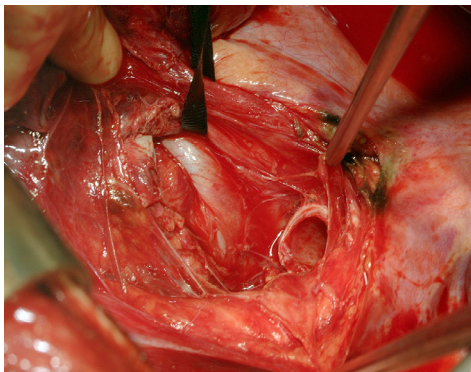


Figure 2: Intra operative picture of complete transection of the left main stem bronchus.

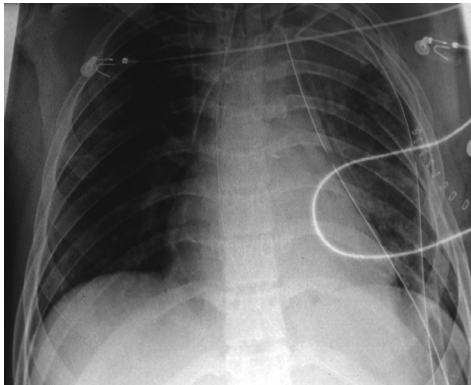


Figure 3: Postoperative Chest X-ray.

occur less frequently compared to right-sided ones, probably due to the length of left mainstem bronchus [4-13] (Table 1).

There are several theories regarding the mechanism of blunt tracheobronchial disruption [1,3,4,8,14]. The first hypothesis states that a direct impact to the chest decreases the antero posterior diameter of the thorax while increasing the transverse one. As the lungs remain always in contact with the chest wall because of the negative intrapleural pressure, they stretch laterally and produce a traction force to the carina. The second hypothesis is that rapid deceleration causes shearing of the bronchus from its points of fixation near the carina and finally, the third one state that the greatest wall tension generated within the trachea bronchial tree during periods of increased airway pressures, such as that occurring during compression of the chest wall against a closed glottis is at the carina. Bronchial rupture may be transverse between the bronchial rings, longitudinal or complex, as it was in our case with fracture of bronchial rings. Complex lesions are very rarely seen, comprising 8% of all ruptures [1]. Left mainstem bronchial ruptures are very rare if one considers that in the 28-year experience of Rossbach et al. [8] only one such rupture is present and in the review by Kiser et al. [4] were only 21 left-sided bronchial ruptures compared to 61 right ones.

Occasionally, only a few clinical signs or symptoms such as dyspnea or subcutaneous emphysema are present even with severe trachea bronchial injury.

Bronchoscopy is the main diagnostic procedure to confirm a bronchial disruption and should be performed in all patients with severe thoracic trauma [1,4,7,8,10,13,15]. In the case of a complete rupture the bronchoscope should be used as a guide during intubation either with a double lumen tube or with a single tube [4,7,13,15]. The authors did not find any need to use either ECMO or transthoracic bronchial intubation, as mentioned in other reports [11,16].

After blunt chest trauma early diagnosis of possible associated vascular, tracheobronchial and esophageal injuries should be performed because all these lesions may be caused by the same mechanism [9,10,17]. Computed tomography gives information about the lung, the great vessels, the heart and the diaphragm. As the causes of bronchial, aortic and esophagus rupture are similar, one may suggest that patients with traumatic bronchial injury routinely should undergo screening to exclude concomitant lesions of the aorta and esophagus, regardless of the presence or absence of specific symptomatology [9,10].

Cardiopulmonary bypass has been used for the repair of complex bilateral ruptures with the risk, however, of a general heparinization at other sites of injuries (fractures or cerebral lesions) in a polytrauma patient [1,15].

Operative repairs after careful airway evaluation can be often creative and unique to the given injury. Early diagnosis and treatment are essential to preserve life and to prevent complications such as airway stenosis and mediastinitis. Primary reconstruction with preservation of healthy lung parenchyma is the treatment of choice [6,18,19]. A very important factor for determining the outcome is close collaboration of anesthesiologists and surgeons. The prognosis depends more on the associated injuries, nevertheless it seems that left-sided lesions have a more favorable outcome [4].

In conclusion prompt recognition of the injury, skillful airway management and early treatment greatly reduce morbidity and increase the chances of restoring normal pulmonary function.

Author	No
Buhr et al. [5]	1
Neef [6]	2/16 tracheobronchial injuries
Mouton et al. [7]	1
Rossbach et al. [8]	1/13 tracheobronchial injuries
Pasic et al. [9]	1
Baron et al. [10]	1
Rosengarten et al. [11]	1
Rocco and Allen [12]	1
Tcherveniakov et al. [13]	5/23 tracheobronchial injuries
Total	14

Table 1: English publications of left bronchial ruptures after blunt chest trauma during the last decade.

into the chest as well as concomitant hyperventilation the anastomosis turned to be airtight, and the left lung expanded completely.

Postoperatively the patient received a bronchoscopic toilette and aggressive physiotherapy (Figure 3). In a follow up of 6 months after the accident the patient is doing well having a patent anastomosis.

Discussion

Injuries to the trachea or major bronchi, most of them associated with high-speed motor vehicle accidents, can be life threatening and have a reported incidence of 0.03% in an autopsy study of 1178 trauma deaths [2]. The majority died almost immediately. The true incidence of tracheobronchial injury is hard to establish, as a long proportion (30 to 80%) will die before reaching the hospital [3]. Left-sided injuries

References

1. Symbas PN, Justicz AG, Ricketts RR (1992) Rupture of the airways from blunt trauma: treatment of complex injuries. *Ann Thorac Surg* 54: 177-183.
2. Bertelsen S, Howitz P (1972) Injuries of the trachea and bronchi. *Thorax* 27: 188-194.
3. Roxburgh JC (1987) Rupture of the tracheobronchial tree. *Thorax* 42: 681-688.
4. Kiser AC, O'Brien SM, Detterbeck FC (2001) Blunt tracheobronchial injuries: treatment and outcomes. *Ann Thorac Surg* 71: 2059-2065.
5. Buhr J, Kelm C, Schäfer A, Henneking K (1996) [Traumatic bronchus rupture. Pathogenesis, surgical and postoperative management]. *Chirurg* 67: 277-279.
6. Neef H (1997) [Tracheobronchial injuries in blunt thoracic trauma]. *Zentralbl Chir* 122: 674-680.
7. Mouton W, Lardinois D, Würsten HU, Nachbur B, Ris HB (1997) [Blunt thoracic trauma with bronchial rupture]. *Swiss Surg* 3: 177-180.
8. Rossbach MM, Johnson SB, Gomez MA, Sako EY, Miller OL, et al. (1998) Management of major tracheobronchial injuries: a 28-year experience. *Ann Thorac Surg* 65: 182-186.
9. Pasic M, Ewert R, Engel M, Franz N, Bergs P, et al. (2000) Aortic rupture and concomitant transection of the left bronchus after blunt chest trauma. *Chest* 117: 1508-1510.
10. Baron O, Galetta D, Roussel JC, Michaud JL (2001) Left bronchial disruption and aortic rupture after blunt chest trauma. *Thorac Cardiovasc Surg* 49: 382-383.
11. Rosengarten AM, Rosalion A, Epstein J, Kelly AM (2000) Management of a patient with a complete rupture of a main bronchus in a community hospital. *Med J Aust* 172: 431-433.
12. Rocco G, Allen M (2001) Bronchial repair with pulmonary preservation for severe blunt trauma. *Thorac Cardiovasc Surg* 49: 231-233.
13. Tcherveniakov A, Tchalakov P, Tcherveniakov P (2001) Traumatic and iatrogenic lesions of the trachea and bronchi. *Eur J Cardiothorac Surg* 19: 19-24.
14. Richardson JD, Miller FB, Carrillo EH, Spain DA (1996) Complex thoracic injuries. *Surg Clinics North Am* 76: 725-748.
15. Muysoms FE, Van Swieten HA (1997) Primary repair of rupture of a main and lobar bronchus. *J Thorac Cardiovasc Surg* 113: 415-417.
16. Rupprecht H, Rümenapf G, Petermann H, Günther K (1996) Transthoracic bronchial intubation in a case of main bronchus disruption. *J Trauma* 41: 895-898.
17. Porte H, Langlois M, Maquette CH, Dupont J, Anselin JM, et al. (1998) Successful esophageal tracheobronchoplasty for combined tracheal and bronchial traumatic rupture. *J Thorac Cardiovasc Surg* 115: 1216-1218.
18. Petterson C, Deslauriers J, McClish A (1989) A classic image of complete right main bronchus avulsion. *Chest* 96: 1415-1417.
19. Reddy S, Davierwala P, Kumar P, Thakur N, Babu P, et al. (2002) Bronchial transection resulting from trivial blunt chest trauma. *Ann Thorac Surg* 73: 1948-1949.