

Case Report

Open Access

Intraductal Papillary Mucinous Carcinoma of the Pancreas Associated With Pancreas Divisum: A Very Rare Entity

Tarek Kellil, Mohamed Amine Makni, Maghrebi Houcine, Rami Rhaïem, Anis Hadded, Mohamed Sabri B'chir, Wael Rebai, Amine Daghfous, Rachid Ksantini, Faouzi Chebbi, Mohamed Juini, Montassar Kacem and Zoubair Ben Safta

Department of Digestive Surgery, La Rabta Hospital, University Hospital of Tunis, Tunis, Tunisia

*Corresponding author: Tarek Kellil, Department of Digestive Surgery, La Rabta Hospital, University Hospital of Tunis, Tunis, Tunisia, Tel: +21652743234; E-mail: kelliltarek10@gmail.com

Received Date: August 28, 2017; Accepted Date: September 22, 2017; Published Date: September 30, 2017

Copyright: © 2017 Tarek Kellil, et al. This is an open-access article distributed under the terms of the Creative Commons Attribution License, which permits unrestricted use, distribution and reproduction in any medium, provided the original author and source are credited.

Abstract

Pancreas divisum (PD) is a common congenital anomaly of the pancreas, which results from an abnormal fusion between the ventral and dorsal pancreatic ducts during fetal development. Association with Intraductal papillary mucinous neoplasm (IPMN) is extremely rare. The treatment of this entity will depend both on the malignant potential of IPMN and on the symptoms related to pancreas divisum. We report a rare case of Intraductal papillary mucinous carcinoma of the pancreas associated with pancreas divisum, one of the most difficult situations which the surgeon can be confronted to in his practice.

Keywords: Pancreas divisum; Congenital anomaly; Fetal development; Intraductal papillary; mucinous neoplasm

Introduction

Pancreas divisum (PD) is a common congenital anomaly of the pancreas, which results from an abnormal fusion between the ventral and dorsal pancreatic ducts during fetal development.

Association with Intraductal Papillary Mucinous Neoplasm (IPMN) is extremely rare. The treatment of this entity will depend both on the malignant potential of IPMN and on the symptoms related to pancreas divisum. We report a rare case of Intraductal papillary mucinous carcinoma of the pancreas associated with pancreas divisum, one of the most difficult situations which the surgeon can be confronted to in his practice.

Case Report

A 52-year old man, presented in the emergency room for epigastric pain without irradiation. The patient does not mention any exacerbating factors. He had a history of three episodes of acute non-severe pancreatitis with an initial negative etiological investigation. The patient does not report any notion of addiction to alcohol nor other substances. On examination, the patient is not febrile. No icterus was noted. The abdomen palpation found guardless epigastric sensitivity. At the biological investigation; the lipase was six times the normal level. The staging abdominal CT detected an acute pancreatitis with an increase in the size of the whole pancreas associated to an infiltration of the adjacent fat (Stage C of Balthazar). A pancreato-MRI was performed and showed a Warshaw type I pancreas divisum aspect associated with a 2.5 cm cystic lesion developed at the ventral pancreas, matching with a Branch-Duct Intraductal papillary mucinous neoplasm (BD-IPMN).

Regarding to the malignant potential of symptomatic IPMN (a young patient with a 2.5 cm BD-IPMN lesion), we decided to operate.

During the procedure, an induration at the level of the uncinat process of the pancreas was observed. This induration would probably correspond to a neoplastic process. The patient had a pancreaticoduodenectomy with a Pancreatico-gastric anastomosis. Postoperatively, a biological pancreatic fistula was detected on the 3rd day. It was treated medically by sandostatin and 'nil by mouth'. The anatomopathological examination of the surgical specimen showed an Intraductal papillary mucinous carcinoma of the ventral pancreas, associated with a complete Pancreas Divisum. The patient has been followed for 2 years. No local or metastatic recurrence was detected.

Discussion

At the beginning of the fourth week of embryonic development, the entoblast of the ventral wall of the distal portion of the anterior intestine buds and gives thickenings which condense into several sketches [1]:

- Hepatic portion on the ventral part;
- Dorsal pancreatic portion, at the origin of the dorsal pancreas;
- Two ventral pancreatic portions, right and left, but the left atrophies and there remains only a ventral portion.

During the sixth week of embryonic development, the ventral pancreatic portion migrates 270° around the mesenteric vascular axis in a clockwise direction to lie below and behind the dorsal portion. The fusion of the two portions during the seventh week of embryonic life is accompanied by a fusion of the two ductal systems draining initially the two pancreatic portions [2]. The pancreas Divisum is the result of the no or bad fusion of the ventral and dorsal portions of the pancreas, as well as of their canals, at the seventh embryonic week. Only a small area of the pancreas drains into the major papilla, the greater part drains into the minor papilla.

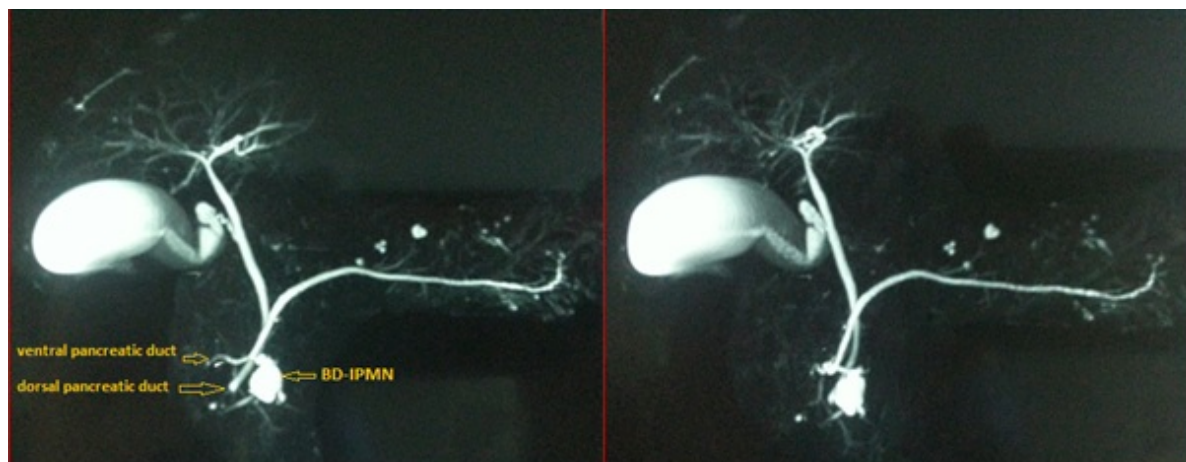


Figure 1: A pancreatico-MRI showing a Warshaw type I pancreas divisum aspect associated with a 2.5 cm cystic lesion developed at the ventral pancreas.

Pancreas Divisum is the most common congenital morphological abnormality of the pancreas.

The frequency is 5 to 10% of the autopsy series including a pancreatographic study [3], because externally, pancreas divisum appears normal.

In the series of endoscopic retrograde cholangiopancreatography (ERCP), the frequency is 0.5 to 7%, the difference with autopsy series being due to false negatives when dorsal catheterization was not performed during ERCP.

For Warshaw, there are three types of Pancreas Divisum [4]:

- A classic type: a dorsal pancreatic duct and a ventral pancreatic duct are completely divided 71%.
- A single dorsal pancreatic duct 23% of cases.
- Two pancreatic ducts, dorsal and ventral, joined by a filiform anastomosis (incomplete pancreas divisum) 6% of the cases.

The diagnosis of pancreas divisum is based on imaging:

- Endoscopic retrograde Pancreatography; Catheterizing both the main papilla, which during the pancreatography shows a miniature ventral segment with a ventral canal of reduced length and gauge, and the accessory papilla (which should be looked for 1 to 2 centimeters above and to the right of the Main papilla), which during opacification, reveals a main pancreatic duct draining most of the pancreatic gland.
- Pancreatography by Magnetic Resonance; Showing a dorsal pancreatic duct intersecting the common bile duct with the same caliber as the proximal principal pancreatic duct.

The association of IPMN and pancreas divisum is rare. Nishi Takeshi [5] by a review of the literature published in 2015 summarized 15 cases of IPMN associated with a pancreas divisum. The clinical features of these cases were concluded by a clear female predominance (80%), the Prevalence of pancreas divisum type I (80%), the predominant tumor localization in the dorsal pancreas (80%), the prevalence of BD-IPMN (60%). Only two patients presented with an acute pancreatitis [6,7]. Acute pancreatitis in IPMN results from ductal obstruction due to accumulation of mucin. In the Pancreas Divisum,

acute pancreatitis is the cause of a relative stenosis of the minor papilla. Because the ventral pancreas is drained into the major papilla, ventral pancreatitis is extremely rare in patients with pancreas divisum [8]. In addition, the relative stenosis of the minor papilla appears to be a predisposing factor in the development of pancreatic cancer by promoting the occurrence of recurrent pancreatitis [9]. So the majority of cancers developed on Pancreas Divisum are in the dorsal pancreas.

The treatment of IPMN associated with pancreas Divisum will depend both on the malignant potential of BD-IPMN and on the symptoms related to pancreas divisum.

For our 52 year old patient; who has a 2.5 cm BD-IPMN lesion; a surgical resection was indicated referring to the international consensus guidelines of IPMN [10]. Limited resections or even focal non-anatomic resections (excision, enucleation, uncinectomy) may be considered for BD-IPMN without suspicion of malignancy. However, such procedures may be associated with a higher incidence of pancreatic fistulae and risk of recurrence from potentially residual neoplasm. Pancreaticoduodenectomy was performed in our patient because curative pancreatectomy provides a favorable prognosis for patients with IPMC [10,11].

Conclusion

The relative stenosis of the minor papilla observed in Pancreas Divisum appears to be a predisposing factor in the development of ordinal pancreatic cancer in the dorsal part of the pancreas, but the relationship between pancreas divisum and IPMN is currently unclear. A large case series study would be needed to clarify the etiology of IPMN arising in patients with pancreas divisum.

Consent

Written informed consent was obtained from the patient for publication of this case report and any accompanying images.

References

1. Sarles J, Sahel J, Leandri R, Salasc B, Renet S (1982) Surgical treatment of pancreas divisum. *Chirurgie. Mémoires de l'Académie de chirurgie* 108: 796.
2. Varshney S, Johnson CD (1999) Pancreas divisum. *International journal of pancreatology* 25: 135-141.
3. Guelrud M (1996) The incidence of pancreas divisum in children. *Gastrointestinal endoscopy* 43: 83-84.
4. Warshaw AL, Simeone JF, Schapiro RH, Warshaw B (1990) Evaluation and treatment of the dominant dorsal duct syndrome (pancreas divisum redefined). *The American Journal of Surgery* 159: 59-66.
5. Nishi T, Kawabata Y, Ishikawa N, Araki A, Yano S, et al. (2015) Intraductal papillary mucinous carcinoma of the pancreas associated with pancreas divisum: a case report and review of the literature. *BMC gastroenterology* 15: 78.
6. Scatton O, Sauvanet A, Cazals-Hatem D, Vullierme MP, Ruszniewski P (2006) Dorsal pancreatectomy: an embryology-based resection. *Journal of gastrointestinal surgery* 10: 434-438.
7. Nakagawa Y, Yamauchi M, Ogawa R, Watada M, Mizukami K, et al. (2013) Complete pancreas divisum with patulous minor papilla complicated by multifocal branch-duct intraductal papillary mucinous neoplasms. *Endoscopy* 45: E199-E200.
8. Saltzberg DM, Schreiber JB, Smith K, Cameron JL (1990) Isolated ventral pancreatitis in a patient with pancreas divisum. *American Journal of Gastroenterology* 85.
9. Siegel J, Yatto R (1993) Re: Pancreatic duct obstruction as a potential etiology of pancreatic adenocarcinoma: a clue from pancreas divisum. *The American journal of gastroenterology* 88: 1288.
10. Tanaka M, Castillo C, Adsay V, Chari S, Falconi M, et al. (2012) International consensus guidelines 2012 for the management of IPMN and MCN of the pancreas. *Pancreatology* 12: 183-197.
11. Wada K, Kozarek RA, Traverso LW. Outcomes following resection of invasive and noninvasive intraductal papillary mucinous neoplasms of the pancreas. *The American journal of surgery* 189: 632-637.