

Internal Limiting Membrane Closure of Idiopathic Macular Hole

Mohamed Farouk Abdelkader* and Hossam Mohamed Moharram

Department of Ophthalmology, Minia University, Egypt

*Corresponding author: Mohamed Farouk Abdelkader, Faculty of Medicine, Minia University, Minya, Egypt, Tel: +201280677577; E-mail: mfarouk531@gmail.com, mohamed.osman@mu.edu.eg

Received date: October 16, 2016; Accepted date: December 12, 2016; Published date: December 16, 2016

Copyright: © 2016 Abdelkader MF, et al. This is an open-access article distributed under the terms of the Creative Commons Attribution License, which permits unrestricted use, distribution, and reproduction in any medium, provided the original author and source are credited.

Abstract

Purpose: To evaluate the efficacy and safety of combined phacoemulsification and 23gauge pars plana vitrectomy with Brilliant blue-G (BBG)-assisted ILM peeling in idiopathic macular hole surgery with closure of the hole by an inverted ILM flap.

Design: Prospective and interventional case series.

Methods: 23 eyes with large (>400 µm) idiopathic macular hole treated by phacoemulsification with posterior chamber IOL and 23-gauge vitrectomy with BBG-assisted ILM peeling with closure of the hole by inverted flap of ILM. Patients were followed up for the 12 months. Outcomes were evaluated in terms of visual improvement, macular hole closure and complications.

Results: In 22 (95.6%) patients, the macular hole was closed (21 eye with single procedure and one eye with second surgery), and visual improvement occurred in 19 eyes (82.6%). There were no intraoperative complications. Two patients developed post-operative glaucoma which required medication for a few weeks.

Conclusion: Combined phacoemulsification and 23-gauge pars plana vitrectomy with inverted ILM flap technique using BBG stain and SF6 as retinal tamponade provides good anatomic and visual outcomes in cases of large idiopathic macular holes after one operative interference.

Keywords: Full thickness idiopathic macular hole; BBG stain; ILM flap; Viscoat; Combined phaco-vitrectomy

Introduction

Idiopathic full-thickness macular hole (FTMH) is a full-thickness defect of the neurosensory tissue of the fovea leading to loss of central vision. It occurs most commonly above the age of 55 years and 3-31% of affected people develop a FTMH in both eyes [1,2].

Kelly and Wendel first reported pars plana vitrectomy, posterior vitreous removal, gas tamponade, and post-operative facedown positioning for idiopathic FTMH closure [3]. Leisenhoff et al. reported that peeling of ILM could minimize the tangential forces and increase the macular hole closure rates [4]. Michalewska et al. described the technique of inverted ILM flap for large macular holes with good anatomical and functional results [5].

Aim of the Work

The aim of this work is to evaluate the efficacy and safety of combined phacoemulsification with posterior chamber IOL and 23-gauge pars plana vitrectomy with Brilliant blue - G (BBG)-assisted ILM peeling in idiopathic macular hole surgery with closure of the hole by an inverted ILM flap.

Patients and Methods

The study is a prospective and interventional case series. Patients with large idiopathic FTMHs (minimum hole diameter >400 µm) were enrolled in this study in Al-Minia University Hospital during the period from July 2013 to December 2014. All eyes were followed up for a period of 12 months. An informed consent about the risks and benefits of the surgery was obtained from all patients. An ethical approval was obtained from the ethical committee of the faculty of medicine, Al-Minia University. The procedure adhered to the tenets of the Declaration of Helsinki.

Twenty-three eyes of 23 patients with large (minimum hole diameter > 400 µm) idiopathic FTMH of stage 3 or 4 were included in the study. Eyes with previous intraocular surgery, any vitreoretinal procedure, trauma, high myopia (6 dioptres or more), retinal vascular occlusions, diabetic retinopathy, uveitis, age-related macular degeneration, optic atrophy, glaucoma, dense cataract, or corneal opacity were excluded.

All patients were subjected to complete ophthalmic examinations, including history taking, best-corrected visual acuity (BCVA), slit lamp examination, intraocular pressure measurement by applanation and fundus examination by indirect ophthalmoscopy and slit-lamp biomicroscopy using +78D Volk lens. Optical coherence tomography (OCT) examination was performed before and after surgery in all eyes using spectral-domain OCT (Cirrus HD OCT, Carl Zeiss, Germany) to confirm the preoperative diagnosis of FTMH and the postoperative closure of the macular hole. OCT examinations were done

postoperatively on the 1st, 3rd, 6th, and 12th month. Biometry (Compact touch, Quantal Medical, France) for IOL power calculation was performed in all eyes. The BCVA was measured by decimal acuity and converted to the logarithm of the minimal angle of resolution (Log MAR) for statistical analysis.

Macular hole closure was defined as the absence of a neurosensory defect in the fovea seen by ophthalmoscopy and confirmed by OCT, and this was considered as an anatomical success. Functional success was defined as an increase in the BCVA of two lines or more.

Surgical procedure

All eyes included in this study were treated with combined phacoemulsification and 23gauge pars plana vitrectomy under general anesthesia. The surgical technique consisted of 2.8 mm clear corneal incision phacoemulsification with one-piece hydrophobic acrylic posterior chamber intraocular lens (PC-IOL) in the capsular bag followed by 23-Gauge pars plana vitrectomy.

Core vitrectomy was done, and triamcinolone acetonide was injected into the vitreous cavity followed by posterior hyaloid separation using the vitrectomy cutter with active aspiration. Peripheral vitrectomy was also done, helped by scleral depression. Epiretinal membranes, if present, were removed with forceps.

Brilliant blue G dye (ILM blue, D.R.O.C, Netherland) was injected into the fluid filled vitreous cavity and was left for about 20 seconds. Excess dye was actively aspirated with the vitrectomy cutter followed by ILM peel using tanoscrafer and ILM forceps (D.R.O.C, Netherland) for at least 2 DD around the fovea. During the circumferential peel, the ILM was not removed completely from the retina but was left attached to the edge of the macular hole (Figure 1). The peeled ILM was adequately trimmed and a small amount of viscoat (Alcon, Fort Worth, TX, USA) was applied to the edges of the macular hole in a circular manner to act as an adhesive. The trimmed ILM flap was then massaged gently over the macular hole from all sides until a thin layer of ILM covered the macular hole. This was followed by fluid-air exchange with 25% SF6 gas. Postoperative face down positioning for 7 days was adopted. Postoperatively, patients were examined in the 1st day, 1st week, 2nd week, 1st month, and then monthly till the end of the follow up period of 12 months.

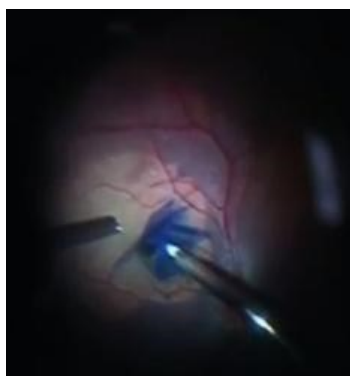

Figure 1: BBG-stained ILM flap over idiopathic macular hole.

Patients age, crystalline lens status, macular hole size, duration of symptoms, and preoperative BCVA were the main preoperative data

considered. Postoperative data included hole closure, BCVA, and postoperative complications.

Statistical method

The collected data were coded, tabulated, and statistically analyzed using SPSS program (Statistical Package for Social Sciences) software version 20.

Descriptive statistics were done for numerical data by mean, standard deviation, and minimum & maximum of the range, while they were done for categorical data by number and percentage. The level of significance was taken at (P value<0.05).

Results

This study included 23 eyes of 23 patients. Fourteen patients (60.9 %) were females and 9 patients (39.1 %) were males. The mean age was 67 ± 3.57 years (range, 60-74 years). Nine patients had incipient cataract (39.1%) which did not interfere with accurate fundus examination and good quality OCT. The macular hole was graded as stage 3 in 13 eyes (56.5%) and stage 4 in 10 eyes (43.5%). The mean minimal linear diameter of macular hole was $686.09 \pm 143.03 \mu\text{m}$ (range, 512-1024 μm) (Figure 2). The mean duration of ocular symptoms was 6 ± 4.28 months (range, 2-18 months). The mean preoperative BCVA was 1013 ± 0.11 Log MAR (range, 1-1.3). The follow up period in all eyes was 12 months (Table 1).

Variables	Descriptive statistics
Age (years):	
Range	(60-74)
Mean \pm SD	67.13 ± 3.57
Sex: n (%)	
Male	9 (39.1%)
Female	14 (60.9%)
Incipient cataract: n (%)	9 (39.1%)
Clear crystalline lens: n (%)	14 (60.9%)
Duration of macular hole preoperatively (months):	
Range	(2-18)
Mean \pm SD	6 ± 4.28
Preoperative stage of macular hole: n (%)	
Stage III	13 (56.5%)
Stage IV	10 (43.5%)
Minimal diameter of macular hole: (μm)	
Range	(513-1024)
Mean \pm SD	686.09 ± 143.03
Preoperative BCVA: (Log MAR) Range.	(1-1.3)
Mean \pm SD	1.13 ± 0.11
Postoperative BCVA: (Log MAR)	

Range	(0.2-1.3)
Mean ± SD	0.69 ± 0.31
Postoperative state of hole: n (%)	
Closed	22 (95.7%)
Persisted	1 (4.3%)

Table 1: Clinical characteristics of patients with FTMHs.

In 21 eyes (91%), the macular hole was closed with a single surgical procedure, and the hole persisted in 2 patients who were re-operated upon in the 6th month by ILM free graft and the hole was closed in one of them and persisted in the other. Those two patients had the largest size of macular hole (minimal hole diameter of more than 1000 μm), the longest duration of symptoms (15-18 months) and age above 70 years. So, the total anatomic success was 95.7% (22 eyes) at the end of the follow up period of 12 months (Figure 3). Macular hole closure was noted within the first month postoperatively.

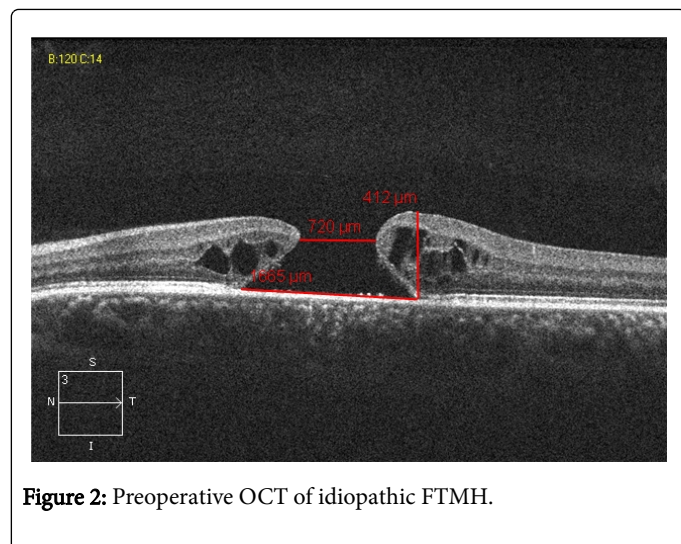


Figure 2: Preoperative OCT of idiopathic FTMH.

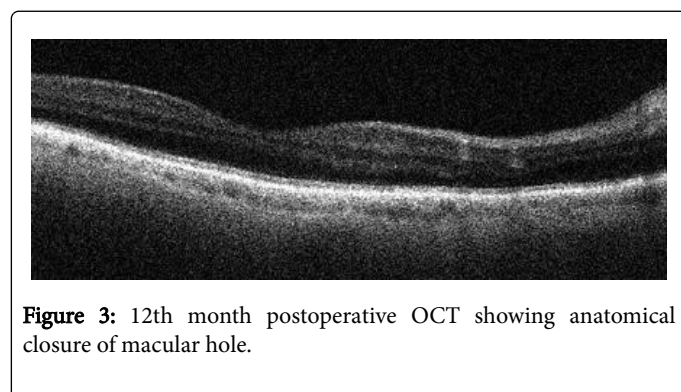


Figure 3: 12th month postoperative OCT showing anatomical closure of macular hole.

The mean of postoperative BCVA was 0.69 ± 0.31 Log MAR. The difference between the preoperative BCVA (mean 1.13 ± 0.110 LOG MAR) and the postoperative BCVA (mean 0.69 ± 0.31 Log MAR) was found to be significant (p<0.001) (Table 2).

	Preoperative	Postoperative	P value
VA			< 0.001*

Range.	(1-1.3)	(0.2-1.3)	
Mean ± SD	1.13 ± 0.11	0.69 ± 0.31	

Table 2: Comparison between preoperative and the postoperative BCVA.

There is a negative correlation between the duration of symptoms and the postoperative visual acuity (Table 3). The overall functional success was achieved in 19 eyes (82.6 %). The four patients who showed no functional success did not show deterioration of BCVA from the preoperative level.

	Duration of macular hole preoperatively	
	R	P value
Postoperative VA	-0.713	< 0.001*

Table 3: Correlation between preoperative duration of macular hole and the postoperative BCVA.

There was no intraoperative or postoperative vision threatening complications such as retinal tears, retinal detachment, or endophthalmitis. Five eyes (21.7%) developed posterior capsular opacification and treated by Nd:YAG posterior capsulotomy between 6-9 months of follow up. Two patients (8.7%) developed postoperative intraocular pressure increase, which was controlled by a combination of timolol and dorzolamide eye drops for a few weeks and none of them required surgery to reduce the intraocular pressure. Few retinal petechial hemorrhages occurred while peeling the ILM in 5 eyes (21.7%). No ILM flap detachment from the macular hole occurred during surgery.

Discussion

The Vitrectomy for Treatment of Macular Hole Study Group showed a clear benefit in closure rates and final visual acuity with pars plana vitrectomy versus observation for stage 3 and 4 macular hole [6].

Pars plana vitrectomy with ILM peeling for idiopathic macular hole relieves both the prefoveal vitreous traction and the tangential traction caused by the ILM, and improves the postoperative visual results, as it prevents the formation of epi-retinal membranes (ERM) caused by glial cell proliferation for which the ILM serves as a scaffold which may lead to postoperative macular hole reopening [7,8]. In this study, no case of postoperative macular hole-reopening occurred during the follow-up period of 12 months.

ILM is an optically clear membrane at the vitreoretinal interface. In this study, the visualization and peeling of ILM was facilitated by the use of BBG stain which increased the contrast between ILM and surrounding retina allowing meticulous creation of ILM flap. BBG stained ILM effectively and rapidly in a fluid-filled eye with a single application, and the excess dye was easily removed by the vitrectomy cutter with active aspiration. Histological and electroretinogram studies showed that BBG had no major toxic effects on the retina [9,10].

Viscoat is a dispersive low molecular weight viscoelastic material formed of a mixture of sodium hyaluronate and chondroitin sulphate. It is commonly used to protect the corneal endothelial cells during phacoemulsification. In this study, viscoat was used as an adhesive to

ensure good apposition of the adequately trimmed ILM flap to the macular hole to avoid frequent attempts to reposition ILM flap over the hole especially during fluid-air exchange. Also, this allows covering the hole with adequate ILM flap rather than packing the hole with a rolled segment of ILM flap to get a more physiological heading of the macular hole without inducing over gliosis. Viscoat can be left in place without causing retinal toxicity [11].

Michalewska et al. first introduced the inverted ILM flap technique for idiopathic macular holes with 100% closure rate and improved postoperative visual acuity. The inverted ILM flap may stimulate the proliferation of glial cells that fill and enhance the closure of macular holes. They assumed that glial cell proliferation produced an environment for the photoreceptors to assume new positions in direct proximity to the fovea improving the postoperative visual acuity [5].

In this study, 23 eyes with large idiopathic FTHMs were included and the rate of macular hole closure was 95.7% with improvement in the mean visual acuity from 1.13 to 0.69 (Log MAR) at the end of follow up period of 12 months. The findings in this study was comparable that of Michalewska et al. who compared 2 groups of eyes with large idiopathic macular holes, one group treated by pars plana vitrectomy with ILM peeling and the second group of eyes treated by the inverted ILM flap technique. In the second group, macular closure rate was 100% with visual improvement from 0.078 to 0.28 (decimal acuity) at the end of 12 month follow up period. However, Michalewska et al. used trypan blue to stain the ILM and did not combine phacoemulsification with vitrectomy in all eyes. In this study, BBG was used because there are many studies in literature comparing brilliant blue G and trypan blue as regards the safety and staining properties and they concluded that brilliant blue G is superior to trypan blue [12-14].

In Michalewska's study, they had to re-operate by phacoemulsification on 3 patients because of cataract between 7-11 months of their study and in addition, 2 patients were pseudopkalic before vitrectomy. In this study, no patient needed to be re-operated upon because of cataract which helped to reduce time and cost, allowed rapid patient rehabilitation, and avoided the patients another operative interference.

Also, Michalewska et al. reported a detachment of the inverted ILM flap during fluid-air exchange in 7 of the 50 eyes (14%) which did not occur in this study because of the use of viscoat which helped to stabilize the ILM flap during fluid-air exchange.

Song, et al. used viscoat to cover large myopic macular holes without retinal detachment with a single layer of ILM. They studied 15 eyes for a period of 6 months and reported a closure rate of 100% with the BCVA improved in 10 eyes (66.7%), remained the same in 3 eyes (20%), and worsened in 2 eyes (13.3%). In their procedure, they used viscoat inside the hole before injection of indocyanine green ICG to protect the retina from its potential toxic effect. Then, they removed it with excess ICG dye. During ILM peeling, they removed the lower ILM and covered the myopic hole with single layer from upper ILM after application of viscoat around the macular hole edges as an adhesive and another amount of viscoat was placed over the ILM flap [14]. In this study, 23 eyes with idiopathic macular hole were studied for 12 months with the use of BBG and a circumferential flap of adequately trimmed ILM was adhered to the hole by the application of a small amount of viscoat all around the edges of the hole. No need to apply an extra amount of viscoat over the ILM flap as a ballast.

Prabhushanker and Kumar showed a closure rate of 100% with visual improvement in cases of idiopathic FTMHs larger than 700 μm of minimum hole diameter. However, they investigated only five eyes for a period of six months [15]. Other studies in the literature showed good results with ILM flap in myopic and traumatic macular holes [16-19]. Although the pathogenesis of idiopathic macular holes seems to be different from myopic and traumatic macular holes, the results of this study are comparable to these studies investigating the same technique in myopic and traumatic macular holes. This indicates that the inverted ILM flap technique, through stimulation glial cell proliferation, may help to close macular holes of different types.

In this study, the factors associated with non-closure of the macular hole after one surgery were long duration of symptoms of more than one year, minimum hole diameter of more than 1000 μm , age above 70 years and poor preoperative visual acuity.

In this study, phacoemulsification was combined with 23-G pars plana vitrectomy because there is a significant probability that visually impairing cataract will occur in the postoperative period after vitrectomy, and as a result, many patients will require subsequent cataract surgery [20-22]. Also, idiopathic macular holes occur in elderly patients in whom the incidence of cataract is high. So, this combined procedure saved time and cost, allowed rapid patient rehabilitation, and saved the patient another operative interference. Also, combining phacoemulsification with pars plana vitrectomy allowed better shaving of the vitreous base without the risk of touching the crystalline lens.

In conclusion, combined phacoemulsification and 23-gauge pars plana vitrectomy with inverted ILM flap technique using BBG stain, viscoat as an adhesive to the ILM flap and SF6 as retinal tamponade provides good anatomic and visual outcomes in cases of large idiopathic macular holes after one operative interference.

References

1. Freeman WR (1993) Vitrectomy surgery for full-thickness macular holes. *Am J Ophthalmol* 116: 233-235.
2. Kumar A, Prakash G, Singh RP (2002) Indocyanine green enhanced maculorhexis in macular hole surgery. *Indian J Ophthalmol* 50: 123-126.
3. Kelly NE, Wendel RT (1991) Vitreous surgery for idiopathic macular holes. Results of a pilot study. *Arch of Ophthalmol* 109: 654-659.
4. Liesenhoff O, Messmer EM, Pular A, Kampik A (1996) Surgical management of complete macular foramina. *Ophthalmologie* 93: 655-659.
5. Michalewska Z, Michalewska J, Adelman RA, Nawrocki J (2010) Inverted internal limiting membrane flap technique for large macular holes. *Ophthalmology* 117: 2018-2025.
6. Freeman WR, Azen SP, Kim JW, el-Hiag W, Mishell DR, et al. (1997) Vitrectomy for the treatment of full-thickness stage 3 or 4 macular holes. Results of a multicentered randomized clinical trial. The Vitrectomy for Treatment of Macular Hole Study Group. *Arch Ophthalmol* 115:11-12.
7. Kumagai K, Furukawa M, Ogino N, Uemura A, Demizu S, et al. (2004) Vitreous surgery with and without internal limiting membrane peeling for macular hole repair. *Retina* 24: 721-727.
8. Shah GK, Rosenblatt BJ, Blinder KJ, Grand MG, Smith M (2005) Triamcinolone-assisted internal limiting membrane peeling. *Retina* 25: 972-975.
9. Enaida H, Ishibashi T (2008) Brilliant blue in vitreoretinal surgery. *Dev Ophthalmol* 42: 115-125.
10. Enaida H, Hisatomi T, Goto Y, Hata Y, Ueno A, et al. (2006) Preclinical investigation of internal limiting membrane peeling and staining using intravitreal brilliant blue G. *Retina* 26: 623-630.

11. Liesegang TJ (1990) Viscoelastic substances in ophthalmology. *Surv Ophthalmol* 34: 268-293.
12. Awaad D, Schrader I, Bartok M, Mohr A, Gabel D (2011) Comparative toxicology of brilliant blue, trypan blue and their combination together with polyethylene glycol on human pigment epithelial cells. *Invest Ophthalmol Vis Sci* 52:4085-4090.
13. Shukla D, Kelliath J, Neelakantan N, Naresh K, Ramasamey K (2011) A comparison of brilliant blue G, trypan blue and indocyanine green dyes to assist internal limiting membrane peeling during macular hole surgery. *Retina* 31: 2021-2025.
14. Ahmad CN, Shaheer M (2014) Comparison of brilliant blue G and trypan blue during vitrectomy for macular hole surgery. *Pak J Ophthalmol* 30: 227.
15. Mahalingam P, Sambhav K (2013) Surgical outcomes of inverted internal limiting membrane flap technique for large macular hole. *Ind J Ophthalmol* 61: 601-603.
16. Kuriyama S, Hayashi H, Jingami Y, Kuramoto N, Akita J, et al. (2013) Efficacy of inverted internal limiting membrane flap technique for the treatment of macular hole in high myopia. *Am J Ophthalmol* 156: 125-131.
17. Michalewska Z, Michalewski J, Dulczewska-Cichecka K, Nawrocki J (2014) Inverted internal limiting membrane flap technique for surgical repair of myopic macular holes. *Retina* 34: 664-669.
18. Song Z, Li M, Liu J, Hu X, Hu Z, et al. (2016) Viscoat assisted inverted internal limiting membrane flap technique for large macular holes associated with high myopia. *J Ophthalmol* 2016.
19. Abou Shousha MA (2016) Inverted Internal Limiting Membrane Flap for Large Traumatic Macular Holes. *Medicine (Baltimore)* 95: e2523.
20. Blankenship GW, Machemer R (1985) Long-term diabetic vitrectomy results. Report of 10 year follow-up. *Ophthalmology* 92: 503-506.
21. De Bustros S, Thompson JT, Michels R G, Enger C, Rice TA, et al. (1988) Nuclear sclerosis after vitrectomy for epiretinal membranes. *Am J Ophthalmology* 105:160-164.
22. Feng H, Adelman RA (2014) Cataract formation following vitreoretinal procedures. *Clin Ophthalmol* 8:1957-1965.