

## Interest of Topical Corticosteroid Therapy in Immune Reconstitution Inflammatory Syndrome (IRIS) in HIV Infected Subjects: Case of the Genital Herpes

Patrice Ildevert Gbery, Ecra Elidjé\*, Celestin Kouadio Ahogo, Komenan Kassi, Alexandre kouame Kouassi and Isidore Yao Kouassi  
\*Department of Dermatology of the Teaching Hospital of Treichville, Abidjan Côte d'Ivoire

Patrice Ildevert Gbery, Ecra Elidjé\*, Celestin Kouadio Ahogo, Komenan Kassi, Alexandre kouame Kouassi and Isidore Yao Kouassi  
\*Department of Dermatology of the Teaching Hospital of Treichville, Abidjan Côte d'Ivoire

\*Corresponding Author: Ecra Elidjé Joseph, Department of Dermatology of the Teaching Hospital of Treichville, Luriers 6B, 191 Abidjan, 15 BP 4 Abidjan15, Cote D'Ivoire, Tel: 0022507840978; E-mail: [jocera@hotmail.com](mailto:jocera@hotmail.com)

Received date: October 09, 2015; Accepted date: November 17, 2015; Published date: November 28, 2015

Copyright: © 2015 Gbery PI, et al. This is an open-access article distributed under the terms of the Creative Commons Attribution License, which permits unrestricted use, distribution, reproduction in any medium, provided the original author and source are credited.

### Abstract

The immune reconstitution inflammatory syndrome occurs during high active antiretroviral treatment (HAART) initiation. It can be the reactivation of an already acquired infectious pathology. It also may result from the exacerbation of a previous pathology such as the genital herpes. Analyzing two clinical cases, the authors showed diagnosis and therapeutic difficulties. In patients receiving HAART expression of chronic herpes can lead to misdiagnosis, therapeutic and inefficiency of HSV specific treatment. CD4 cell count contributes to diagnosis. In this inflammatory syndrome the authors also showed earliest healing of herpes genital ulcer when using 2 to 4 weeks of topical corticosteroid therapy. Therefore it improves the patients' quality of life.

**Keywords:** Genital herpes; Immune reconstitution inflammatory syndrome; HIV; Topical corticosteroid therapy

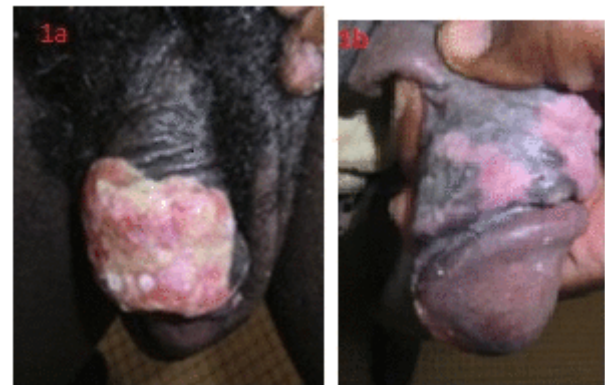### Introduction

The immune reconstitution inflammatory syndrome (IRIS) is any pathological manifestations resulting from an excessive immune reaction to infectious or non-infectious antigens. It may also result from insufficient control of those antigens; it occurs after High Active Antiretroviral Treatment (HAART) [1,2]. It may be a previously unrecognized infection which displays clinical features at the onset of an immune reconstitution. Sometime it appears as the worsening of a previously recognized and infections even in patient receiving specific therapies such as genital herpes [3,4]. It is an inflammatory reaction. Anti-inflammatory agents play an important role in IRIS management [5]. We report two clinical case with management difficulties. They revealed a reactivation and worsening of a tumoral-like genital herpes thus resulting in chronic course. Those lesions promptly healed with topical corticotherapy.

### First clinical case

A man, 46 year old consulted for ulcerated and growing skin lesions of the penis. Those lesions occurred after several flairs of genital herpes. The patient has been living with VIH1 infection for 8 months. He received HAART which was initiated at a low CD4 cell counts: about 60 cells/ mm<sup>3</sup>. He has been experiencing four times genital herpes flairs per year, during ten years. All previous flairs displayed the same features: two to five focal vesicles of the penis. He did not notice any clinical change until the moment an ultimate flair, arisen 7 months after HAART initiation, evolved in an ulcerated and tumoral-like lesion. Although the patient received acyclovir followed by valacyclovir and finally famcyclovir, no healing was observed. The ulcer was

infiltrated and became a growing tumoral-like ulcer. It was painless, and displayed lymphatic discharge (Figure 1a).

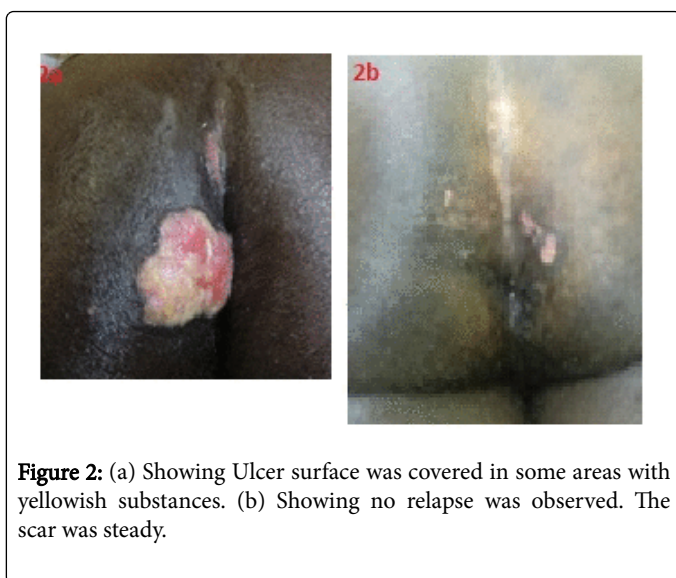


**Figure 1:** (a) Showing ulcer was infiltrated and became a growing tumoral-like ulcer. (b) Showing relapse was not observed.

Direct bacteriological exams were negatives. Blood tests were positive to HIV1, and HSV2. The CD4 cell count was 420 cells/ mm<sup>3</sup>. Then, we concluded to Immune Reconstitution Inflammatory Syndrome (IRIS). We stopped HSV specific therapies and switched to a daily topical betamethasone after antiseptic (sodium-hypochlorite at 5%) and patient was still receiving HAART. Complete healing was observed within 15 days (Fig1b). Patient was followed up during 2 months and relapse was not observed.

## Second clinical case

A man, 44 year old, HIV positive during 6 years and receiving HAART, consulted the dermatology department for a growing ulcerated and lesion of the buttock. Those lesions occurred after initial genital herpes flair in the same location. It has been evolving for 4 years, approximately 2 years after HAART initiation. The clinical manifestation progressively changed. Blister eruption progressively changed in chronic ulceration, afterwards in a growing tumoral-like and ulcerated lesion with no healing tendency. During that time, he received without any success several treatments: valacyclovir and famcyclovir. Clinically we observed a pseudo-tumoral lesion of the anterior and internal area of the left side of the buttock. The lesion had polycyclic edges. The ulcer surface was covered in some areas with yellowish substances (Figure 2a).



**Figure 2:** (a) Showing Ulcer surface was covered in some areas with yellowish substances. (b) Showing no relapse was observed. The scar was steady.

We also reported ulceration in the intergluteal fold. We did not find lymphatic nodes. The rest of the clinical examination was normal. The bacteriological exams were negative. The CD4 cell count was 900 cells/mm<sup>3</sup>. But this count at the HAART initiation was unknown. Blood test to HSV1 was positive. The diagnosis of IRIS was retained on these bases. A local treatment with topical betamethasone was applied, associated with antiseptic (sodium-hypochlorite at 5%). Complete healing was observed within 1 month (Figure 2b) after 3 months of follow up, no relapse was observed. The scar was steady.

## Discussion

The genital herpes in immune compromised, HIV positive patients was characterized by frequent flairs resulting sometime in polycyclic chronic ulcers. Tumoral evolving is uncommon. Chronic genital herpes, which mean more than one month course without healing, associated to polycyclic ulcer or tumoral features are specific to AIDS [6,7]. Moreover, in HIV positive receiving HAART the occurrence of chronic genital herpes with atypical aspect, such as hypertrophic and tumoral-like aspects, may be the manifestation of treatment failure or IRIS [8,2]. These two forms are similar and responsible for long delay of diagnosis. Because of specific treatment failures. The chronic course, in our countries where viral testing cannot be performed, could explain the possibility of HSV resistance to antiviral to be simply evoked, but not confirmed. These could explain the treatment change in the 2 cases by the clinicians switching from acyclovir to famcyclovir. But, a good disease history taken and analysis of patient

medical records allow making the differential diagnosis between chronic genital herpes in positive HIV classified AIDS and HSV resistance to antiviral treatment. The IRIS can occur early mostly within 3 months following HAART initiation associated with an active infection, sometime subclinical or currently treated infection, whether lateley over 12 months in the cases of sequestered antigen [5]. So, IRIS diagnosis can be retained on the basis of atypical evolution, CD4 cells count rising, accompanying this immune reconstitution which was observed in our two patients. The viral load was not financially accessible. Sometimes, therapeutic approach in the IRIS is difficult to control by only anti-infectious agents and anti-viral. In fact, it was an inflammatory syndrome in which anti-inflammatory agents like topical corticosteroids were needed. These corticosteroid agents have not only an anti-inflammatory action, but also an anti-proliferative action. The latest was already used in hyper-growing chronic ulcers associated with lack of healing. The risk of infections represents the main limits for the choice of management by topical corticosteroid. We did not experience such problem. In hypertrophic tumoral-like genital herpes lesions, agents like imiquimod have already been used with success [9]. Regarding our patients, the inefficiency of antiviral in spite of HAART, led to direct the diagnosis in favor of IRIS. Applying daily topical betamethasone because for its anti-inflammatory and antiproliferative actions were useful. This led to complete wound healing (fig1b and 2b) after 2-4 weeks of treatment. In our knowledge, this management was not yet used. These two case reports showed that this topical approach is easier in practice, less expensive, and contributes to improve quickly the patient life quality by fast healing of post herpetic lesions.

## Conclusion

The tumoral-like aspect of genital herpes may be the manifestation of immune reconstitution in HIV infected patients. This form resists to antiviral agents for HSV infections and favorably heals under topical corticosteroid agents.

## References

1. Walker NF, Scriven J, Meintjes G, Wilkinson RJ (2015) Immune reconstitution inflammatory syndrome in HIV-infected patients. *HIV AIDS (Auckl)* 12: 49-64.
2. Soria A, Canestri A, Bournerias I, et al (2009) Lupus discoïde chronique, une nouvelle manifestation cutanée de la reconstitution immunitaire au cours de l'infection par le virus de l'immunodéficience humaine. *La Presse Médicale* 38: 1541-1543.
3. Couppié P, Sarazin F, Clyti E, El Guedj M, Vaz T, et al. (2006) Increased incidence of genital herpes after HAART initiation: a frequent presentation of immune reconstitution inflammatory syndrome (IRIS) in HIV-infected patients. *AIDS Patient Care STDS* 20 :143-145.
4. Sarazin F, Nacher M, Toure Y, et al. (2011) Manifestations dermatologiques associées au syndrome de restauration immunitaire du patient VIH+ débutant un traitement antirétroviral : étude rétrospective en Guyane française. *Bull Acad Natle Med* 195: 561-575.
5. Weiss L (2007) Syndrome de restauration immunitaire (IRIS) au cours du traitement de l'infection par le VIH. In Girard PM, Katlama C, Pialoux G. *VIH: manifestations cliniques de l'infection à VIH et du SIDA Paris*: Doin: 445-467.
6. Phiri S, Zadrozny S, Weiss HA, Martinson F, Nyirenda N et al. (2013) Etiology of genital ulcer disease and association with HIV infection in Malawi. *Sex Transm Dis* 40: 923-928.
7. Eholié SP, Girard PM (2009) *Mémento thérapeutique du VIH/SIDA en Afrique*: 2. Rueil-Malmaison:Doin.
8. Chakrabarti LA, Lortholary O (2015) IRIS: a paradoxical inflammatory reaction in patients treated simultaneously for tuberculosis and HIV. *Med Sci (Paris)* 31 :53-59.

9. McKendry A, Narayana S, Browne R (2014) Atypical presentations of genital herpes simplex virus in HIV-1 and HIV-2 effectively treated by imiquimod. *Int J STD AIDS* 9: 98-99.