

## Inflammatory Fibroid Polyps of Large Bowel with PDGFRA Mutation

Kanazu Ariyasu<sup>1</sup>, Riko Kitazawa<sup>1,2</sup>, Ryuma Haraguchi<sup>1</sup>, Yasuo Ueda<sup>1,2</sup>, Yukino Kawanami<sup>1</sup>, Yukiko Nishi<sup>1</sup>, Yuri Kameoka<sup>1</sup>, Yosuke Mizuno<sup>1,2</sup> and Sohei Kitazawa<sup>1\*</sup>

<sup>1</sup>Department of Molecular Pathology, Ehime University Graduate School of Medicine, Toon City, Ehime 791-0295, Japan

<sup>2</sup>Division of Diagnostic Pathology, Ehime University Hospital, Shitsukawa 454, Toon City, Ehime 791-0295, Japan

\*Corresponding author: Sohei Kitazawa, Department of Molecular Pathology, Ehime University Graduate School of Medicine, Toon City, Ehime 791-0295, Japan, Tel: +0899605175; E-mail: kitazawa@m.ehime-u.ac.jp

Rec date: Nov 07, 2015; Acc date: Feb 15, 2016; Pub date: Feb 18, 2016

Copyright: © 2015 Ariyasu K, et al. This is an open-access article distributed under the terms of the Creative Commons Attribution License, which permits unrestricted use, distribution, and reproduction in any medium, provided the original author and source are credited.

### Abstract

The presence of the platelet-derived growth factor receptor  $\alpha$  (PDGFRA) gene mutation was examined in 2 cases of inflammatory fibroid polyp (IFP) in the large bowel. Immunohistochemical analysis of PDGFRA revealed one positive (Case 1) and one negative (Case 2) IFP. The lesions were then selectively microdissected from paraffin-embedded specimens, based on typical histological features showing bland spindled cells arranged in whorls or in onionskin-like fashion around blood vessels or mucosal glands with eosinophilic cells. Case 1 carried a deletion with additional missense mutation causing frameshift-nonsense mutation in exon 14; Case 2 carried a missense mutation in exon 18. These findings confirmed that IFPs in the large bowel, albeit very rare, also share genetic alterations of PDGFRA similar to those in other gastrointestinal IFPs.

### Introduction

Inflammatory fibroid polyps (IFPs) are rare, benign lesion that arise throughout the gastrointestinal tract, mostly in the stomach (0.1-3.0 % of all gastric polyps) and small intestine, and are typically composed of fibrovascular tissue infiltrated by inflammatory cells including eosinophils and mast cells. Although the pathogenesis of IFPs is still controversial and their morphologic features often vary, the recent finding of frequent mutations in platelet-derived growth factor receptor  $\alpha$  (PDGFRA) in gastrointestinal IFPs supports their neoplastic etiology. Here, we describe the molecular pathological features of two cases of IFPs in the large bowel that carry genetic alteration of the PDGFRA gene [1-4].

### Case Presentation

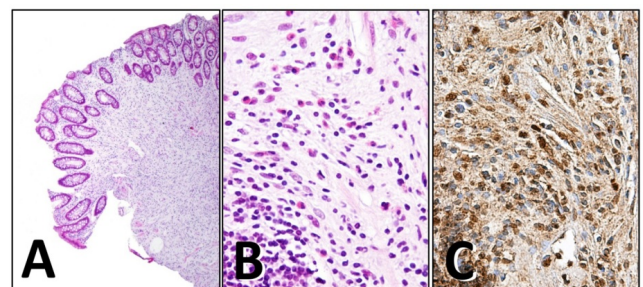
#### Case 1

A polypoid lesion was disclosed in the ascending colon of a man in his early 50s undergoing total colonoscopy for routine examination. He has no family background of gastrointestinal polyposis. Histopathological analysis of a specimen of the endoscopically resected lesion revealed numerous CD34-positive spindled-shaped cells arranged in whorls around blood vessels and mucosal glands with abundant eosinophilic cells (Figure 1A (HE, x20), and B, (HE, x400)), leading to the diagnosis of IFP (Figure 1).

#### Case 2

A polypoid lesion was disclosed by endoscopic examination in the rectum of a woman in her late 70s, who had consulted a local hospital with the chief complaint of melena. Histopathological examination of the lesion revealed a dense bundle of proliferating CD34-positive spindle-shaped cells with eosinophilic cells beneath the surface of the epithelial lining (Figure 2A (HE, x20), and B, (HE, x400)), leading to the diagnosis of IFP.

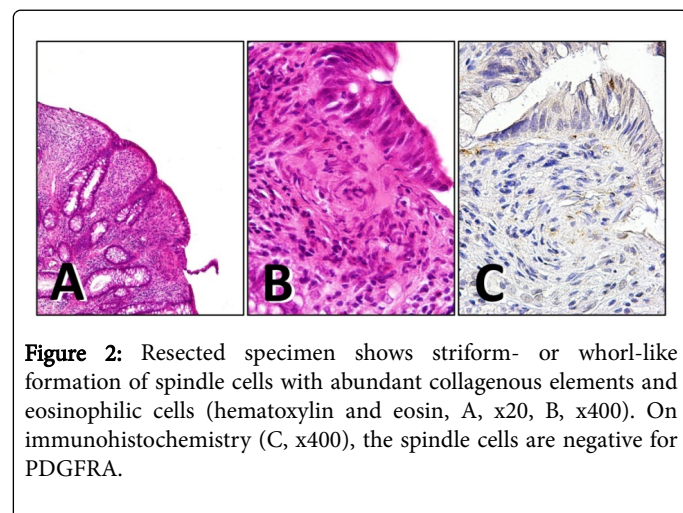
Specimens from both cases immunohistochemically stained for PDGFRA with the use of an anti-PDGFRA antibody (Cell Signaling Technology, Danvers, MA, cat. #3164) showed positive reaction for Case 1 (Figure 1C, PDGFRA, x400), and negative for Case 2 (Figure 2C, PDGFRA, x400) (Figure 2).



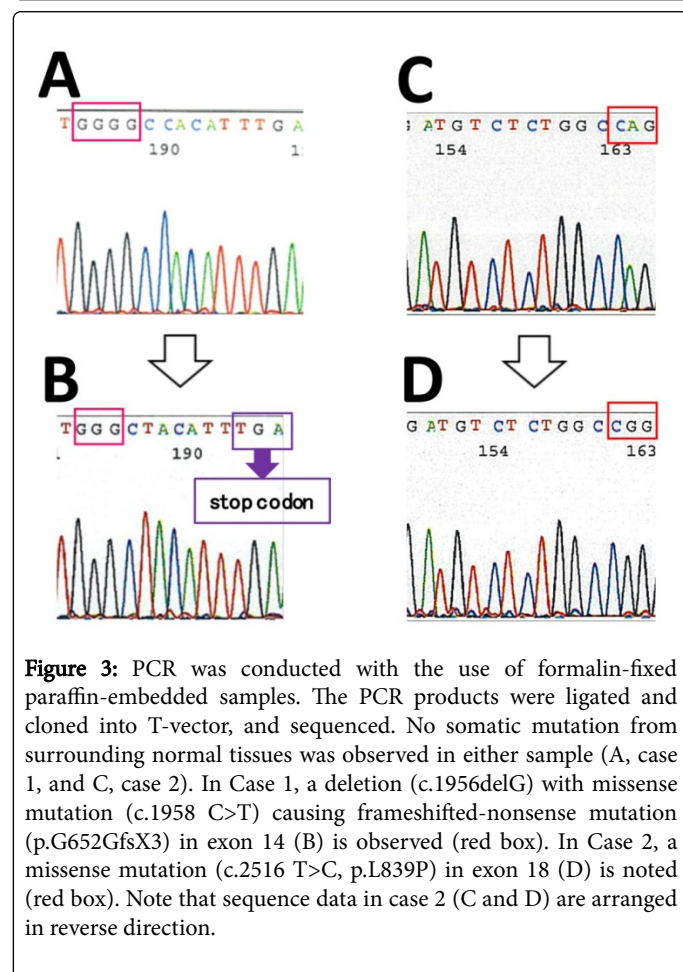
**Figure 1:** Polypectomy specimen shows an onionskin-like concentric formation of spindle cells and dense inflammatory cell infiltration, predominantly eosinophils (hematoxylin and eosin, A, x20, B, x400). On immunohistochemistry (C, x400), the spindle cells appear diffusely positive for PDGFRA.

To determine whether the two cases of colonic IFPs carried PDGFRA gene alterations, sections (5- $\mu$ m thick) from formalin-fixed paraffin-embedded specimens were cut, and DNA samples selectively prepared from microdissected samples by the agarose-bead mediated technique were subjected to PCR [5]. Since exons 12, 14 and 18 are the three hot spots of somatic PDGFRA mutations, three sets of primers were used for polymerase chain reaction (PCR) to cover the three exonic regions with specific primers as previously described [3]. PCR products were ligated and cloned into T-vector, and at least 10 independent clones were sequenced. No somatic mutation from surrounding normal tissue was observed in either sample (Figure 3A and C). Nonetheless, in Case 1, a deletion (c.1956delG) with missense

mutation (c.1958 C>T) causing frameshifted-nonsense mutation (p.G652GfsX3) in exon 14 (Figure 3B) was observed in 4 of the 10 sequenced clones. Furthermore, in Case 2, a missense mutation (c.2516 T>C, p.L839P) in exon 18 (Figure 3D) was found in 3 of the 10 sequenced clones (Figure 3).



**Figure 2:** Resected specimen shows striform- or whorl-like formation of spindle cells with abundant collagenous elements and eosinophilic cells (hematoxylin and eosin, A, x20, B, x400). On immunohistochemistry (C, x400), the spindle cells are negative for PDGFRA.



**Figure 3:** PCR was conducted with the use of formalin-fixed paraffin-embedded samples. The PCR products were ligated and cloned into T-vector, and sequenced. No somatic mutation from surrounding normal tissues was observed in either sample (A, case 1, and C, case 2). In Case 1, a deletion (c.1956delG) with missense mutation (c.1958 C>T) causing frameshifted-nonsense mutation (p.G652GfsX3) in exon 14 (B) is observed (red box). In Case 2, a missense mutation (c.2516 T>C, p.L839P) in exon 18 (D) is noted (red box). Note that sequence data in case 2 (C and D) are arranged in reverse direction.

## Discussion

IFPs, first described by Vanek as characteristic submucosal granulation tissue with eosinophilic infiltration, are rare condition of mesenchymal proliferation with an onionskin-like pattern around blood vessels and epithelial glands [6]. IFPs were regarded as a reactive condition to specific local inflammation until the high frequency of PDGFRA gene mutation was demonstrated [3,4]. The differential diagnosis of IFPs, therefore, includes wide variety of pathological condition ranging from reactive or reparative lesions (various form of granulation tissues and nodular fasciitis in reactive process) to neoplastic lesions (various spindle-shaped sarcomas, and sarcomatoid carcinoma, inflammatory myofibroblastic tumors, gastrointestinal stromal tumors and Hodgkin's lymphoma) [7-9]. Although there still are some cases free of apparent genetic alteration, IFPs are now generally regarded as benign mesenchymal tumors related to genetic alteration of the PDGFRA gene [3]. Besides characteristic histopathological features, mesenchymal cells in IFPs usually show positive immunostaining for CD34 [1]. Indeed, in our current study, both cases were positive for CD34 (data not shown); however, immunostaining of PDGFRA was not consistent in the two cases.

Accumulated molecular analyses of IFPs have shown that most mutations of the PDGFRA gene are concentrated in exons 12, 14 and 18 [3,4]. Interestingly, PDGFRA mutations in exon 12 tend to be associated with the small intestine, and those in exon 18 with the stomach [3]. Compared with other sites in the gastrointestinal tract, however, occurrence of IFPs at a colorectal location is rare, and few studies have been conducted on genetic alterations in colorectal IFPs [3]. In the current study, the presence of PDGFRA gene mutation was confirmed in two cases of IFPs in the large intestine. Interestingly, Case 1 showed frameshifted-nonsense mutation that probably produced a truncated form of the PDGFRA protein. Since this study does not cover the entire exome and does not include in vitro assays, we were not able to perceive how the truncated form of PDGFRA induces tumorigenicity in mesenchymal cells. Study of a large number of similar cases is needed to uncover the role of uncommon truncation mutation of the PDGFRA gene in the pathogenesis of IFPs.

## References

1. Liu TC, Lin MT, Montgomery EA, Singhi AD (2013) Inflammatory Fibroid Polyps of the Gastrointestinal Tract: Spectrum of Clinical, Morphologic, and Immunohistochemistry Features. *Am J Surg Pathol* 37: 586-592.
2. Carmack SW, Genta RM, Schuler CM, Saboorian MH (2009) The Current Spectrum of Gastric Polyps: A 1-Year National Study of over 120,000 Patients. *Am J Gastroenterol* 104: 1524-1532.
3. Huss S, Wardelmann E, Goltz D, Binot E, Hartmann W, et al. (2012) Activating PDGFRA Mutations in Inflammatory Fibroid Polyps Occur in Exons 12, 14 and 18 and are Associated with Tumour Localization. *Histopathology* 61: 59-68.
4. Schildhaus HU, Cavlar T, Binot E, Buttner R, Wardelmann E, et al. (2008) Inflammatory Fibroid Polyps Harbour Mutations in the Platelet-derived Growth Factor Receptor alpha (PDGFRA) Gene. *J Pathol* 216: 176-182.
5. Nakagawa M, Kitazawa R, Kuwahara N, Yoshida K, Haraguchi R, et al. (2013) Efficient Genetic Analysis of Microdissected Samples by Agarose-Bead Method: Alterations of beta-Catenin Gene in Fundic Gland Polyp and Heterotopic Gastric Mucosa of Duodenum. *Acta Histochem Cytochem* 46: 19-24.
6. Vanek J (1949) Gastric Submucosal Granuloma with Eosinophilic Infiltration. *J Pathol* 25: 397-412.

- 
7. Makhoulf HR, Sobin LH (2002) Inflammatory myofibroblastic tumors (inflammatory pseudotumors) of the gastrointestinal tract: How closely are they related to inflammatory fibroid polyps? Hum Pathol 33: 307-315.
  8. Koyuncuer A (2014) Inflammatory myofibroblastic tumor of the small-bowel mesentery: A case report of nonspecific clinical presentation and a review of the literature. Int J Surg Case Rep 5: 1214-1217.
  9. Koyuncuer A, Gönüşen L, Kutsal AV (2015) A rare case of giant gastrointestinal stromal tumor of the stomach involving the serosal surface. Int J Surg Case Rep 12: 90-94.