

Incomplete Macular Hole Closure after Human Amniotic Membrane Plug Transplantation: Is Sulfur Hexafluoride Reinjection Necessary?

Tito Fiore*, Davide Tucci, Greta Castellucci, Barbara Iaccheri, Marco Lupidi, Carlo Cagini

Department of Biomedical and Surgical Sciences, Section of Ophthalmology, University of Perugia, S. Maria Della Misericordia Hospital, Perugia, Italy

ABSTRACT

Purpose: To report a case of a patient with a Full-Thickness Macular Hole (FTMH) treated with a Pars-Plana Vitrectomy (PPV) and the positioning of a human Amniotic Membrane (hAM) plug.

Methods: Patient was surgically treated with PPV, hAM plug implantation and SF₆ (sulfur hexafluoride) as endotamponade. A complete ophthalmic examination and an Optical Coherence Tomography (OCT) were performed at every visit.

Results: After surgery, the edges of hAM were elevated, folded and not perfectly outspread under the surrounding retinal layers, which were thickened and elevated, due to the presence of a persistent intraretinal oedema. A new surgery with reinjection of 20% SF₆ was performed, but despite the closure of MH, neurosensory retina migration over the hAM plug was incomplete and macular edema persisted.

Conclusion: hAM transplant is a valuable option for MH surgery. Plug dimension should be calibrated on MH diameter, and correctly spread under the edges of the hole itself. In cases of persistent macular hole, a new surgery with reinjection of 20% SF₆ can be used to promote macular hole closure. Preoperative macular edema should be considered as a negative prognostic factor for MH closure.

Keywords: Human amniotic membrane; Macular hole; Vitreoretinal surgery

INTRODUCTION

The use of a human Amniotic Membrane (hAM) plug in the treatment of Full-Thickness Macular Holes (FTMHs) has recently been described by different vitreoretinal surgeons [1-3]. The hAM is one of the layers of the fetal membranes and it's made of a stromal matrix, a thick collagen layer, an overlying basement membrane and a single layer of epithelium. Transplantation of a hAM plug is widely used in the treatment of many different pathological conditions of ocular surface, while its use in vitreoretinal surgery has only recently been described [4,5]. Different clinical studies have been made prior to the use of the hAM plug in retinal pathology. Some authors demonstrated that, *in vitro*, hAM is a valid support matrix for Retinal Pigmented Epithelium (RPE) restoration. Other studies proved, in rabbits, the absence of inflammation after positioning the plug in the subretinal space. More recently, the transplantation of amniotic membrane to the subretinal space in pigs showed good results in treating mechanically induced damages. The first described case of hAM plug use in human eyes is a recent choroidal

hole repair in a case of globe rupture [6-10].

Here, we present a case of a 79 years old female patient with a FTMH, developed with a Rhegmatogenous Retinal Detachment (RRD) and treated with hAM positioning. After surgery, the edges of hAM were elevated, folded and not perfectly outspread under the surrounding retinal layers, which were thickened and elevated, due to the presence of a persistent intraretinal oedema. Neurosensory retina migration over the hAM plug was incomplete and macular hole never fully closed.

CASE STUDY

A 79 years old female patient referred to our clinic with a RRD involving the posterior pole and originated from a peripheral retinal break. A concomitant FTMH was diagnosed. Patient ophthalmic history included the presence of glaucoma, medically controlled with topical drops of prostaglandin analogue tafluprost and beta-blocker timolol.

Considering clinical presentation, patient was addressed to surgery.

Correspondence to: Tito Fiore, Department of Biomedical and Surgical Sciences, Section of Ophthalmology, University of Perugia, S. Maria Della Misericordia Hospital, Perugia, Italy, E-mail: titofiore@hotmail.com


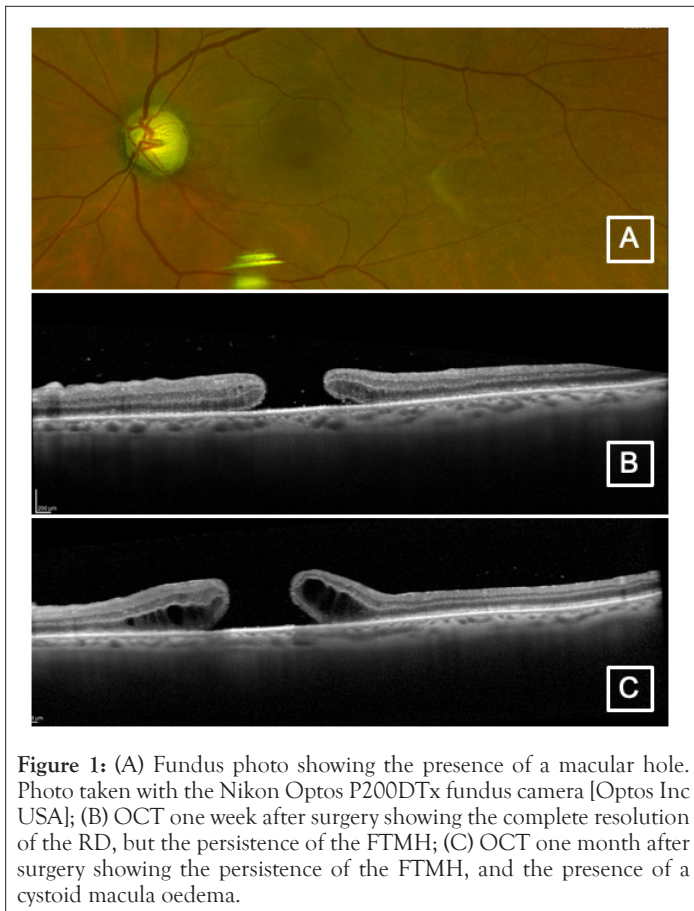
Received: May 28, 2021; Accepted: June 12, 2021; Published: June 19, 2021

Citation: Fiore T, Tucci D, Castellucci G, Iaccheri B, Lupidi M, Cagini C (2021) Incomplete Macular Hole Closure after Human Amniotic Membrane Plug Transplantation: Is Sulfur Hexafluoride Reinjection Necessary? Immunome Res. 17:8143.

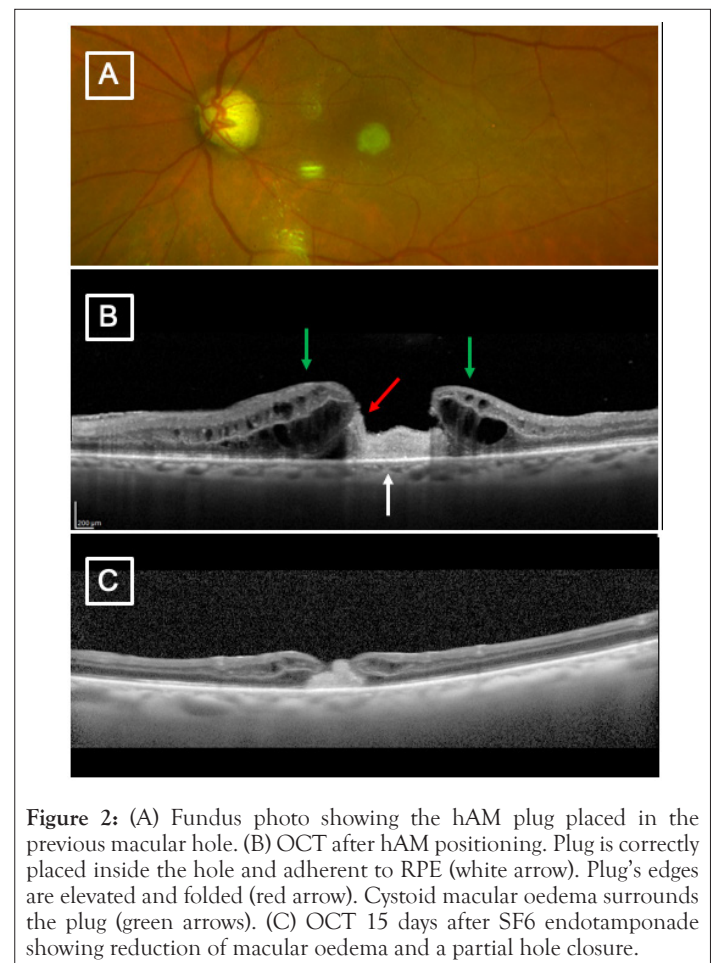
Copyright: © 2021 Fiore T, et al. This is an open-access article distributed under the terms of the Creative Commons Attribution License, which permits unrestricted use, distribution, and reproduction in any medium, provided the original author and source are credited.

Preoperatively a complete ophthalmic examination and a retinal Optical Coherence Tomography (OCT) were performed. Surgery was performed by one of the experienced vitreoretinal surgeons of the clinic (T.F.) and carried out under retrobulbar anesthesia. Patient underwent a 3-port 25-gauge transconjunctival Pars Plana Vitrectomy (PPV) performed by the means of the Constellation Vision System (Alcon Laboratories, USA), with peeling of the Internal Limiting Membrane (ILM) and the use of 20% sulfur hexafluoride (SF6) (Alcon Laboratories, Inc., Fort Worth, USA) endotamponade.

After surgery, the RD resolved, but the FTMH persisted (Figure 1). Best corrected visual acuity (BCVA) was 20/250. One-month later, patient was evaluated, and OCT showed a FTMH with an increased diameter and with raised, thickened, oedematose edges (Figure 1).



After surgery, BCVA slightly improved from baseline (20/250) to 20/200 and OCT showed the presence of the hAM plug placed inside the hole. Nevertheless, the edges of hAM were elevated, folded and not perfectly outspread under the surrounding retinal layers, which were thickened and elevated, due to the presence of a persistent intraretinal oedema (Figure 2). Considering that, after one month, OCT was substantially unchanged, possibly due the presence of oedema contrasting the adhesion between hAM and neuroretina, the patient was addressed to a further surgery to inject again 20% SF6 as endotamponade.



Considering the persistence and potentially worsening of the FTMH, patient was addressed again to surgical treatment for the positioning of a hAM plug (video 1). Surgery was again performed by the same experienced vitreoretinal surgeon (T.F.) and carried out under retrobulbar anesthesia. The hAM, stored and cryopreserved in the eye tissue bank located in Fabriano (Italy), was transported to our clinic the same day of the surgery. In the surgery room, tissue was pre-cut at the diameter of 2 mm using a full-thickness biopsy punch. A standard 3-port 23-gauge transconjunctival PPV was performed again and the hAM plug was inserted inside the vitreous cavity, where it was furthermore cut to perfectly fit the macular hole. Plug was then positioned through the macular hole into the subretinal space, with its basal membrane faced up, and the chorion layer faced towards the RPE. After plug positioning, 20% SF6 was injected inside the vitreous cavity as endotamponade.

Fifteen days after this last surgery, OCT showed that hAM plug was still perfectly placed and adherent to the overlying retina, with a significant reduction of the macular oedema (Figure 2) that persisted at 16-month follow-up (Figure 3). Despite the multiple

surgical interventions described, neurosensory retina migration over the hAM plug was incomplete and macular hole never fully closed.

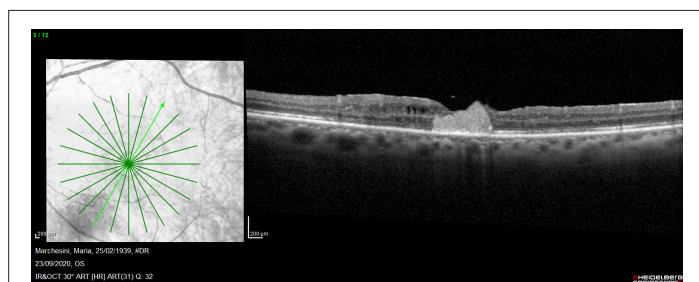


Figure 3: OCT 16-month after SF6 injection showing the incomplete MH closure and the persistence of macular oedema.

RESULTS AND DISCUSSION

FTMH is a challenging clinical condition. According to literature, PPV with ILM peeling and 20% SF6 as endotamponade was performed. Considering the persistence of the hole during the following month, we planned a new surgery to transplant a hAM plug into the subretinal space of the MH. According to Rizzo et al., we should have expected the complete MH closure with the neurosensory retina totally overfilling the hAM plug after 1 week from surgery. Nevertheless, our result was different (Figure 2), and although the hAM plug fitted in the hole and was adherent to RPE, its edges were elevated and folded with a surrounding macular oedema.

Two choices were possible: injection of an air bubble in the vitreous cavity or watch and wait. In agreement with a previous report 11, the second option was chosen, but, unlike Ventre et al., MH was unchanged on OCT during the following month and a further surgery with 20% SF6 injection was performed. After this last surgery MH again behaved unexpectedly. In fact, at 16-month follow-up, although the hAM plug was adherent to the overlying retina, MH was only partially closed, and a cuff of retinal oedema was still present (Figure 3).

Our case report suggests some observations. Firstly, the presence of the marginal folds of the plug can mechanically block the migration of the neuroretina over the hAM and this could have been related either to the different dimension between the plug and the hole or to the incorrect positioning of the edges of the plug under the edges of the macular hole. Nevertheless, unlike Ventre et al. [11], a further surgery was again needed to flatten the retina over the hAM plug, and this was probably due to the presence of the macular oedema likely contrasting the adhesion between hAM and neuroretina. Later, neuroretina progressively migrated over the plug, probably due to adhesive properties and a shrinkage of the hAM with the retina in tow over time and/or to a regenerative effect of the hAM on the neurosensory retina. Regarding the possible pathogenesis of ME, it is remarkable to underly that the patient was under both timolol and tafluprost topical therapy for glaucoma. As reported by Wendel and colleagues, the postoperative use of both prostaglandin

analogues and beta-blockers is significantly associated with the incidence of pseudophakic cystoid macular oedema [8,12,13].

CONCLUSION

In conclusion, hAM transplant is a valuable option for macular hole surgery, given the potential regenerative effect on the neurosensory retina, the absence of immunogenic activity and a possible ant inflammatory effect. Plug dimension should be calibrated on MH diameter, and correctly spread under the edges of the hole itself. In cases of persistent macular hole, a new surgery with reinjection of 20% SF6 can be used to promote macular hole closure. Preoperative macular oedema should be considered as a negative prognostic factor for MH closure.

REFERENCES

1. Caporossi T, Tartaro R, De Angelis L, Pacini B, Rizzo S. A human amniotic membrane plug to repair retinal detachment associated with large macular tear. *Acta Ophthalmol.* 2019;6.
2. Caporossi T, De Angelis L, Pacini B, Tartaro R, Finocchio L, Barca F, et al. A human amniotic membrane plug to manage high myopic macular hole associated with retinal detachment. *Acta Ophthalmol.* 2020;18.
3. Rizzo S, Caporossi T, Tartaro R, Finocchio L, Franco F, Barca F, et al. A Human amniotic membrane plug to promote retinal breaks repair and recurrent macular hole closure. *Retina.* 2019;39:95-103.
4. Sorsby A, Symons HM. Amniotic membrane grafts in caustic burns of the eye (burns of the second degree). *Br J Ophthalmol.* 1946;30:6.
5. Roth A. Plastic Repair of conjunctival defects with fetal membranes. *Arch Ophthalmol.* 1940;23:522-525.
6. Capeéans C, Piñeiro A, Pardo M, Sueiro-López C, Blanco MA, Domínguez F, et al. Amniotic membrane as support for human retinal pigment epithelium (RPE) cell growth. *Acta Ophthalmol Scand.* 2003;29.
7. Ohno-Matsui K, Ichinose S, Nakahama K, Yoshida T, Kojima A, Mochizuki M, et al. The effects of amniotic membrane on retinal pigment epithelial cell differentiation. *Mol Vis.* 2005;11:1-10.
8. Rosenfeld PJ, Merritt J, Hernandez E. Subretinal implantation of human amniotic membrane: A rabbit model for the replacement of Bruch's membrane during submacular surgery. *Investig Ophthalmol Vis Sci Ophthalmol.* 1999;40.
9. Kiilgaard JF, Scherfig E, Prause JU, La Cour M. Transplantation of amniotic membrane to the subretinal space in pigs. *Stem Cells Int.* 2012.
10. Zhu D, Jin X, Zhou J. Transplantation of amniotic membrane for choroidal hole to treat suprachoroidal silicone oil migration. *Acta Ophthalmologica.* 2017;11.
11. Ventre L, Marolo P, Reibaldi M. A Human amniotic membrane plug to treat persistent macular hole. *Case Rep Ophthalmol.* 2020;11:442-447.
12. Wendel C, Zakrzewski H, Carleton B, Etminan M, Mikelberg FS. Association of postoperative topical prostaglandin analog or beta-blocker use and incidence of pseudophakic cystoid macular edema. *J Glaucoma.* 2018;27:402-406.
13. Jirsova K, Jones GLA. Amniotic membrane in ophthalmology: Properties, preparation, storage and indications for grafting: A review. *Cell Tissue Bank.* 2017;18:193-204.