

Imperforate Anus with a Proximal Sigmoid Colovesical Fistula

Samuel M Alaish

University of Maryland School of Medicine, Baltimore, USA

*Corresponding author: Samuel M Alaish, Assistant Professor of Surgery, University of Maryland School of Medicine, Baltimore, USA, Tel: 410-328-5730; Fax: 410-328-0652; E-mail: salaish@smail.umaryland.edu

Rec date: Jun 04, 2014; Acc date: Jun 06, 2014; Pub date: Jun 12, 2014

Copyright: © 2014 Alaish SM. This is an open-access article distributed under the terms of the Creative Commons Attribution License, which permits unrestricted use, distribution, and reproduction in any medium, provided the original author and source are credited.

Introduction

Although anorectal malformations occur in 1:5000 live births worldwide [1], their cause remains elusive. Males carry a slight preponderance to the defect [2]. The defects were formerly classified as either low, implying a less severe defect with a better prognosis, versus high, implying a more severe defect with greater morbidity, including a greater incidence of stool incontinence. Current classification of anorectal malformations is according to the location of the fistula, if present. 95% of patients have either a perineal, vestibular, rectourethral or rectovesical (bladder neck) fistula; 5% have no fistula. Perineal fistulas and vestibular fistulas (in girls) can be primarily repaired with an anorectoplasty; patients with more proximal fistulae are advised to undergo a diverting proximal sigmoid or descending colostomy and mucous fistula [3]. The exact location of the fistula, if present, can then be ascertained with a distal colostogram through the mucous fistula. We present a case of an infant with a fistula between the proximal sigmoid colon and the dome of the bladder. Our review of the literature fails to find another example of this most severe anomaly.

Case Presentation

An otherwise, healthy, term 9 month-old male infant with a history of imperforate anus presented for evaluation for a posterior sagittal anorectoplasty. As a newborn, he had undergone a diverting right transverse loop colostomy by another surgeon, after no meconium appeared on the perineum following 24 hours of life. Typically, a diverting proximal sigmoid or descending colostomy and mucous fistula is created; however, after the distal colostogram, it became clear why the first surgeon chose this location. As is customary, we injected contrast through the mucous fistula which demonstrated a fistula between the proximal sigmoid colon [the rectum was not present] and the dome of the bladder [not the bladder neck] (Figure 1 Images A-D). At laparotomy, the diagnosis was confirmed. The fistula measured 3 cms in diameter. Following division of the fistula and closure of the bladder in two layers, a posterior sagittal anorectoplasty approach was performed to pull the sigmoid colon through the muscle complex and create a neanus. The child then underwent colostomy closure 1 year later, after having been briefly lost to follow-up.

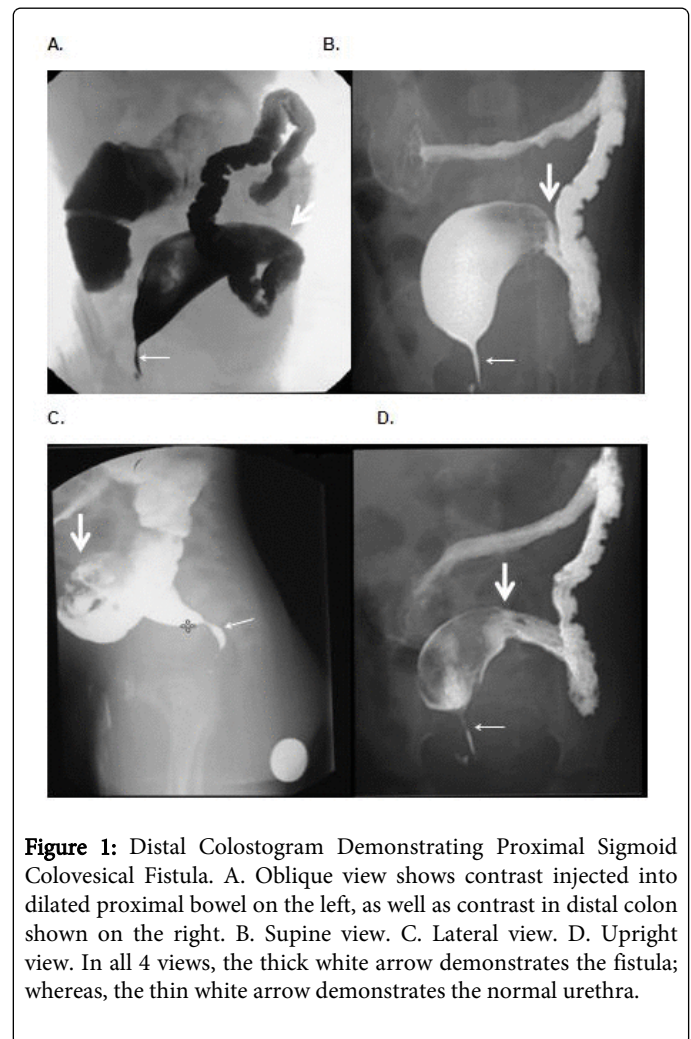


Figure 1: Distal Colostogram Demonstrating Proximal Sigmoid Colovesical Fistula. A. Oblique view shows contrast injected into dilated proximal bowel on the left, as well as contrast in distal colon shown on the right. B. Supine view. C. Lateral view. D. Upright view. In all 4 views, the thick white arrow demonstrates the fistula; whereas, the thin white arrow demonstrates the normal urethra.

References

1. Brenner EC (1975) Congenital defects of the anus and rectum. *SurgGynecolObstet* 20:579-588.
2. Stephens FD (1953) Malformations of the anus. *Aust N Z J Surg* 23: 9-24.
3. Levitt MA, Pena A (2012) *Anorectal malformations in Pediatric Surgery*. (7thedn), Saunders, Philadelphia, PA.