

Image Guided Percutaneous Facet Joint Infiltrations: Review of the Knowledge for Diagnostic and Therapeutic Approach

Filippiadis DK*, Mazioti A, Velonakis G and Kelekis A

2nd Radiology Department, University General Hospital "ATTIKON", Athens, Greece

Introduction

It is estimated that approximately 70-90% of the population will experience at least once during their lifetime an episode of back pain (neck pain, upper low back pain) with facet joints accounting as a causative agent in 25-40% of the cases [1,2]. Facet joints are frequently affected by osteoarthritis resulting in joint space narrowing, intra-articular vacuum phenomenon/fluid, osteophytes, synovial cyst formation and flaval ligaments hypertrophy [3].

Percutaneous facet joint steroid infiltrations are minimally invasive therapeutic or diagnostic procedures that involve injection of corticosteroid with or without local anesthetic inside the zygapophysal joints of the spine. The procedure is performed under minimal or no anesthesia aiming to control painful symptoms during the acute phase. In addition infiltrations provide diagnostic verification of a certain facet joint acting as pain source.

The use of steroids for infiltrations goes back to 1950s [4]. Steroids decrease neutrophils aggregation and suppress inflammatory proteins release by mast cells and macrophages, thereby, decreasing inflammatory cells activity [5]. Nowadays, facet joint steroid infiltrations are used throughout the globe for low back pain treatment. They constitute a symptomatic treatment for low back pain and facet syndrome refractory to appropriate conservative medical therapy.

Facet Joint Syndrome

Facet joint syndrome is diagnosed in patients with local paralumbar tenderness occasionally radiating to thigh, iliac crest and rarely to the groin. Pain is usually worse when waking up from bed or trying to stand after prolonged sitting and could be exacerbated upon pressure, hyperextension, torsion and lateral bending. The correlation of physical examination findings to those of imaging and neurophysiologic studies will play a decisive role to proper patient selection. Emphasis must be given to the fact that apart from their therapeutic role, percutaneous corticosteroid infiltrations might as well provide diagnostic information concerning the origin of the pain.

Conservative therapy is initially proposed. Image guided infiltrations can either be combined to this course or solely performed as an intermediate step between any of the rest therapeutic options which are either percutaneous (ablation) or surgical [6]. The injectate in the vast majority of cases contains a long acting corticosteroid mixed to local anesthetic. Alternatively, sodium hyaluronate solutions or ozone were tested, however more and extensive studies are necessary [7,8].

Ideal candidate for percutaneous facet joint infiltration is any patient with low back or radicular pain refractory to a 2-3 weeks course of conservative medical therapy. The facet joint selection is usually made by identifying the point of maximal local tenderness to palpation over the joint of interest and considering the cutaneous distribution of the pain. There is no clear relation between the dose and the effect. In most cases, if pain reduction is more significant than 50%, a second injection is performed 1 week later, and a third injection at one month with a maximum of five injections per years [9].

Alternative minimally invasive therapies include median nerve block, radiofrequency ablation of the medial branch nerves of the dorsal rami innervating each facet and MR-guided HIFU [6,10,11].

Indications

Cervical spine

- Unilateral or bilateral paravertebral neck pain with or without headaches and cutaneous pain
- Decreased range of neck motion
- Local tenderness over the facet joint(s) of interest
- Pain referral in a nonradicular pattern into shoulder girdle or elbow but never more distally [3,6,12,13].

Lumbar spine

- Degenerative facet joint arthritis, inflammatory facet joint arthropathy (spondyloarthropathy, rheumatoid polyarthritis)
- Unilateral or bilateral paravertebral low back pain which may be aggravated on extension or rotation, during rest in any posture, upon changing positions from sitting to standing
- Deep, dull pain limited to low back, buttock and hip – pain referral in a nonradicular pattern into knee joint but never more distally
- Pain relieved by flexion, standing or walking, rest or repeated activity
- Local tenderness to palpation over the facet joint(s) of interest
- Absence of radicular pain upon straight-leg raising
- Morning local paraspinal stiffness
- Normal neurologic examination

Contraindications

- Patient unwilling to consent to the procedure
- Pregnancy (due to teratogenic effects of ionizing radiation)
- Coagulopathy [Platelets count <50.000/mm³ - International Normalized Ratio (INR)>1.4]

*Corresponding author: Filippiadis DK, 2nd Radiology Department, University General Hospital "ATTIKON", Athens, Greece, E-mail: dfilippiadis@yahoo.gr

Received June 10, 2013; Accepted September 30, 2013; Published October 04, 2013

Citation: Filippiadis DK, Mazioti A, Velonakis G, Kelekis A (2013) Image Guided Percutaneous Facet Joint Infiltrations: Review of the Knowledge for Diagnostic and Therapeutic Approach. J Med Diagn Meth 2: 137. doi:10.4172/2168-9784.1000137

Copyright: © 2013 Filippiadis DK, et al. This is an open-access article distributed under the terms of the Creative Commons Attribution License, which permits unrestricted use, distribution, and reproduction in any medium, provided the original author and source are credited.

- Systemic infection
- Local skin infection at the puncture site
- Allergy to contrast medium (in such case air bubbles can be used)
- Allergy to any component of the injected mixture (local anesthetic, corticosteroid)
- Patient has already received maximum allowed for a given period dose of steroids [6,12].

Pre-procedure set-up

At least 24 hours prior to the procedure, patient's physical examination and coagulation laboratory tests are performed and clinical symptoms are recorded on a visual-analogue scale (VAS) with the corresponding VAS score. Painful areas and other possible neurological defects (e.g. hypoesthesia) are drawn on a specific chart before and during the procedure [14].

Strict sterility measures are necessary. Sterile bags are used to cover image intensifiers and X ray tubes, whilst, the skin is cleaned with alcohol solution and iodide povidone and a full surgical drape is placed over the patient [6].

Technique

Corticosteroid selection

The most commonly injected corticosteroids are derivatives of a cortisol analogue called prednisolone that can be either soluble (particulate preparation) or non-soluble (non-particulate preparation which contains highly insoluble in water corticosteroid esters that form microcrystalline suspensions) [15]. Non-soluble corticosteroids have a longer lasting effect than soluble ones due to the esters which require hydrolysis in order to release the active moiety [15,16]. On the other hand, controversy is raised on whether soluble corticosteroids have a quicker initiation of their effect due to the rapid cellular uptake [17].

Imaging guidance

Fluoroscopy, Computed Tomography or Magnetic Resonance can be used as guidance imaging methods for percutaneous spinal infiltrations. Fluoroscopy is governed by the advantage of real time imaging during needle progression and especially during contrast medium injection which will verify the extravascular and intrarticular needle positioning. Computed Tomography provides more detailed anatomy of the region of interest. Magnetic Resonance although lacking

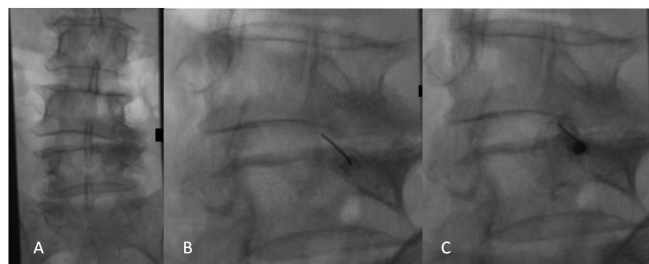

Figure 1: A: P-A fluoroscopy projection illustrating a degenerated L4-L5 right facet joint (patient is in prone position). B: Oblique ("Scottie Dog" projection) fluoroscopy view with the needle inside the L4-L5 right facet joint (posterolateral approach) C: Oblique ("Scottie Dog" projection) fluoroscopy view post contrast medium injection verifying the proper needle position (dispersion of the medium inside the articular space with no evidence of intravascular access).

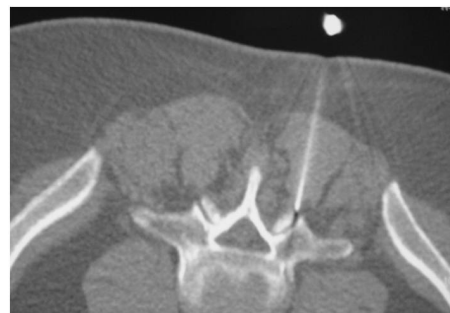


Figure 2: Axial CT scan with the needle inside the facet joint (patient in prone position, posterior access).

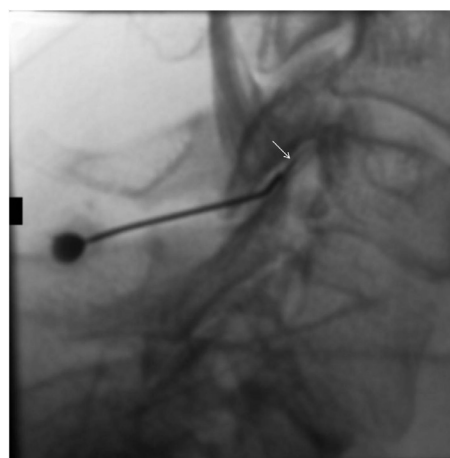


Figure 3: Lateral fluoroscopy view with the needle inside the C5-C6 right facet joint post contrast medium injection. Notice the dispersion of the contrast medium within the articular space (arrow).

ionizing radiation is of higher cost and of longer duration. Recent study upon the cost of MR-guided infiltrations concluded that it is twice the cost of CT-guided ones [18] (Figures 1-3).

Cervical Spine

Concerning C1-C2 infiltration

With the patient in prone position with neck extension, a strict posterior access aiming in the inferior external articulation of C1-C2 is the approach of choice.

For the rest cervical levels, a posterolateral access is used. In our department we perform facet joint infiltration in the cervical spine with the patient seated in the fluoroscopy unit and the contralateral shoulder against the X-ray table. A direct posterolateral access is performed under strict sterility measures. In most centres worldwide the injectate mixture for cervical spine includes corticosteroid mixed to normal saline instead of local anaesthetic in order to avoid inadvertent anesthetization of C4, C5 and C6 nerve roots.

Lumbar spine

Two approaches can be used:

- The posterior access (patient is in strict prone position and needle tip is advanced at the inferior part of the articular recess).
- The oblique direct access: at 45° rotation, the facet joint is

visualized in the “Scotty dog” projection. The 22-gauge needle is advanced into the facet joint and its final position inside the articulation is confirmed with injection of non-ionic contrast medium. The mixture of glucocorticosteroid and local anaesthetic is then injected.

Post- Procedure Care

Post-discharge instructions vary and depend upon the practitioner. In general, patient is usually allowed to return to his/her normal activities after the first 24 hours. Precaution of a diet without salt and sugar for 24-48 hours must be taken for diabetics or patients with arterial hypertension. The injected corticosteroid may take 3-5 days to reach its anti-inflammatory effect thereby the initial pain relief (which is the local anesthetic) is followed by a baseline pain return and a secondary pain relief at 3-5 days [19]. Clinical evaluation is performed after 7-10 days.

Potential Complications

- Immediate and generally transient painful reaction with a latter acute stage of arthritis which regresses in 24-48 hours
- Bleeding (under normal coagulation values, epidural hematoma is a very rare complication, almost exceptional)
- Infection (septic arthritis has a 24-72 hours latency period)
- Misplacement of the needle in the sub-arachnoid space
- Contrast medium reaction
- Cord injury, vasovagal reactions, ataxia (for cervical level)
- Thecal sac puncture with subsequent headache
- Allergic reactions to the medications given
- Arterial puncture with subsequent dissection, thrombus, false aneurysm, perivascular hematoma, air or crystals embolisation [6,7,20,21].

Outcome Measures

Outcome of facet joint infiltration greatly depends upon proper patient selection (59-94% immediate and 27-54% long term relief) [6]. Level of evidence for therapeutic facet joint infiltrations is limited for cervical spine and limited to moderate for lumbar spine concerning short- and long-term improvement [22,23]. However, even in the most recent guidelines released from the American Society of Pain Physicians it is stated that the technique is the oldest and most commonly used one [23].

The moderate to high success rates of the technique, its safety profile and least invasiveness seem to constitute intra-articular facet joint infiltrations as an attractive therapy for facet joint syndrome. In addition, intra-articular facet joint infiltrations can be used to differentiate symptomatic from asymptomatic facet joint alterations in cases where diagnosis is controversial.

References

1. Andersson GB (1999) Epidemiological features of chronic low-back pain. *Lancet* 354: 581-585.
2. Manchikanti L, Boswell MV, Singh V, Pampati V, Damron KS, et al. (2004) Prevalence of facet joint pain in chronic spinal pain of cervical, thoracic, and lumbar regions. *BMC Musculoskelet Disord* 5: 15.
3. Gallucci M, Limbucci N, Paonessa A, Splendiani A (2007) Degenerative disease of the spine. *Neuroimaging Clin N Am* 17: 87-103.

4. Robecchi A, Cash KA (1952) L' idrokortisone, prime esperienze cliniche in campo reumatologico. *Minerva Med* 2: 1259-63.
5. Young IA, Hyman GS, Packia-Raj LN, Cole AJ (2007) The use of lumbar epidural/transforaminal steroids for managing spinal disease. *J Am Acad Orthop Surg* 15: 228-238.
6. Kelekis AD, Somon T, Yilmaz H, Bize P, Broutzos EN, et al. (2005) Interventional spine procedures. *Eur J Radiol* 55: 362-383.
7. Colen S, Haverkamp D, Mulier M, van den Bekerom MP (2012) Hyaluronic acid for the treatment of osteoarthritis in all joints except the knee: what is the current evidence? *BioDrugs* 26: 101-112.
8. Staal JB, de Bie RA, de Vet HC, Hildebrandt J, Nelemans P (2009) Injection therapy for subacute and chronic low back pain: an updated Cochrane review. *Spine (Phila Pa 1976)* 34: 49-59.
9. Martin JB Minimal invasive lumbar back pain therapy. In: HUG, editor. November 4-6, 2004. Geneva: Switzerland 2004.
10. Weeks EM, Platt MW, Gedroyc W (2012) MRI-guided focused ultrasound (MRgFUS) to treat facet joint osteoarthritis low back pain--case series of an innovative new technique. *Eur Radiol* 22: 2822-2835.
11. Varlotta GP, Lefkowitz TR, Schweitzer M, Errico TJ, Spivak J, et al. (2011) The lumbar facet joint: a review of current knowledge: Part II: diagnosis and management. *Skeletal Radiol* 40: 149-57.
12. Czervionke LF, Fenton DS. Facet joint injection and medial branch block. In: *Image-guided spine intervention*. Editors Saunders 2003;9-50.
13. Fenton DS, Czervionke LF. Selective nerve root block. In: *Image-guided spine intervention*. Editors Saunders 2003; 73-98.
14. Mystakidou K, Mendoza T, Tsilika E, Befon S, Parpa E, et al. (2001) Greek brief pain inventory: validation and utility in cancer pain. *Oncology* 60: 35-42.
15. MacMahon PJ, Eustace SJ, Kavanagh EC (2009) Injectable corticosteroid and local anesthetic preparations: a review for radiologists. *Radiology* 252: 647-661.
16. Wright JM, Cowper JJ, Page Thomas DP, Knight CG (1983) The hydrolysis of cortisol 21-esters by a homogenate of inflamed rabbit synovium and by rheumatoid synovial fluid. *Clin Exp Rheumatol* 1: 137-141.
17. Blankenbaker DG, De Smet AA, Stanczak JD, Fine JP (2005) Lumbar radiculopathy: treatment with selective lumbar nerve blocks--comparison of effectiveness of triamcinolone and betamethasone injectable suspensions. *Radiology* 237: 738-741.
18. Maurer MH, Schreiter N, de Bucourt M, Grieser C, Renz DM, et al. (2013) Cost comparison of nerve root infiltration of the lumbar spine under MRI and CT guidance. *Eur Radiol* 23: 1487-1494.
19. Sitzman BT. Epidural injections. In: *Image-guided spine intervention*. Editors Saunders 2003; 99-126.
20. Delassus P, Hadjidekov G, Kastler B Complications and patient management. Types of agents infiltrated. In: *Interventional radiology in pain treatment*. Editor Kastler B 2003;43-47.
21. Wybier M, Gaudart S, Petrover D, Houdart E, Laredo JD (2010) Paraplegia complicating selective steroid injections of the lumbar spine. Report of five cases and review of the literature. *Eur Radiol* 20: 181-189.
22. Boswell MV, Trescot AM, Datta S, Schultz DM, American Society of Interventional Pain Physicians, et al. (2007) Interventional techniques: evidence-based practice guidelines in the management of chronic spinal pain. *Pain Physician* 10: 7-111.
23. Manchikanti L, Abdi S, Atluri S, Benyamin RM, Boswell MV, et al. (2013). An update of comprehensive evidence-based guidelines for interventional techniques in chronic spinal pain. Part II: guidance and recommendations. *Pain Physician* 16: S49-S283.