

Ilizarov Technique in Acute Ankle Trauma: A Report of Fourth Cases

Vyacheslav T Tarchokov and Sergey S Leonchuk*

Scientific Center for Restorative Traumatology and Orthopedics, Kurgan, Russia

*Corresponding author: Sergey S Leonchuk, Scientific Center for Restorative Traumatology and Orthopedics, Head of the 6th orthopaedic department, M. Ulianov street, 640014, Kurgan, Russia, Tel: +7 905 8516338; E-mail: leon4yk@mail.ru

Received date: April 18, 2017; Accepted date: April 28, 2017; Published date: April 30, 2017

Copyright: © 2017 Tarchokov VT, et al. This is an open-access article distributed under the terms of the Creative Commons Attribution License; which permits unrestricted use; distribution; and reproduction in any medium; provided the original author and source are credited.

Abstract

Surgical treatment of patients with acute ankle trauma by transosseous osteosynthesis method was presented in the article. Malleolar fracture, injury of tibiofibular syndesmosis, subluxation in ankle joint and dislocation of foot were observed in our cases. Fracture of malleolus was described according to AO/OTA fracture classification in each case. In these patients we used osteosynthesis method by Ilizarov (original frame). Patients could load and use the operated limb in the Ilizarov fixator from the first days after the injury. The length of fixation of the limb by the Ilizarov fixator in the described cases was 45-58 days. In the presented clinical cases our approach in the treatment of this pathology is shown namely preference is given to closed fracture repositioning and elimination of subluxation/dislocation without open access to bones and joints. Open access is possible with repeated attempts of closed reposition in the fixator or splintered fractures of the bones of the ankle joint. Initial range of motions in ankle joint in the described patients recovered in 4 weeks after removal of the Ilizarov fixator and training with a physiotherapist and massage therapist. Functional outcome was assessed using the American Orthopaedic Foot and Ankle Society (AOFAS), the American Academy of Orthopaedic Surgeons (AAOS) and VAS-pain scales. The goal of this paper is to show capabilities and our approach in closed reduction of malleolar fractures with injury of tibiofibular syndesmosis by Ilizarov technique.

Keywords: Ankle joint; Ilizarov; External fixator; Trauma; Fracture; Subluxation; Malleolus; Syndesmosis

Introduction

Ankle injury is very common among athletes and military and among ordinary citizens. Ankle fractures are seen at emergency departments, accounting for approximately 10% of all fractures [1]. In the UK ankle injury occurs in 90,000 people per year [2], in France fractures of this zone were observed in 125 cases per 100,000 people per year [3]. Among the surgical methods of fixing fractures of the ankle joint area and damaging of tibiofibular syndesmosis, there are a number of ways: by internal fixation (wires, plates, screws, intramedullary nailing) [4-7] and by different external fixators [8]. Unfortunately, complications can often be encountered, such as non-union or mal-union of the bones [9-12], pseudoarthrosis, subluxations in the ankle [5], pain syndrome [12,13]. Cases of inflammation in the zone of intervention are common. [14,15]. For example, according to Höiness P [14] soft tissue infections after surgery in ankle fractures treated by open reduction and internal fixation (ORIF) were observed in 40% of all cases. In any colleagues paper rate of complications after intramedullary nailing of distal tibial fractures was 42.8% [12]. It is generally known that Ilizarov's fixator allows for gradual correction and lengthening of the bone [16,17], and it is also effectively used for open bone injuries [8] and infections [18]. However, this device is also successfully used for closed fixation of the fracture zone and allows the necessary reposition of bone fragments if necessary both initially and after a possible secondary displacement of bone fragments. It is important to note that the patient begins to load the injured limb in the Ilizarov fixator from the first days after the injury.

Case Presentation

After the injury, patients with temporary immobilization of the limb were delivered by an ambulance to our clinic. Patients were examined clinically and by X-ray. Functional outcome was assessed using the American Orthopaedic Foot and Ankle Society (AOFAS) [19], the American Academy of Orthopaedic Surgeons (AAOS) [20] and VAS-pain scales [21]. Pain in the ankle joint and foot, edema of soft tissues, violation of the support ability of the lower limb with limitation range of motions (ROM) in the ankle joint were typical complaints.

Operative orthopaedic intervention started in manual repositioning of fracture and dislocation or subluxation in ankle joint. After that we produced a placement of Ilizarov original frame on the leg and residual displacement of fragments of bone were occurred corrected by external fixator with fixation of ankle joint and X-ray control. This is achieved by carrying olivial wires through the fragments and fixing of the wires in the rings, further correction is also possible in the fixator due to the tightening of the olivial wires and the controlled movement of the supports. In all cases the ankle joint was fixed. Support from the foot was removed after 4-5 weeks after the operation and activities were carried out with a physiotherapist. With splintered fractures and an overweight of the patient the fixation of the ankle joint continued throughout the treatment period.

X-ray control of ankle joint (AP and ML view) was made next day after operation. Patient was allowed to walk with gradually increasing weight-bearing on operated extremity with crutches. During the hospital period patient was observed each day in our department by physiotherapist. For the period of fixation the patient was on an ambulatory supervision with dynamic control in our clinic each 2 weeks. Ilizarov frame was removed after consolidation of bone fragments.

After removal of the Ilizarov frame patient was allowed to walk with gradually increasing weight-bearing on this extremity with or without crutches. Patient was getting restorative treatment in the domiciliary clinic including physiotherapy and restoration of ROM of ankle joint. Amplitude of motions of ankle joint was restored up to initial one in 4 weeks after the beginning of the active exercises.

We present several clinical cases. Patient M, 38 y.o., male, entered in department after domestic trauma. Closed fracture of fibula and dislocation of foot (44-C1 by AO) were closed corrected by Ilizarov frame in operation (Figure 1). Period of fixation by the Ilizarov frame was 58 days.

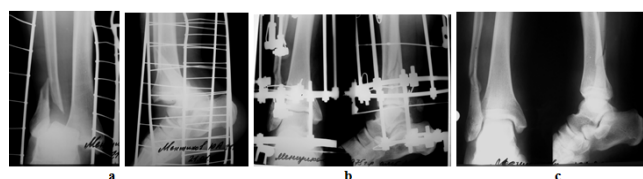


Figure 1: X-ray pictures of ankle joint (AP and ML view) of 1st patient (M), 38 y.o.: (a) after trauma (b) during the treatment by Ilizarov device (c) after our treatment.

Patient C, 35 y.o., female, got into a car crash. She was operated in our clinic for treatment of trimalleolar fracture and subluxation in ankle joint with injury of tibiofibular syndesmosis (44-B3 by AO). There was closed correction by Ilizarov device without open intervention (Figure 2). Fixation period was 48 days.




Figure 2: X-ray pictures of ankle joint (AP and ML view) of 2nd patient, 35 y.o.: a) after trauma (b) during the treatment by Ilizarov (c) after removing the frame.

Patient K, 25 y.o., male, got a sports injury of right low extremity (44-C1 by AO): fracture of fibula, injury of tibiobular syndesmosis and subluxation in ankle joint to outside (Figure 3). Occurred correction of these violations was done in operation room by Ilizarov technique with compression in zone of syndesmosis. Period of fixation was 45 days. In 4 month after frame removal patient started training.




Figure 3: X-ray pictures of ankle joint (AP and ML view) of 3rd patient, 25 y.o.: (a) after trauma (b) during the treatment by Ilizarov frame (c) after frame removal.

Patient Z, 40 y.o., female, got a high-energy injury of right low extremity (44-A2 by AO): trimalleolar fracture, injury of tibiofibular syndesmosis and subluxation in ankle joint to outside (Figure 4). Correction of these violations was produced in operation room by Ilizarov technique with compression in zone of syndesmosis. Period of fixation was 55 days.

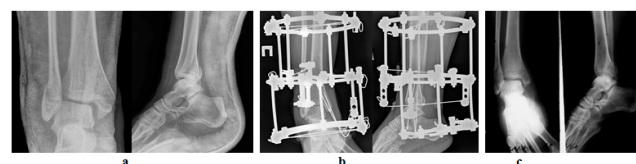


Figure 4: X-ray pictures of ankle joint (AP and ML view) of 4th patient, 40 y.o.: (a) after trauma (b) during the treatment by Ilizarov external fixator (c) after treatment.

There were no complications during our treatment in presented cases. In 6 month follow-up patients were satisfied for result and had initial ROM of ankle joint without pain. The data received from AOFAS, AAOS, VAS-pain scales are presented in the Table 1.

AO class	AOFAS	AAOS	VAS
1st case (44-C1)	94	94	1,5
2nd case (44-B3)	88	90	2,5
3rd case (44-C1)	94	94	1,1
4th case (44-A2)	91	90	1,8

Table 1: Clinical results (6 month follow-up).

Discussion

Applying the Ilizarov osteosynthesis method demonstrated a lower risk of complications than the results of our colleague's papers [22,23]. Soft tissue infections after internal fixation were observed in 56% of presented cases by Asloum Y study [15], according to Jain S [11] the rate of non-unions after intramedullary fixation of fibula fractures was presented in 20% of examined patients and by Kruppa CG [12] the number of non-unions was 19%, malunions – 23.8%. According to Lays M [24] complications after ORIF treatment were noted in 30% of patients. According to Viberg B [24] paper after locking plate treatment a rate of complications was observed in 69% cases. We

believe that absence of a foreign body in the proximity of the joint contributes to the absence of pain syndrome, which is proved by studies of some surgeons: Kruppa CG [12] – in 47.6% of all cases, according to Verhage SM [13] due to pain or discomfort removal of the implants took place in 29% participants after 13 months in average.

Absence of infection complications, secondary fragment displacement during fixation period and weight-bearing on operated extremity showed advantages of transosseous osteosynthesis according to Ilizarov technique.

In our opinion, every effort should be made to operate on closed ankle fractures as soon as possible. A delay in surgery is associated with a significant rise in infectious wound complications, which significantly lowers outcome and patient satisfaction [25,26]. Thus, according to Carragee EJ [27], 44% of the complications were noted in patients who got fixation of the segment after 24 hours after trauma.

Conclusion

Therefore, the correction of the ankle joint fracture with Ilizarov's technique allows achieving the desired adaptation of bone fragments, getting the patient an early loading on the operated limb, preserving his capacity, and adherence to the methodical principles of this method allow to prevent a possible complication and achieve to the desired result of treatment.

Conflict of Interest

There are no conflicts of interest.

Consent

The patients have provided informed consent for the case report to be published.

Authors' Contributions

V Tarchokov and S Leonchuk are the contributors of the submission and have approved the final manuscript.

References

1. Court-Brown CM, McBurnie J, Wilson G (1998) Adult ankle fractures--an increasing problem? *Acta Orthop Scand* 69: 43-47.
2. van Staa TP, Dennison EM, Leufkens HG, Cooper C (2001) Epidemiology of fractures in England and Wales. *Bone* 29: 517-522.
3. Biga N (1993) Malleolar fractures of the adult. In: *Sofcot Readings*. Expansion Scientifique Franc, Paris.
4. Tsukada S, Otsuji M, Shiozaki A, Yamamoto A, Komatsu S, et al. (2013) Locking versus non locking neutralization plates for treatment of lateral malleolar fractures: a randomized controlled trial. *Int Orthop* 37: 2451-2456
5. van den Bekerom MP, Haverkamp D, Kerkhoffs GM, van Dijk CN (2010) Syndesmotic stabilization in pronation external rotation ankle fractures. *Clin Orthop Relat Res* 468: 991-995.
6. Ilizarov GA (1989) The tension-stress effect on the genesis and growth of tissues: Part II. The influence of the rate and frequency of distraction. *Clin Orthop Relat Res*, pp: 263-285.
7. Leonchuk SS, Neretin AS, Ivanov GP (2017) Surgical treatment of the older age children with congenital recurrent clubfoot using method of transosseous osteosynthesis by ilizarov. *J Bone Rep Recomm* 3: 1.
8. Górski R, Zarek S, Modzelewski P, Malydk P, Wisniewski R, et al. (2015) Open trimalleolar fractures treated with Ilizarov external fixator. *Ortop Traumatol Rehabil* 17: 381-391.
9. Jonard B, Dean E (2017) Posttraumatic reconstruction of the foot and ankle in the face of active infection. *Orthop Clin North Am* 48: 249-258.
10. Tong D, Ji F, Zhang H, Ding W, Wang Y, et al. (2012) Two-stage procedure protocol for minimally invasive plate osteosynthesis technique in the treatment of the complex pylon fracture. *Int Orthop* 36: 833-837.
11. Khurana S, Karia R, Egol KA (2013) Operative treatment of nonunion following distal fibula and medial malleolar ankle fractures. *Foot Ankle Int* 34: 365-371.
12. Capogna BM, Egol KA (2016) Treatment of nonunions after malleolar fractures. *Foot Ankle Clin* 21: 49-62.
13. Verhage SM, Schipper IB, Hoogendoorn JM1 (2015) Long-term functional and radiographic outcomes in 243 operated ankle fractures. *J Foot Ankle Res* 8: 45.
14. Kitaoka HB, Alexander IJ, Adelaar RS, Nunley JA, Myerson MS, et al. (1994) Clinical rating systems for the ankle-hindfoot, midfoot, hallux and lesser toes. *Foot Ankle Int* 15: 87-101.
15. Johanson NA, Liang MH, Daltroy L, Rudicel S, Richmond J (2004) American Academy of Orthopaedic Surgeons lower limb outcomes assessment instruments. Reliability, validity, and sensitivity to change. *J Bone Joint Surg Am* 86: 902-909.
16. McCormack HM, Horne DJ, Sheather S (1988) Clinical applications of visual analogue scales: a critical review. *Psychol Med* 18: 1007-1019.
17. Höiness P, Engebretsen L, Stromsoe K (2001) The influence of perioperative soft tissue complications on the clinical outcome in surgically treated ankle fractures. *Foot Ankle Int* 22: 642-648.
18. Lamontagne J, Blachut PA, Broekhuysen HM, O'Brien PJ, Meek RN (2002) Surgical treatment of a displaced lateral malleolus fracture: The antiglide technique versus lateral plate fixation. *J Orthop Trauma* 16: 498-502.
19. Stewart CM, Kiner D, Nowotarski P (2013) Intramedullary nail fixation of fibular fractures associated with tibial shaft and pilon fractures. *J Orthop Trauma* 27: e114-117.
20. Jain S, Houghton BA, Brew C (2014) Intramedullary fixation of distal fibular fractures: a systematic review of clinical and functional outcomes. *J Orthop Traumatol* 15: 245-254.
21. Asloun Y, Bedin B, Roger T, Charissoux JL, Arnaud JB, et al. (2014) Internal fixation of the fibula in ankle fractures. A prospective, randomized and comparative study: Plating versus nailing. *Orthop Traumatol Surg Res* 100: 255-259.
22. Kruppa CG, Hoffmann MF, Sietsema DL, Mulder MB, Jones CB (2015) Outcomes after intramedullary nailing of distal tibial fractures. *J Orthop Trauma* 29: 309-315.
23. Viberg B, Kleven S, Hamborg-Petersen E, Skov O (2016) Complications and functional outcome after fixation of distal tibia fractures with locking plate- A multicentre study. *Injury* 47: 1514-1518.
24. Zaghoul A, Haddad B, Barksfield R, Davis B (2014) Early complications of surgery in operative treatment of ankle fractures in those over 60: a review of 186 cases. *Injury* 45: 780-783.
25. Leyes M, Torres R, Guillén P (2003) Complications of open reduction and internal fixation of ankle fractures. *Foot Ankle Clin* 8: 131-147.
26. Schepers T, De Vries MR, Van Lieshout EM, Van der Elst M (2013) The timing of ankle fracture surgery and the effect on infectious complications: A case series and systematic review of the literature. *Int Orthop* 37: 489-494.
27. Carragee EJ, Csongradi JJ, Bleck EE (1991) Early complications in the operative treatment of ankle fractures: influence of delay before operation. *J Bone Joint Surg Br* 73: 79-82.