

A Case of Vortex Vein Aplasia and Recurrent Idiopathic Uveal Effusion Syndrome

Neelakshi Bhagat*, Yufei Tu and Marco A Zarbin

The Institute of Ophthalmology and Visual Science, New Jersey Medical School, Newark, NJ

Abstract

A 46-year-old Hispanic man with a history of retinal detachment (RD) in the left eye presented ten years later with worsening superior field visual defect due to inferior serous RD in the right eye. Choroidal and ciliary body detachments were present. A diagnosis of idiopathic uveal effusion syndrome (IUES) was made after exclusion of other etiologies, and he underwent placement of sclera windows. Absence of vortex veins was noted intra-operatively. Histological analysis of the sclera specimen showed abnormal arrangement of collagen fibrils with the deposition of glycosaminoglycan (GAG). His vision gradually improved postoperatively, and the retina completely attached within four months. Four years later, however, patient developed recurrence of IUES and subsequently underwent debridement of previously-constructed scleral windows that were noted to be covered with ingrowth of fibrous tissue. Resolution of subretinal fluid and recovery of baseline vision were achieved postoperatively within 4 months, and no relapse has occurred during 27-month follow-up.

Keywords: Serous Retinal Detachment; Idiopathic Uveal Effusion Syndrome; Scleral Window; Harada's Disease; Central Serous Chorioretinopathy; Vortex Vein

Introduction

"Uveal effusion" was first described in a nanophthalmic patient by Schepens and Brockhurst in 1963 [1]. Gass and Jallow [2] described a similar syndrome in 1982, idiopathic uveal effusion syndrome, in healthy middle-aged men with normal eyes [2]. These patients usually present with visual loss in either one or both eyes with a superior visual field defect derived from an inferior RD [3]. It is widely accepted that scleral abnormality with thickened sclera, disorganized collagen fibers and deposition of GAG and compression of vortex veins by the thickened sclera are the primary causes [4]. We report a case of recurrent IUES. Absence of vortex veins was noted intra-operatively. Histologically, the sclera was of normal thickness, but areas of randomly arranged collagen fibers with fraying of collagen fibrils into 50 nm filaments were present. Granular deposits of GAG were noted in the inter fibrillar space.

Case Report

A 46-year-old Hispanic man was referred for an inferior serous RD OD of one month duration refractory to oral steroids. Serous RD was reported in OS 10 years earlier; he had undergone two RD repair attempts for a suspected rhegmatogenous component. Cataract extractions with lens implants were performed OU in the preceding 4 years.

The best-corrected visual acuity (BCVA) was 20/40 OD and hand motions OS. Intraocular pressure (IOP) measured 22 mmHg OD and 18 mmHg OS. No increased pulse pressure was noted. Slit lamp examination revealed dilated episcleral vessels OU (Figure 1). The anterior chambers OU were deep and quiet. There were trace cells in the anterior vitreous OD.

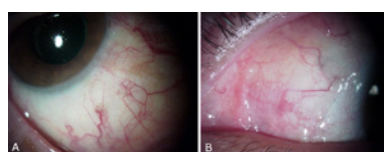


Figure 1: External photograph of OD (A) and OS (B) shows episcleral injection.

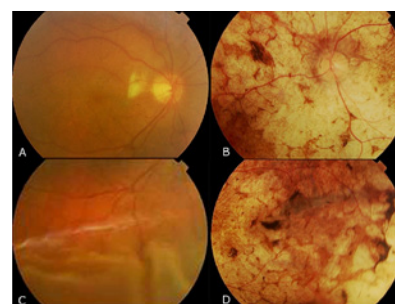


Figure 2: Fundus photographs of OD (A,C) show serous retinal detachment and of OS (B,D) show "leopard spot-type" diffuse pigmentation.

Retinal examination of OD showed a healthy, pink optic nerve with a cup/disc ratio of 0.3. Yellow-white subretinal deposits measuring 100-300 microns in diameter were noted in the macula and peri papillary area. The vessels appeared normal. Serous RD was noted from three o'clock clockwise to ten o'clock with undulating smooth retinal folds inferiorly as well as evidence of shifting fluid. The macula looked boggy (Figure 2A,C). Optical Coherence Tomography (OCT) exhibited a small amount of sub retinal fluid in the macula. OS exhibited a pale optic nerve with severe diffuse retinal pigment epithelial (RPE) atrophy with hyper plastic changes (Figure 2B,D). Gonioscopic examination using Schaffer classification revealed grade IV angles in all quadrants with blood in the Schlemm's canal at 5 o'clock OD. Examination of OS revealed a grade IV angle with no blood in the Schlemm's canal.

***Corresponding author:** Neelakshi Bhagat, The Institute of Ophthalmology & Visual Science, UMDNJ-New Jersey Medical School, Doctors Office Center, 90 Bergen Street, Suite 6168, Newark, NJ 07103, USA, Tel: 973-972-2032; Fax: 973-972-2068; E-mail: Bhagatne@umdnj.edu

Received December 09, 2010; **Accepted** January 14, 2011; **Published** January 17, 2011

Citation: Bhagat N, Tu Y, Zarbin MA (2011) A Case of Vortex Vein Aplasia and Recurrent Idiopathic Uveal Effusion Syndrome. J Clin Exp Ophthalmol 2:116. doi:10.4172/2155-9570.1000116

Copyright: © 2011 Bhagat N, et al. This is an open-access article distributed under the terms of the Creative Commons Attribution License, which permits unrestricted use, distribution, and reproduction in any medium, provided the original author and source are credited.

Fluorescein angiography (FA) of OD revealed delayed peri-papillary choroidal perfusion with multifocal pinpoint RPE leaks of varying sizes in the macula and peripapillary area (Figure 3A and Figure 3B). The late frames illustrated “leopard spot” fluorescence throughout the macula and the mid-periphery OU, but more pronounced OS (Figure 3C, D). B-scan demonstrated moderate diffuse homogenous choroidal thickening (OD 3.5mm, OS 2.0mm) (Figure 4A). Shallow suprachoroidal fluid was noted in the inferotemporal periphery. The sclera appeared minimally thickened with no T-sign (T-sign indicates scleral thickening due to fluid accumulation in Tenon’s space in the region of optic nerve [5]). Axial length measurements were 22.42 mm (OD) and 23.67 mm (OS) via A-scan. Ultrasound Biomicroscopy (UBM) showed annular thickening of the ciliary body OD. Ciliary body detachment was noted in the inferotemporal quadrant (Figure 4B).

A comprehensive blood work-up for posterior uveitis was only significant for an elevated T4 (103.7 µg/dl) with normal free T4 and TSH. Medical evaluation revealed no signs of lympho proliferative disorders. Syphilis, sarcoidosis, tuberculosis, collagen vascular diseases and HIV were eliminated with appropriate tests. Vogt-Koyanagi-Harada (VKH) syndrome was unlikely given the lack of systemic findings and presence of outflow obstructive signs. Lumbar puncture exhibited a normal opening pressure, and cerebral spinal fluid (CSF) analysis revealed normal composition and cytology.

As the patient’s BCVA worsened to 20/400 OD over the following six weeks, the steroids were tapered off and a diagnosis of IUES was made.

Surgical placement of scleral windows was performed. A limbal peritomy was performed for 360 degrees. The subtenons’ space was dissected posterior to the equator in all four quadrants. Each quadrant was extensively and meticulously inspected for vortex veins but none were noted. Four 4 x 4 mm² scleral windows- (90-95% depth) were constructed in each quadrant (Figure 5). Subretinal fluid was noted to slowly exude through the newly constructed scleral windows. The patient was noted to have inferior serous detachment from two o’clock meridian to ten o’clock at the completion of the surgery.

Histological analysis of the scleral specimens using transmission electron microscopy (TEM) disclosed randomly arranged collagen fibers. Some areas of disruption of normal lamellar arrangement of fibers with fraying of the collagen fibrils into 50 nm filaments were noted along with GAG deposits.

The serous retinal detachment resolved within four months after surgery and the BCVA returned to 20/40 at 6 months (Figure 6). However, four years later, the patient returned with decreased vision of 20/100 in OD with recurrent inferior serous RD involving the macula. FA revealed multiple pin-point areas of RPE leaks in peri-macular area, and diffuse choroidal thickening was present on the B-scan.

Intra operatively, thick fibrous tissue growth was noted in each of four previously-constructed scleral windows. The fibrous tissue was scraped off until dark grey hue of choroid was noted; approximately 10% of sclera remained. Pathology of the removed fibrous tissue disclosed fragments of fibro collagenous tissue. The serous RD slowly resolved within four months with BCVA of 20/50 at the two-year follow-up. There has been no recurrence during 27-month surveillance.

Discussion

IUES is a very rare condition characterized by serous retinal detachment, usually without abnormal IOP and significant inflammation. Elagouz et al. [4] suggest categorization of IUES into

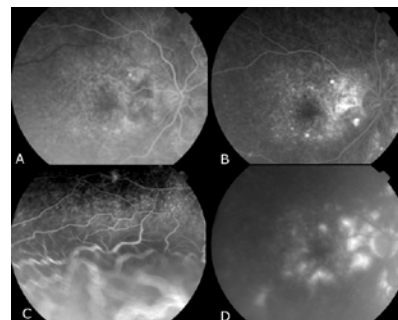


Figure 3: Fluorescein angiography of OD at presentation shows multifocal pinpoint RPE leaks of varying sizes in the macula and peri-papillary area in early (A,B) and late frames (C,D).

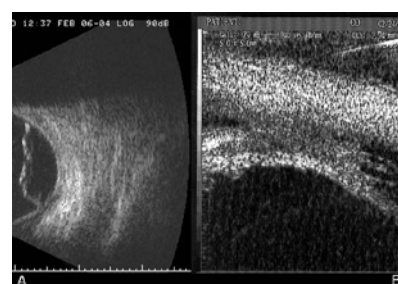


Figure 4: A: B-scan shows diffuse choroidal thickening in OD; B: UBM shows ciliary body detachment in inferotemporal quadrant OD.

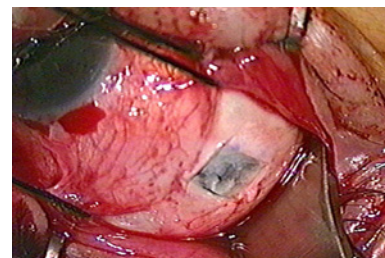


Figure 5: A 4 x 4 mm² scleral window resection (90-95% depth) in the inferonasal quadrant OD.

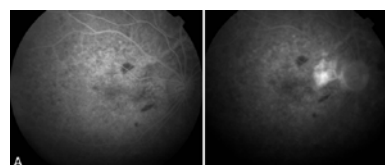


Figure 6: Fluorescein angiography of OD, 6 months after the scleral window resection shows resolution of the RPE leaks.

hypermetropic or nanophthalmic and idiopathic groups [4]. IUES should only be diagnosed after exclusion of other etiologies, such as inflammatory or hydrostatic effusion. The onset of IUES in our patient may be traced back ten years prior to referral when he was diagnosed with a serous retinal detachment in OS, whereas the involvement of the fellow right eye may have begun four years prior to referral when he was diagnosed with central serous chorioretinopathy.

Uveal vasculature is a highly fenestrated and permeable structure. Various mechanisms exist to maintain protein and fluid homeostasis within the uvea, including the vortex veins, transscleral albumin diffusion, transscleral hydrostatic water movement, and bulk flow

around the sclera emissaria [4]. When those mechanisms are impaired, extravasated protein and fluid are retained in the suprachoroidal space, leading to choroidal effusion. Elagouz et al. [4] proposed mechanisms for pathogenesis of IUES such as abnormalities of the sclera including reduced scleral protein permeability, reduced scleral hydraulic conductivity, vortex vein compression, increased choroidal vessel permeability, chronic choroidal inflammation, and chronic hypotony [4]. Altered scleral permeability and vortex vein compression can each contribute to the pathogenesis of IUES, but the relative contribution of each may vary in individuals [4].

We speculate that IUES in our patient may be due to reduced scleral permeability related to the deposition of GAG-like material in the sclera and aplasia of vortex veins.

Histological examination of our patient's sclera showed disruption of normal lamellar structure along with GAG deposits. It is known that the existence of GAG-like material impedes diffusion of macromolecules such as serum albumin across sclera [6]. Fluid then accumulates under the increased osmotic pressure. Fibrous tissue growth into the scleral windows caused relative outflow obstruction and recurrence of IUES four years after complete recovery was achieved. Debridement of the fibrotic tissue from the scleral windows, however, resulted in remission suggesting scleral abnormality to be the primary culprit in our case.

The clinical finding of vortex vein aplasia in this patient is plausible as the second cause of IUES in our case. Vortex vein compression was proposed early in 1975 by Shaffer and later supported and well accepted by others [7]. Variation in the caliber and even absence of the vortex veins reported by Gass in 1982 among their IUES patients implies that there is high plasticity in vortex vein and choroidal vasculature [2]. Therefore, we tentatively propose that the patient may have suffered a developmental aplasia of vortex veins. The congenitally abnormal and overtaxed sclera may have been compromised gradually by aging and hormonal changes in collagen structure and deposition of GAG-like material in the sclera [8]. An unknown insult, such as a mild ocular inflammation or cataract surgery performed within the previous year, may have further reduced scleral permeability to a critical point, resulting in the onset of serous RD.

In 1980, Brockhurst proposed a treatment combination of vortex vein decompression (through sclerectomy) and sclerotomy in nanophthalmic cases with thickened sclera [9]. In 1982, Gass and Jallow [2] demonstrated that full thickness scleral incisions alone were an effective treatment [2]. In our patient, this technique resulted in

successful retinal reattachment initially, but RD recurred 4 years later when fibrous growth led to closure of the windows. It has been reported that instillation of corticosteroids or mitomycin-C in the sclerostomies may prevent fibrous ingrowth and closure of the scleral windows [3,10]. The recurrence in our patient was successfully managed by a simple debridement of the sclera windows. Remission has been maintained for over 2 ½ years.

Conclusion

We report a case of recurrent IUES. IUES is an extremely rare but treatable, sight-debilitating condition. Timely diagnosis is crucial to ensure a vision-saving treatment. Scleral window placement can serve as effective treatment in patients with abnormal sclera. Given that IUES has a relapsing-remitting clinical course and can involve the fellow eye even after many years, long-term follow-up and close monitoring is vital even after successful surgery.

Funding

Supported by an unrestricted grant from Research to prevent blindness.

References

1. Schepens CL, Brockhurst RJ (1963) Uveal effusion. I. Clinical picture. Arch Ophthalmol 70: 189-201.
2. Gass JDM, Jallow S (1982) Idiopathic serous detachment of the choroid, ciliary body, and retina (uveal effusion syndrome). Ophthalmology 89: 1018-1032.
3. Gass JDM (1997) Idiopathic Uveal Effusion Syndrome. Stereoscopic Atlas of Macular Disease: diagnosis and treatment. (4th edn) St. Louis: Mosby 200-208. Volume 1.
4. Elagouz M, Stanescu-Segall D, Jackson TL (2010) uveal effusion syndrome. Surv Ophthalmol 55: 134-145.
5. Byrne SF, Green RL (1992) Ultrasound of the eye and orbit. Mosby-Year Book, Inc, St. Louis.
6. Levick JR (1987) Flow through interstitium and other fibrous matrices. Q J Exp Physiol 72: 409-437.
7. Calhoun FP Jr (1975) The management of glaucoma in nanophthalmos. Trans Am Ophthalmol Soc 73: 97-122.
8. Gass JDM (1983) Uveal effusion syndrome: a new hypothesis concerning pathogenesis and technique of surgical treatment. Retina 3: 159-63.
9. Brockhurst RJ (1980) Vortex vein decompression for nanophthalmic uveal effusion. Arch Ophthalmol 98: 1987-1990.
10. Akduman L, Adelberg DA, Del Priore LV (1997) Nanophthalmic uveal effusion managed with scleral windows and topical mitomycin-C. Ophthalmic Surg Lasers 28: 325-327.