

Identification of Diabetic Maculopathy Stages using Fundus Images

Nishanth K* and Karthik G

Department of ECE, MLR Institute of Technology, Hyderabad, India

Abstract

The impairment and blindness are caused due to Diabetes mellitus. Most of sick person are suffering with impairment diabetes and fifty to sixty percent of ill persons are suffering due to blindness diabetes. Present paper concentrated the identification process of diabetes mellitus using a computer-based intelligent system. The method consists of non-clinically and clinically significant maculopathy and usual eye images. With the help of morphological image processing techniques the fundus are extracted from the usual eye images. Later for comparison the extracted data is applied to classifiers named as (i) feed-forward ANN and (ii) (PNN) probabilistic neural network.

Keywords: Non-clinically maculopathy; Clinically maculopathy; CSME image; Non-CSME image; Artificial Neural Network

Introduction

Today's scenario the eradication of progression of diabetes is a major challenge. It is very difficult to identify side effects due to diabetic immediately. The effects will gradually and silently develop over the time, during the time patient can't predict the complications. As per WHO estimation, out of 37 million cases 4.8% cases are suffering due to diabetic retinopathy, which leads to blindness. Macula is inner part of retina which is very sensitive area, help to reading and color vision [1]. It is located in the center part of the retina and very near the optic nerve. The optic nerve is the sparkling region on the fundus image and usually located inner part of the eye where the optic nerve and retina are joined together (Figure 1).

Figure 1 shows a usual retina with blood vessels are cascading toward the macula. Normally four different sets of eye illness, known as, normal or moderate maculopathy, severe maculopathy and mild maculopathy retina. The method consists of non-clinically and clinically significant maculopathy. The severe maculopathy is classified CSME whereas moderate maculopathy and mild maculopathy are classified as Non-CSME [2].

Significant of non-clinically maculopathy

In Non-CSME stage, exudates begin to pass out from the spoiled retina vessels which will effects from diabetes. In this Non-CSME stage, the ill persons Macula are not seriously affected.

Significant of clinically maculopathy

In this stage, most of the retina with blood vessels is injured. This result will be effect to the Macula. So, ill persons are suffering due to blindness.

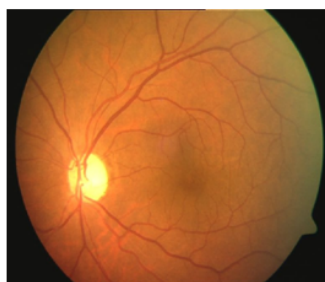

Figure 1: Human retina.

The below images shows the fundus images of usual eye, CSME image and non-CSME image (Figure 2).

Morphological Image Processing

Pre-processing

The colors of fundus collected as samples from various ill persons are found different. The root cause for dissimilarity is depends on the ill person's iris color and skin pigmentation. There exist other more reasons like intrinsic attribute of lesions, lighting disparity, and decreasing color dispersion at the lesion periphery etc.

The following steps are involved in pre-processing of image:

- 1) The Red Green Blue (RGB) image is altered into a grayscale image.

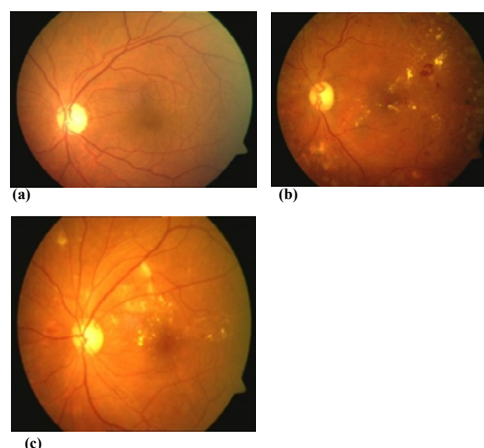


Figure 2: Fundus images: (a) Usual image (b) CSME (c) Non-CSME.

*Corresponding author: Nishanth K, Department of ECE, MLR Institute of Technology, Hyderabad, India, Tel: 8688061351, 9505109726; E-mail: Kalkuntla.nishanth@gmail.com

Received June 20, 2015; Accepted July 10, 2015; Published July 28, 2015

Citation: Nishanth K, Karthik G (2015) Identification of Diabetic Maculopathy Stages using Fundus Images. J Mol Imag Dynamic 5: 118. doi:[10.4172/2155-9937.1000118](https://doi.org/10.4172/2155-9937.1000118)

Copyright: © 2015 Nishanth K, et al. This is an open-access article distributed under the terms of the Creative Commons Attribution License, which permits unrestricted use, distribution, and reproduction in any medium, provided the original author and source are credited.

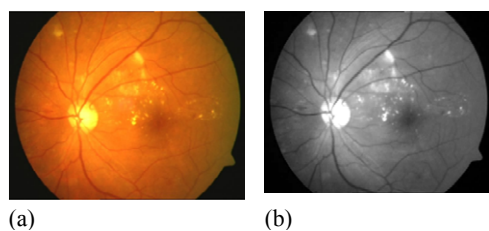


Figure 3: (a) image (b) intensity values adjusted image.




Figure 4: Image segmentation.

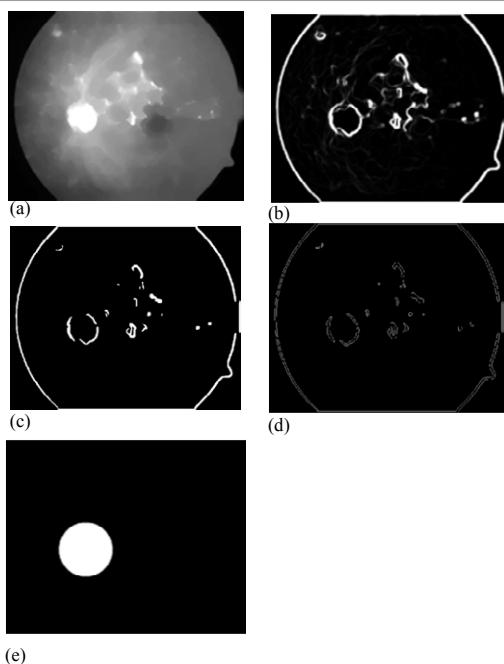


Figure 5: (a) Output of morphological image, (b) Image segmentation, (c) Binary converted image, (d) identification of the optic disc, (e) Optic disc in circular shape.

- 2) With the help of adjust functions, the intensity levels are adjusted in the corresponding image (Figure 3).

Image segmentation

Image segmentation is the process of partitioning a digital image into multiple segments (sets of pixels, also known as super pixels). This is to super pixels that have various colors into various regions. The result of image segmentation is a set of segments that collectively cover the entire image (Figure 4).

Detection of optic disc

The optic disc present at retinal nerve vessels from the eye, where the

entrance and exit point for the retinal blood vessels exists. The feature of optical disc resembles like retinal image features. Figure 5a shows the output of this morphological image [3]. An image segmentation operation was applied to set each morphological image we calculate the variance of the respective image, the image pixel value in between 8-by-8 as depicted in Figure 5b. The result of Figure 5b image was converted into binary form with threshold of 0.95, shown in Figure 5c. Optic disc center was considered as reference image. Figure 5d depicts the identification of the optic disc. To cover the entire optic disc image a circular shape is created with respective radius as depicts in Figure 5e.

Artificial Neural Network (ANN)

The following constitution is related to ANN

i) Adaptive learning: ANN is able to learn and perform tasks based on the given data for training.

ii) Self-organization: It is able to create its own organization or represent the data information which receives during the learning time.

iii) Real time operation: ANN computations may be carried out concurrently and it takes the advantage of the ability in which unique hardware devices are being designed and manufactured.

Results and Discussion

Data analysis

Here we are using a Graphical User Interface (GUI) is a graphical display that allows user to perform interactive tasks. The area covered by the exudates in the four regions (R1, R2, R3 and R4) are considered as parameters for identifying the respective maculopathy images [4]. The input data for the ANN and PNN classifiers is the total number of white pixel which indicates the exudates in each region. In normal and non-CSME images, the R1 and R2 values are zero due to the black area on the foveola and fovea regions [5]. Whereas there are R1 values in the minority of the CSME images and R2 values in all CSME images as compare to other images due to the number of white pixels exit in these regions (Figures 6a-6c).

Conclusion

Diabetic maculopathy is resulted from the prolonged diabetes retinopathy and is a leading cause of blindness. It occurs when the retinal blood vessels are spoiled and the exudates leakage area increases, deposit very close to the fovea [6]. Features from the raw images are extracted using image processing techniques, and fed into the ANN and PNN classifiers for classification. We have concluded that the ANN

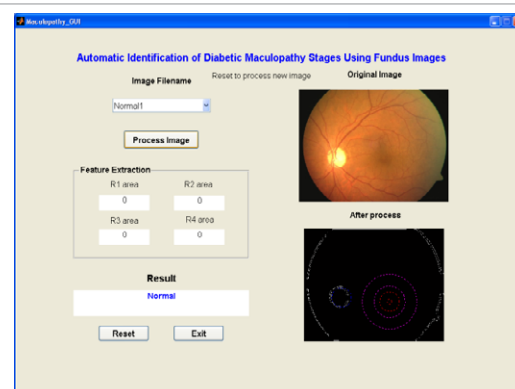


Figure 6a: GUI interface-normal image.

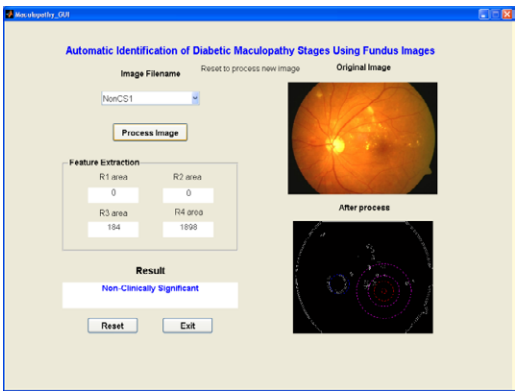


Figure 6b: GUI interface–non-CSME image.

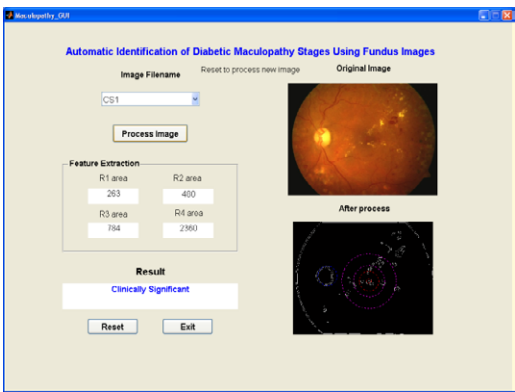


Figure 6c: GUI interface-CSME image.

classifier perform better than PNN classifier with an accuracy of more than 96% of correct classification, and sensitivity of more than 96% and specificity of exactly 100%.The accuracy of the system can further be improved using proper input features such as microaneurysms and Hemorrhages, and the size of the training data.

References

1. Tobin KW, Chaum E, Govindasamy VP, Karnowski TP (2007) Detection of anatomic structures in human retinal imagery. *IEEE Transactions on Medical Imaging* 26: 1729-1739.
2. Nayak J, Bhat, PS, Acharya UR (2009) Automatic identification of diabetic maculopathy stages using fundus images. *Journal of Medical Engineering and Technology* 33: 119-129.
3. Klais CM, Grupchev ID, McGhee CN, Donaldson ML (2004) Photoscreening for diabetic retinopathy - A comparison of image quality between film photography and digital imaging. *Clinical and Experimental Ophthalmology* 32: 393-396.
4. Styles CJ, Park SJ, McGhee CN, Gamble G, Donaldson ML (2007) Evaluating the use of a scanning laser-derived oedema index to grade diabetic retinopathy and maculopathy. *Clinical and Experimental Ophthalmology* 35: 18-23.
5. Peter J, Piantadosi J, Piantadosi C, Cooper P, Gehling N, et al. (2006) Use of real-time telemedicine in the detection of diabetic macular oedema - A pilot study. *Clinical and Experimental Ophthalmology* 34: 312-316.
6. Li H, Chutatape O (2000) Fundus image features engineering in medicine and biology society. *Proceedings of the 22nd Annual International Conference of the IEEE* 4: 3071-3073.