

Case Report

Open Access

Hypohidrotic Ectodermal Dysplasia in Association with Athelia

Iveta Dencheva*, Ivan Botev and Lyubka Miteva

Department of Dermatology and Venereology, Medical University – Sofia, Bulgaria

Abstract

Hypohidrotic ectodermal dysplasia (HED) is characterized by hypohidrosis, hypotrichosis and hypodontia. We present an 11-year-old girl who developed some malformative stigmas at birth such as facial dysmorphism, abnormally low-placed auricles, hypertelorism, and exophthalmia. At present we can identify dry scaly skin; fine sparse and brittle hair, eyebrows, and eyelashes, hypodontia, nail dystrophy, hypohidrosis, and athelia, with deficient hearing and vision. Histopathological examination reveals absence of sweat glands. In this case we discuss the heterogeneity of the ectodermal dysplasias and the clinical criteria for their classification. We present a rare association of hypohidrotic ectodermal dysplasia and athelia.

Keywords: Hypohidrotic ectodermal dysplasia; Athelia

Introduction

Hypohidrotic ectodermal dysplasia, X-linked (Christ-Siemens-Touraine syndrome) is the most common ectodermal dysplasia. It is characterized by partial or complete absence of sweat glands, hypotrichosis and hypodontia. The prevalence of the disease is estimated to be 1 case per 100,000 births. The male sex is affected in 90% of cases. The complete syndrome does not occur in females, but female carriers may show dental defects, sparse hair, reduced sweating and dermatoglyphic abnormalities. The present case demonstrates the major symptoms of hypohidrotic ectodermal dysplasia. A rare association of hypohidrotic ectodermal dysplasia and athelia is reported. To our knowledge this is the seventh case of such an association reported in the literature [1-6].

Case Presentation

We present a 11-year-old girl who was born from second pathology pregnancy in the 35th gestational week, after premature rupture of membranes and data for perinatal asphyxia. According to the accompanying birth medical history, the existence of malformative stigmas was established, like facial dysmorphism – frontal ridges and chin, saddle nose, sunken cheeks, low-set ears, hypertelorism and exophthalmos, micrognathia, 5 teeth, dry scaly skin and fine sparse hair, eyebrows and eyelashes. The mother denies any family medical history.

The clinical examination showed xerosis cutis, keratosis pilaris and the rare anomaly athelia – the congenital absence of both nipples (Figure 1). On the face, we noticed multiple ephelides, hypotrichosis of the scalp hair, eyebrows and eyelashes (Figures 2 and 3). The skin of the palms and soles was not affected.

The nails were dystrophic, brittle, thin, ridged and yellow colored (Figure 4).

The dental examination showed hypodontia with only one tooth. That is why the patient wears dentures and has developed enanthema on the palate (Figure 5).

The blood test was within normal ranges, the potassium hydroxide (KOH) examination from finger nails was negative.

The patient was examined by an ophthalmologist, who established reduced visual acuity. The consultation with the otorhinolaryngologist showed hearing loss and nasal concretions.

The histological examination demonstrated hyperkeratosis, papillomatosis and fragmented collagen fibers. In the histological preparation sweat glands could not be detected (Figure 6).

The diagnosis of hypohidrotic ectodermal dysplasia was made and we treated the patient only symptomatically with emollients for the dry skin.

Discussion

Ectodermal dysplasias are heterogeneous group of inherited disorders that are defined by primary defects in the development of two or more tissues derived from embryonic ectoderm. The tissues primarily

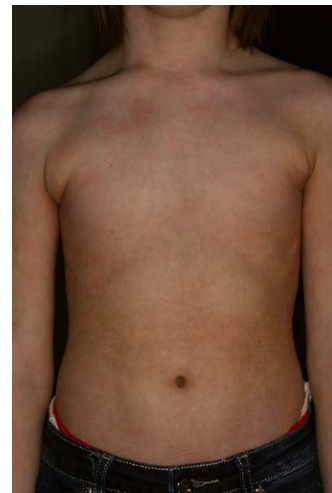

Figure 1: Athelia.

*Corresponding author: Iveta Dencheva, Department of Dermatology and Venereology, Medical University – Sofia, 1, St. Georgi Sofiiski Blvd., Sofia 1431, Bulgaria, Tel: 359-887-330202; E-mail: iv.dencheva@abv.bg

Received May 29, 2014; Accepted July 28, 2014; Published July 30, 2014

Citation: Dencheva I, Botev I, Miteva L (2014) Hypohidrotic Ectodermal Dysplasia in Association with Athelia. J Genet Syndr Gene Ther 5: 233. doi:10.4172/2157-7412.1000233

Copyright: © 2014 Dencheva I, et al. This is an open-access article distributed under the terms of the Creative Commons Attribution License, which permits unrestricted use, distribution, and reproduction in any medium, provided the original author and source are credited.

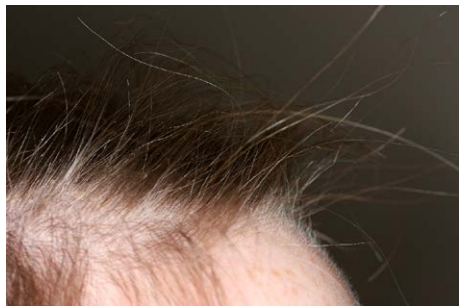

Figure 2: Hypotrichosis of the scalp hair.

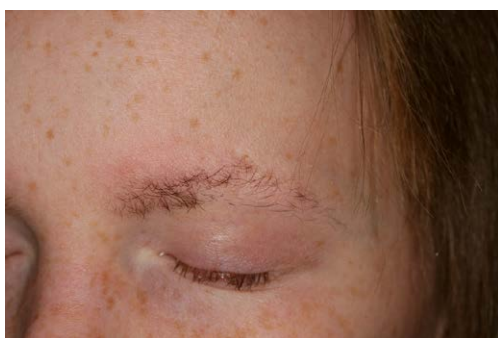

Figure 3: Hypotrichosis of the eyebrows and eyelashes.

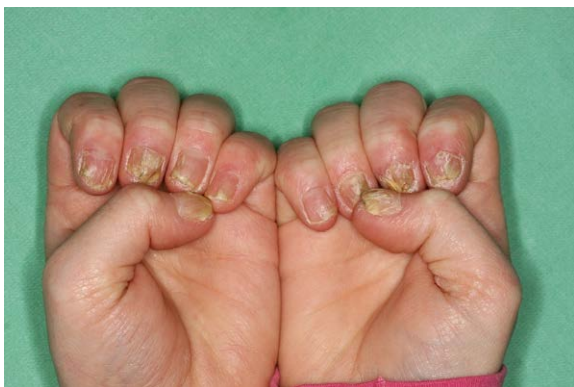

Figure 4: Dystrophic nails.

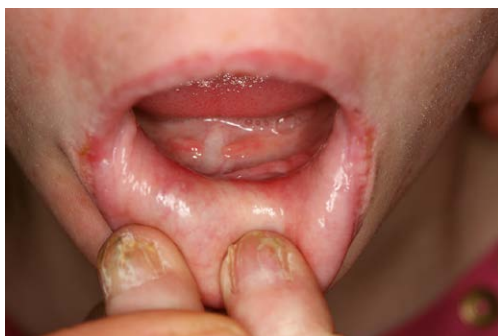

Figure 5: Hypodontia.

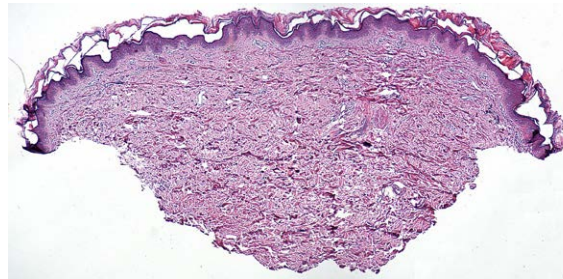


Figure 6: Hyperkeratosis, papillomatosis and fragmented collagen fibers; absence of sweat glands (Haematoxylin-eosin staining, x40).

involved are the skin, hair, nails, eccrine sweat glands, and teeth. At present, more than 150 types of ectodermal dysplasias are known. The most frequent forms are hypohidrotic ectodermal dysplasia (HED) or anhidrotic ectodermal dysplasia (Christ-Siemens-Touraine syndrome) and hidrotic ectodermal dysplasia (Clouston syndrome).

Ectodermal dysplasia was first described in 1848 by Thurnam [7] and later by Darwin [8]. Weech [9] in 1929 found the depression of sweat gland function, and coined the term “anhidrotic ectodermal dysplasia”.

The X-linked form of HED occurs in a approximately 1 in 100,000 liveborn boys and happens in all racial and ethnic groups. The complete syndrome does not occur in females, but female carriers may show dental defects, sparse hair, reduced sweating and dermatoglyphic abnormalities [10,11]. Burck and Held [12] reported a case report of a female infant with athelia. Her mother, maternal aunt and grandmother show hypodontia, sparse hair and small breasts associated with mammillary hypoplasia. Autosomal recessive and autosomal dominant forms of hypohidrotic ectodermal dysplasia have been reported but are rare. Phenotypically, they are indistinguishable from the X-linked form, except that the complete syndrome occurs in both sexes. It has been claimed that the sweating deficiency is less severe in the autosomal recessive form. Sweat glands are reduced in number but are not absent.

The hypohidrotic ectodermal dysplasias are caused by genetic defects in the ectodysplasin signal transduction pathway. Epithelial cells in the developing tooth, hair follicle and eccrine sweat gland utilize this pathway during morphogenesis, and genetic defects in the pathway result in aplasia, hypoplasia or dysplasia of these structures. With activation, a transcription factor, NF- κ B, is translocated into the nucleus of these cells and alters the expression of an unknown number of target genes [13].

The X-linked form results from mutations in ectodysplasin A gene (EDA1) that code for a protein belonging to a tumor necrosis factor (TNF) ligand superfamily. A minority of patients with HED phenotype displays an autosomal recessive or autosomal dominant inheritance pattern. Both of these forms result from mutations in two functionally linked genes EDA-A1 receptor (EDAR) located on chromosome 2q11-q13 and EDA-A1 receptor death domain (EDARDD) on chromosome 1q42.2-q43. The EDAR is activated by EDA and use EDARADD as an adaptor to build an intracellular signal-transducing complex, which is necessary for normal development of ectodermal organs both in humans and in mice [14].

Conclusion

Ectodermal dysplasia is a rare and serious condition. Temporary

and permanent teeth may be entirely absent. Regular dental supervision is essential and dentures may be required at an early age. Absent or reduced sweating causes heat intolerance. The use of DNA-based mutational analysis offers the opportunity for prenatal diagnosis.

References

1. Alcón Saez JJ, Elía Martínez MA, Elía Martínez I, Pont Colomer M, Lurbe Ferrer E (2008) [Amastia and athelia as an exceptional presentation of hypohidrotic ectodermal dysplasia in an adolescent female]. *Pediatr (Barc)* 69: 289-290.
2. Triolo O, Allegra A, Stella Brienza L, De Meo A, Tropea G (1993) [Familial ectodermal dysplasia with agenesis of the breasts and the external urethral sphincter. Description of a case]. *Minerva Ginecol* 45: 139-142.
3. Suvorova KN, Sazonova NS (1974) [Ectodermal dysplasia with athelia and decalvant follicular keratosis]. *Pediatriia* 3: 85-88.
4. Iamin MT, Kumar VP (2003) Complete absence of breasts in a 24-year-old woman associated with ectodermal dysplasia. *Plast Reconstr Surg* 111: 959-961.
5. Klinger M, Caviggioli F, Banzatti B, Fossati C, Villani F (2009) Ectodermal dysplasia with amastia: a case of one-step reconstruction. *Case Rep Med* 2009: 927354.
6. Fan H, Ye X, Shi L, Yin W, Hua B, et al. (2008) Mutations in the EDA gene are responsible for X-linked hypohidrotic ectodermal dysplasia and hypodontia in Chinese kindreds. *Eur J Oral Sci* 116: 412-417.
7. Thurman J (1848) Two cases in which the skin, hair and teeth were very imperfectly developed. *Med Chir Trans* 31: 71-82.
8. Darwin C (1875) *The variations of animals and plants under domestication*. John Murray, London.
9. Weech AA (1929) Hereditary ectodermal dysplasia (congenital ectodermal defect): A report of two cases. *Am J Dis Child* 37: 766-790.
10. Pinheiro M, Freire-Maia N (1979) Christ-Siemens-Touraine syndrome: A clinical and genetic study analysis of a large Brazilian kindred. *Am J Med Genet* 4: 113-122.
11. Verbov J (1970) Hypohidrotic (or anhidrotic) ectodermal dysplasia--an appraisal of diagnostic methods. *Br J Dermatol* 83: 341-348.
12. Burck U, Held KR (1981) Athelia in a female infant - heterozygous for anhidrotic ectodermal dysplasia. *Clin Genet* 19: 117-121.
13. Kere J, Srivastava AK, Montonen O, Zonana J, Thomas N, et al. (1996) X-linked anhidrotic (hypohidrotic) ectodermal dysplasia is caused by mutation in a novel transmembrane protein. See comment in PubMed Commons below *Nat Genet* 13: 409-416.
14. Haghghi A, Nikuei P, Haghghi-Kakhki H, Saleh-Gohari N, Baghestani S, et al. (2013) Whole-exome sequencing identifies a novel missense mutation in EDAR causing autosomal recessive hypohidrotic ectodermal dysplasia with bilateral amastia and palmoplantar hyperkeratosis. *Br J Dermatol* 168: 1353-1356.