

Hypercoagulability in Malignancy and a Rare Case of Embolic Stroke as a Consequence of Nonbacterial Thrombotic Endocarditis in Ovarian Clear Cell Carcinoma

Kerem Can Yilmaz*, Senem Has Hasirci, Ugur Abbas Bal and Leyla Elif Sade

Department of Cardiology, Baskent University School of Medicine, Ankara, Turkey

*Corresponding author: Kerem Can Yilmaz, Baskent University School of Medicine, Cardiology, Fevzi Cakmak Caddesi, 10.sokak No:45, 06570, Türkiye, Ankara, Ankara 06570, Turkey, Tel: +905358887668, E-mail: keremcny@hotmail.com

Rec date: Jan 12, 2015, Acc date: Jan 31, 2015, Pub date: Feb 7, 2015

Copyright: © 2015 Yilmaz KC, et al. This is an open-access article distributed under the terms of the Creative Commons Attribution License, which permits unrestricted use, distribution, and reproduction in any medium, provided the original author and source are credited.

Introduction

Nonbacterial thrombotic endocarditis (NBTE) is a rare manifestation of hypercoagulability in malignancy and very rarely seen in ovarian clear cell carcinoma (OCCC). Systemic embolization to multiple organs secondary to NBTE is common, with embolization to the brain ranging from 14–91%. A few case reports have shown the association between NBTE and OCCC, but we report a rare association of NBTE and OCCC presenting with embolic stroke.

Case Report

In our case 41-year old woman with ovarian clear cell carcinoma (OCCC) was admitted to our hospital to receive routine chemotherapy in November 2012. She had diagnosis of stage I OCCC after pulmonary embolism (with another thromboembolic event) in May 2011. At the time of presentation, she was status post-total abdominal hysterectomy and bilateral salpingo-oophorectomy, and had received 6 cycles of chemotherapy with carboplatin and paclitaxel. At follow up, a CT of the thorax, abdomen and pelvis was done to monitor the progression of OCCC, which showed new metastases to the liver and lungs in May 2012, and had begun topotecan treatment. Echocardiography was performed for patient's exertional dyspnea, revealed that severe aortic regurgitation with multiple vegetations on the aortic valve. Transesophageal echocardiography showed most of vegetations were in non-coronary cusp and severe eccentric aortic regurgitation (Figures 1-3). Patient had no fever or any other symptoms of bacterial endocarditis and we did not isolate any specific microorganism in eight blood samples. In follow-up, patient had seizures without loss of motor function and cranial diffusion magnetic resonance imaging was compatible with multiple acute and subacute infarcts. Other confounding factors for stroke, including paroxysmal nocturnal hemoglobinuria marker, protein C, protein S, factor Leiden V, antithrombin III, antinuclear antibody, lupus anticoagulant, erythrocyte sedimentation rate, homocysteine and vitamin B12 levels, were within normal limits. Seizures recurred under anticoagulant treatment so patient underwent aortic valve replacement and was given warfarin therapy to hold the International Normalized Ratio (INR) between 2.0-3.0.

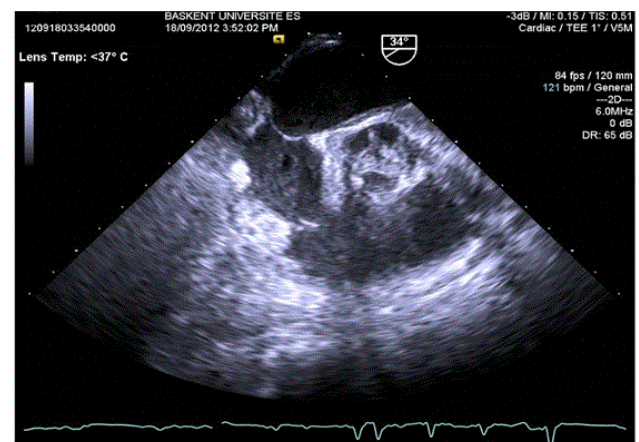


Figure 1: Vegetations of aortic valve in aortic short axis view in transesophageal echocardiography.

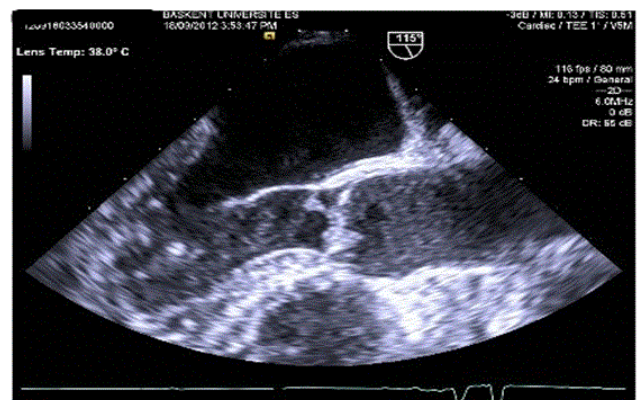


Figure 2: Vegetations of aortic valve in aortic long axis view in transesophageal echocardiography.

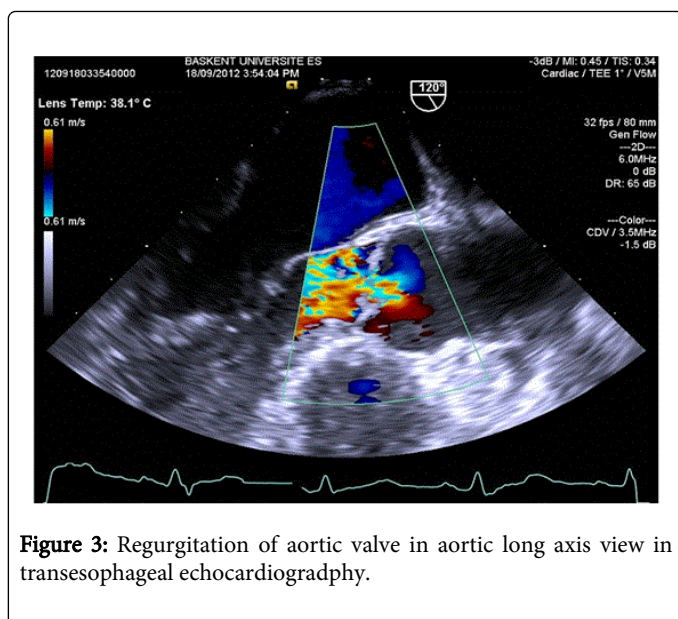


Figure 3: Regurgitation of aortic valve in aortic long axis view in transesophageal echocardiography.

Discussion

Thrombosis is a common complication in cancer patients, with 15% of all cancer patients developing clinically apparent thrombosis [1]. Hypercoagulability in malignancy represents a clinical spectrum ranging from abnormal coagulation tests but no clinically evident thromboembolic disease, to arteriovenous thrombosis, migratory thrombophlebitis, NBTE and disseminated intravascular coagulation [2]. NBTE, also known as marantic endocarditis, is due to uninfected vegetations on heart valves of patients with malignancy, systemic lupus erythematosus, antiphospholipid antibody syndrome or other diseases that manifest with hypercoagulability. Pathogenesis of NBTE is considered to be similar to the mechanisms underlying cancer hypercoagulability. General factors, tumor-specific factors and chemotherapy-related factors can play a role in disorders of coagulation in patients with cancer. When interacting with host cells, malignant cells can release procoagulant and fibrinolytic substances as well as inflammatory cytokines such as interleukin 1 β (IL-1 β), tumor necrosis factor alpha (TNF)- α , and vascular endothelial growth factor. Inflammatory cytokines such as TNF- α and IL-1 β derived from malignant cells can induce endothelial cells lining blood vessels to increase tissue factor procoagulant activity and to produce the fibrinolysis inhibitor plasminogen activator inhibitor 1. The combination of the increase in procoagulant activity and decrease in fibrinolytic activity accelerates the prothrombotic potential of endothelial cells in malignancy [3].

Anticancer therapy can also increase the risk of hypercoagulability and thrombosis in cancer patients. A multivariate logistic analysis of risk factors for DVT or pulmonary embolism found that the first lifetime episode of venous thromboembolism diagnosed in the community had a 4-fold increase in cancer patients; this risk was further increased in cancer patients who had received chemotherapy or radiotherapy [4]. Mechanisms for this include the release of procoagulants and cytokines by tumor cells damaged by chemotherapy; direct damage of the vascular endothelium by chemotherapy or radiotherapy; and the reduction in plasma levels of anticoagulant proteins such as antithrombin III, protein C and protein S, likely due to the direct hepatotoxic effects of chemoradiotherapy [3]. It has never been reported before, but the anticancer drugs carboplatin and paclitaxel, received by our patient, may have increased her risk of hypercoagulability.

NBTE can occur at any stage of malignancy, but is commonly seen in the advanced stages. Sometimes it can herald the advancement of the malignancy, as in our patient who initially presented with stage I OCCC, but was found to have advanced malignancy on further workup after detection of NBTE.

Our report illustrates a patient with OCCC who presented with acute cerebrovascular events secondary to NBTE. Adenocarcinoma of the ovary has been described as a cause for NBTE, but clear cell carcinoma of the ovary presenting with NBTE is very rare [5]. This case has been reported because of the rare and unique association of OCCC, NBTE and embolic stroke. NBTE is a rare manifestation of malignancy and is routinely underevaluated. Morbidity and mortality from embolization can be reduced by early identification of NBTE and appropriate anticoagulation. Thus far, there are no specific guidelines regarding appropriate screening and management of NBTE in malignancy. Some case review series in the literature guide current clinical management.

References

1. Rickles FR, Levine MN (2001) Epidemiology of thrombosis in cancer. *Acta Haematol* 106: 6-12.
2. Hussain S (2009) Thrombophilia in malignancy: a review of the literature. *Internet J Int Med* 2009: 8.
3. Falanga A, Donati MB (2001) Pathogenesis of thrombosis in patients with malignancy. *Int J Hematol* 73: 137-144.
4. Heit JA, Silverstein MD, Mohr DN, Petterson TM, O'Fallon WM, et al. (2000) Risk factors for deep vein thrombosis and pulmonary embolism: a population-based case-control study. *Arch Intern Med* 160: 809-815.
5. Oueida Z, Scola M (2011) Ovarian clear cell carcinoma presenting as non-bacterial thrombotic endocarditis and systemic embolization. *World J Oncol* 2: 270-274.