



# Human Mesenchymal Stem Cell Transfusion for End Stage Liver Disease: A Case Series and Literature Review

Wen-Bo Meng<sup>1,2,3,4</sup>, Bing Bai<sup>1,2,3,4</sup>, Ying Li<sup>2,3,4</sup>, Jian-jun Zhang<sup>2,3,4</sup>, Yong-long Guo<sup>2,3,4</sup>, Wen-Ce Zhou<sup>2,3,4</sup>, Yan Li<sup>5\*</sup> and Xun Li<sup>2,3,4\*</sup>

<sup>1</sup>Special Minimally Invasive Surgery, 1<sup>st</sup> hospital of Lanzhou university, Lanzhou, China

<sup>2</sup>The Second General Surgery Department, 1<sup>st</sup> hospital of Lanzhou University, Lanzhou, China

<sup>3</sup>Hepatopancreatobiliary Surgery Institute of Gansu Province, Clinical Medical College Cancer Center of Lanzhou University, Lanzhou, China

<sup>4</sup>Key Laboratory of Biological Therapy and Regenerative Medicine Transformation, Gansu, China

<sup>5</sup>Department of Immunology, Cleveland Clinic, Cleveland, OH, USA

\*Corresponding authors: Yan Li, Department of Immunology, Cleveland Clinic, Cleveland, OH, USA, Tel: 001216-444-2200; E-mail: [liy6@ccf.org](mailto:liy6@ccf.org)  
Xun Li, The Second General Surgery Department, 1<sup>st</sup> Hospital of Lanzhou University, Lanzhou, China, Tel: 0931-8625200; E-mail: [drlixun@163.com](mailto:drlixun@163.com)

Received date: Oct 30, 2015; Accepted date: December 16, 2015; Published date: Dec 24, 2015

Copyright: © 2015 Meng W, et al. This is an open-access article distributed under the terms of the Creative Commons Attribution License, which permits unrestricted use, distribution, and reproduction in any medium, provided the original author and source are credited.

## Abstract

Decompensated liver cirrhosis is a severe, life-threatening situation in end-stage liver disease. Liver transplantation is the only effective therapy regarding on this. Unfortunately the shortage of liver donors, vast of patients died during enrolled in the waiting list. There are increasing reports of using stem cell to treat advanced liver disease nowadays worldwide, and if it could be alternative therapy in persons with end-stage liver disease is not so clear. Herein we describe a case series outcome of Umbilical Cord-Derived Mesenchymal Stem Cells (UC-MSCs) transfusions for decompensated liver cirrhosis and also reviewed the literature on stem cell therapy.

**Keywords:** End stage liver disease; Stem cell; Liver cirrhosis

## Introduction

End-Stage Liver Disease (ESLD) is major health problems worldwide; it is the 7th leading cause of death in young and mid-age people, and the 12th leading cause of death in US [1], the ESLD has about 20-50% mortality rates in China. Hepatitis viruses, alcohol, diabetes, autoimmune diseases are the leading causes of decompensated liver cirrhosis which leading to high mortality, morbidity, and high healthcare costs. Because of the extreme shortage of liver donors, although liver transplantation is the only effective therapy for the end-stage liver disease, with increased waiting times and the instability of the organ resource for liver transplantation, approximately 15-20% of listed patients die by the deterioration of liver function during the waiting, and many other patients with ESLD are not candidates for liver transplantation [1]. In the recent decade, a growing amount of literature reporting that appropriate palliative care approach for patients who are suffering ESLD, stem cell therapy is one of the groups showing the potential to provide a valuable adjunct and alternative therapy to liver transplantation and in the management of ESLD and liver failure. Stem cell therapy might be mediated by either a direct contribution to the functional hepatocyte population with embryonic, induced pluripotent or adult stem cell or by the promotion of endogenous regenerative processes with bone marrow derived stem cells, umbilical cord derived mesenchymal stem cell as well. Previously studies have been encouraging and suggested improved liver function in end-stage liver disease, giving the possibility of time wait for transplantation. We describe a case series outcome of Umbilical Cord-Derived Mesenchymal Stem Cells (UC-MSCs) transfusions for decompensated liver cirrhosis as follow and reviewed the literature.

## Case series

Four different etiology decompensated liver cirrhosis patients between 41-60 years old were referred to our clinic for ESLD, include in hepatitis B, hepatitis C, alcoholic, and autoimmune respectively. Detailed history and physical examination had been made to clarify patients without recent infection; the not presence of severe renal, respiratory, cardiac disease; none detectable tumor by ultrasonography, computed tomography, or magnetic resonance imaging; non-biliary disease; none detection of hepatic, portal, or splenic vein thrombosis by Doppler ultrasonography. The therapy conformed to the ethical guidelines of the 1975 Declaration of Helsinki. The ethics committee of the 1st Hospital of Lanzhou University evaluated the study and indicated that there was no risk/discomfort associated. The fresh human virus-free umbilical cords were donated by Heze Bio-tec company, China. Approximately  $1 \times 10^7$  UC-MSCs were infused intravenously into the hepatic artery one time; all participants were followed up 24 months after UC-MSCs transfusions. Clinical parameters, as serum alanine aminotransferase (ALT), serum aspartate aminotransferase (AST), total bilirubin (TBIL), albumin (ALB), prothrombin activity (PTA), model of end-stage liver disease (MELD) score, and Child-pugh score, etc. were collected at baseline, 1, 6, 12, and 24 months (Table 1; Figures 1 and 2). There are no adverse events occurred during 24 months of follow-up. All the parameters improved after transfusion within the first year. The Child-pugh scores and MELD scores are simultaneously decreased in 6 months period and increased slightly afterward (Figure 1). The patient's liver functions (TBIL, ALT, AST, ALB, PTA) got stabilized during the first 6 months, then decreased after one-year's observation (Figure 2).

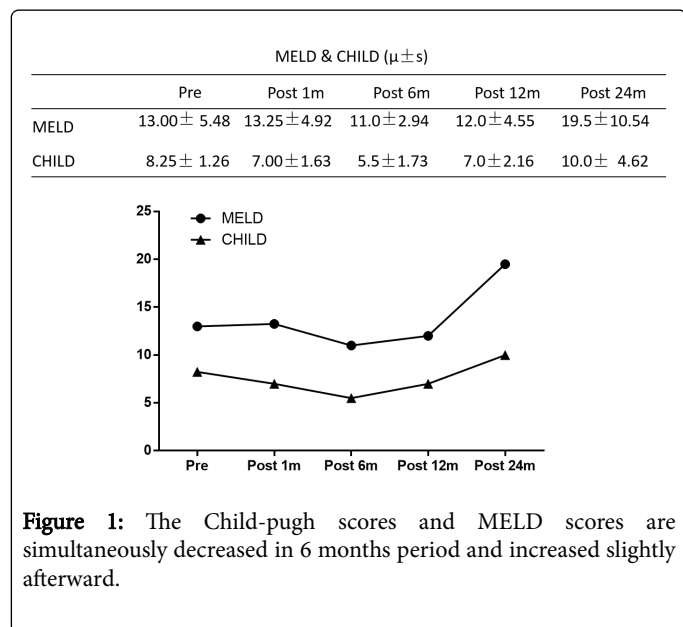
TBIL, ALT, AST & PTA ( $\mu \pm s$ )					
	Pre	Post 1 m	Post 6 m	Post 12 m	Post 24 m
TBIL ( $\mu\text{mol/L}$ )	26.93 $\pm$ 15.30	30.48 $\pm$ 11.13	28.35 $\pm$ 9.70	36.95 $\pm$ 17.22	55.18 $\pm$ 33.10
ALT (U/L)	22.25 $\pm$ 6.24	24.00 $\pm$ 6.58	25.25 $\pm$ 3.69	33.00 $\pm$ 5.77	38.75 $\pm$ 7.80
ALB (g/L)	27.50 $\pm$ 6.70	33.55 $\pm$ 7.02	33.48 $\pm$ 5.64	37.88 $\pm$ 6.24	34.70 $\pm$ 12.60
AST (U/L)	29.25 $\pm$ 5.56	32.25 $\pm$ 2.63	34.50 $\pm$ 3.70	45.25 $\pm$ 15.54	50.75 $\pm$ 15.56
PTA (%)	60.50 $\pm$ 41.33	48.75 $\pm$ 22.25	64.40 $\pm$ 13.28	67.75 $\pm$ 25.36	55.50 $\pm$ 14.82

**Table 1:** Clinical parameters, as ALT, AST, TBIL, ALB, PTA, MELD score, and Child-pugh score, were collected at baseline, 1, 6, 12, and 24 months.

### Discussion

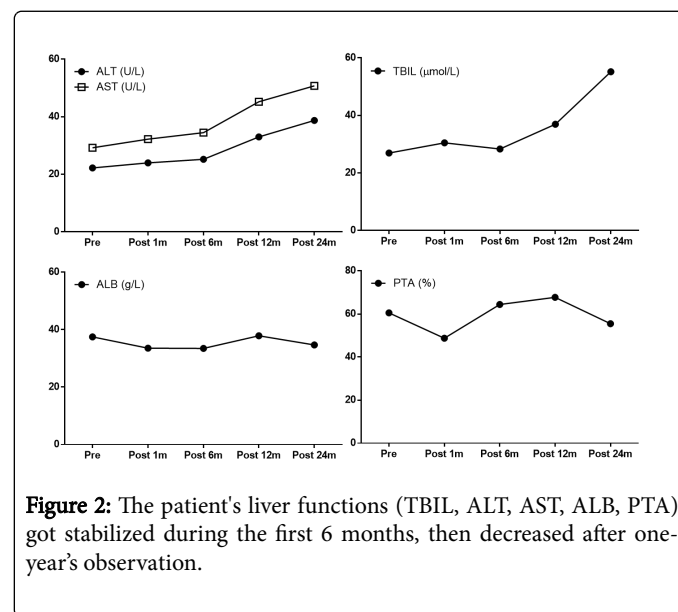
The cause of liver dysfunction varies from infection, tumor, chemical or toxic substances exposure, drug use or variable of illness. Those above contain two main categories as acute liver failure and chronic liver failure. Liver transplantation remains the primary treatment for ESLD. However, the shortage of donor's organ limits current treatment progress. Recent, stem cell still holding a promising in regenerative medicine and immunosuppression function, the mechanism of stem cell therapy considered as homing, differentiation and paracrine effect, there is considerable interest in using stem cells or stem cell differentiated cell to repair the liver structure or improve liver function in ESLD.

scores were observed. Serum albumin levels markedly increased in the third month [6]. Amer et al. infused partially differentiated bone marrow derived MSCs into 20 subjects with HCV-induced cirrhosis via the intrasplenic or portal vein. Compared with the group receiving conventional therapy, the authors claimed recipients of MSCs by either route had improved CHILD and MELD scores and had less fatigue in general [7].



**Figure 1:** The Child-pugh scores and MELD scores are simultaneously decreased in 6 months period and increased slightly afterward.

Currently, it is clear that the hepatocytes have a strong capacity for regeneration, it's the main source of liver regeneration and keep the normal liver function, studies found that during the severe damage or restoration of hepatocytes regeneration, hepatic oval cells can differentiate into hepatocytes and bile duct epithelial cells, therefore, is considered as liver stem cells or progenitor cells [2-5]. Kantarcioğlu et al. infused autologous mesenchymal stem cell into 25 patients with biopsy-proven liver cirrhosis via a peripheral vein. In 8 of the patients, improvements in the Model for End-Stage Liver Disease (MELD)



**Figure 2:** The patient's liver functions (TBIL, ALT, AST, ALB, PTA) got stabilized during the first 6 months, then decreased after one-year's observation.

Most of current *in-vitro* research shows that UC-MSC therapy is more effective than bone marrow-derived stem cell (BM-MSC), UC-MSC has been widely reported that has the ability to differentiate into hepatocytes *in-vitro*, but BM-MSC based research haven't provided such excited data as UC-MSC [8], but El-Ansary et al. [9] indicated that compared to a placebo control group (n=10), the intravenous transfusion of BM-MSCs improved liver function partially (n=15), which effective in HCV-induced cirrhosis group, that indicated the BM-MSC might play a positive role *in-vivo*. The most likely mechanism considered the BM-MSC produced several growth factors, such as hepatocyte growth factor, transforming growth factor- $\alpha$ , heparin-binding epidermal growth factor-like growth factor, and vascular endothelial growth factor, and also elicited endogenous growth factors to stimulate endogenous hepatocytes activation and regeneration [10,11]. Salama et al. assessed the utility of autologous

mesenchymal stem cell peripheral vein infusion as a possible therapeutic modality for patients with end-stage liver diseases, and found that MSCs have a supportive role in the treatment of end-stage liver disease, with satisfactory tolerability and beneficial effects on synthetic liver functions and hepatic fibrosis [12]. Because ESLD's high mortality, morbidity, and Rapid disease progression, protect and maintain current liver function is the top priority before liver transplantation, Shi et al. demonstrated that the 43 Acute-on-Chronic Liver Failure (ACLF) patients associated with Hepatitis B Virus (HBV) infection received the UC-MSCTransfusions therapy, the UC-MSCTransfusions are safe and TBIL and ALT levels were significantly decreased. They found that UC-MSCTransfusions significantly increased the survival rates in ACLF patients; serum cholinesterase, prothrombin activity and platelet counts had been increased; the liver functions as serum Total Bilirubin (TBIL) and Alanine Aminotransferase (ALT) levels were significantly decreased after the UC-MSCTransfusions [13]. During the procedure, the therapy effectiveness depends on the amount of the cells transfused into the liver, the major transfusion route includes adjacent organ (spleen, kidney, and peritoneal cavity) and intravenous (portal vein, hepatic artery and peripheral vein). Mehdi et al. reported that autologous MSC transplantation through a peripheral vein is safe and feasible in the treatment of liver cirrhosis [14]. Malekzadeh et al. also find that autologous MSC transplantation through a peripheral vein is safe and feasible in patients with liver cirrhosis, and improvements in liver function tests and MELD scores of some of their patients are promising [15]. In addition, Adeeb et al. focuses on evaluating health-related quality of life using the International Short Form 36-Item Health Survey in chronic liver disease patients, who received either Stem Cell Therapy (SCT) or Supportive Medical Treatment (SMT), and they found that patients who underwent SCT showed marked improvements in all domains of the evaluation, much lower mortality rates, and complete absence of malignancy, compared with patients enrolled in SMT [16]. Above-mentioned results and clinical trials show that MSCs transfusion is a safe and feasible method to improve liver function in ESLD.

## References

1. US Department of Health and Human Services, H.R.a.S.A., U.S. Organ Procurement and Transplantation Network and the Scientific Registry of Transplant Recipients, OPTN/SRTR annual report: transplant data 1999-2008.
2. Rountree CB, Wang X, Ge S, Barsky L, Zhu L, et al. (2007) Bone marrow fails to differentiate into liver epithelium during murine development and regeneration. *Hepatology* 45: 1250-1260.
3. Zhang Y, Bai XF, Huang CX (2003) Hepatic stem cells: existence and origin. *World J Gastroenterol* 9: 201-204.
4. Gennero L, Roos MA, Sperber K, Denysenko T, Bernabei P, et al. (2010) Pluripotent plasticity of stem cells and liver repopulation. *Cell Biochem Funct* 28: 178-189.
5. Factor VM, Radaeva SA, Thorgeirsson SS (1994) Origin and fate of oval cells in dipin-induced hepatocarcinogenesis in the mouse. *Am J Pathol* 145: 409-422.
6. Kantarcioglu M, Demirci H, Avcu F, Karshoğlu Y, Babayigit MA, et al. (2015) Efficacy of autologous mesenchymal stem cell transplantation in patients with liver cirrhosis. *Turk J Gastroenterol* 26: 244-250.
7. Amer ME, El-Sayed S, El-Kheir WA, Gabr H, Gomaa AA, et al. (2011) Clinical and laboratory evaluation of patients with end-stage liver cell failure injected with bone marrow-derived hepatocyte-like cells. *Eur J Gastroenterol Hepatol* 23: 936-941.
8. Cai J, Zhao Y, Liu Y, Ye F, Song Z, et al. (2007) Directed differentiation of human embryonic stem cells into functional hepatic cells. *Hepatology* 45: 1229-1239.
9. El-Ansary M, Abdel-Aziz I, Mogawer S, Abdel-Hamid S, Hammam O, et al. (2012) Phase II trial: undifferentiated versus differentiated autologous mesenchymal stem cells transplantation in Egyptian patients with HCV induced liver cirrhosis. *Stem Cell Res* 8: 972-981.
10. Nakamura T, Torimura T, Sakamoto M, Hashimoto O, Taniguchi E, et al. (2007) Significance and therapeutic potential of endothelial progenitor cell transplantation in a cirrhotic liver rat model. *Gastroenterology* 133: 91-107.
11. Taniguchi E, Kin M, Torimura T, Nakamura T, Kumemura H, et al. (2006) Endothelial progenitor cell transplantation improves the survival following liver injury in mice. *Gastroenterology* 130: 521-531.
12. Salama H, Zekri ARN, Medhat E, Alim SAA, Ahmed OS, et al. (2014) Peripheral vein infusion of autologous mesenchymal stem cells in Egyptian HCV-positive patients with end-stage liver disease. *Stem Cell Res Ther* 5: 70.
13. Shi M, Zhang Z, Xu R, Lin H, Fu J, et al. (2012) Human mesenchymal stem cell transfusion is safe and improves liver function in acute-on-chronic liver failure patients. *Stem Cells Transl Med* 1: 725-731.
14. Mohamadnejad M, Alimoghaddam K, Mohyeddin-Bonab M, Bagheri M, Bashtar M, et al. (2007) Phase I trial of autologous bone marrow mesenchymal stem cell transplantation in patients with decompensated liver cirrhosis. *Arch Iran Med* 10: 459-466.
15. Malekzadeh R, Mohamadnejad M, Alimoghaddam K, Bagheri M, Baharvand H, et al. (2010) Cell-Based Regenerative Therapy as an Alternative to Liver Transplantation for End-Stage Liver Disease: Experience from Iran. *Int J Organ Transplant Med* 1: 21-7.
16. AlZoubi AM, Khalifeh F (2013) The effectiveness of stem cell therapies on health-related quality of life and life expectancy in comparison with conventional supportive medical treatment in patients suffering from end-stage liver disease. *Stem Cell Res Ther* 4: 16.