

Case Report

Open Access

How Far could a Ureteral Stent become a Cardiovascular Danger?

Chafiki J*, Janane A, Ghadouane M, Ameur A and Abbar M

Department of Urology, Military Hospital of Instruction Mohammed V, Rabat, Morocco

Summary

The drainage of the upper urinary tract by ureteral stent is a routine gesture in endourology. The side effects are usually mild. We report a rare case of simultaneous ureteral and vascular perforation, having trained an intravascular stent migration into the right common iliac vein and the vena cava, in a 33 years old pregnant woman, who presented with a right obstructive pyelonephritis. To our knowledge only a couple of cases have been described.

Introduction

Vascular complications involving the ureter are rare and usually present as an arterio-ureteral fistula. They can arise in several situations including degenerative iliac artery disease [1], previous vascular reconstruction procedures [2], extirpative surgery for pelvic or abdominal malignant disease [3], pelvic irradiation urolithiasis, urinary diversion procedure [4], extensive ureteral mobilization and prolonged indwelling ureteral stent [5]. Venous complications during the installation of the ureteral endoprosthesis are uncommon than arterial complications. We report a very rare case of simultaneous ureter and iliac vein perforation with intravenous migration of a ureteral stent through the inferior vena cava till the right atrium.

Case Report

The report case is about a 33 years old pregnant woman followed for a gestational obstructive pyelonephritis. The ureteral obstruction was related to an eventual compression of the pelvic ureter by the right ovarian vein lasting for one week. Urinary tract infection *Escherichia coli* was treated with amoxicillin and clavulanic acid, 3gramme per day, for 10 days.

A right ureteral stent was placed at 12 weeks of pregnancy for acute obstructive pyelonephritis in a private institution. During the positioning of the ureteral endoprosthesis (7ch, 28 cm, Bard), there were no haemorrhagic complications.

After the pregnancy, the stent was not found in the bladder at the time of removal, a ureteroscopy was performed which did not find the ureteral stent in the urinary tract. A Computed Tomography (CT) was then conducted and showed the intravenous placement of the stent through the right iliac vein into the inferior vena cava till the right atrium (Figures 1 and 2). Then the patient was sent to our institution. Impressively enough, the patient only reported insidious onset of palpitations and moderate right flank pain. Surprisingly, she presented no macroscopic hematuria, possibly due to intra-catheter blood clotting.

The patient was then transferred to the vascular surgery department and an endovascular extraction was performed by a puncture of the femoral vein. The extraction of the endoprosthesis was made by a curved guide introduced through the cavous vein till the right atrium under fluoroscopic control; the guide was twisted around the stent and was pulled out with it. No other complication was noted and the patient was discharged the following day.

Discussion

Ureteral J-stent (pigtail) placement, either retrograde or antegrade is a very common urological as well as radiological interventional procedure. Modern "double pigtail" ureteral stents are soft and are

designed to curl at its two ends to prevent organ trauma and stent migration [6,7]. These stents are used for a wide variety of conditions and, as with all interventional procedures, are accompanied by a number of possible complications. Though renal or urocytic stent migration is commonly seen, intravenous stent migration is not.

Michalopoulos et al. [8] first reported a case of intravascular migration of a J-stent intra-operatively placed in the right ureter which migrated into the venous circulation through one of the intercommunicating ovarian veins. In both the previously mentioned report as well as in this case it is believed that ureteral wall fragility was caused by chronic ureteral trauma due to prior urolithiasis and/or ureteral wall inflammation.

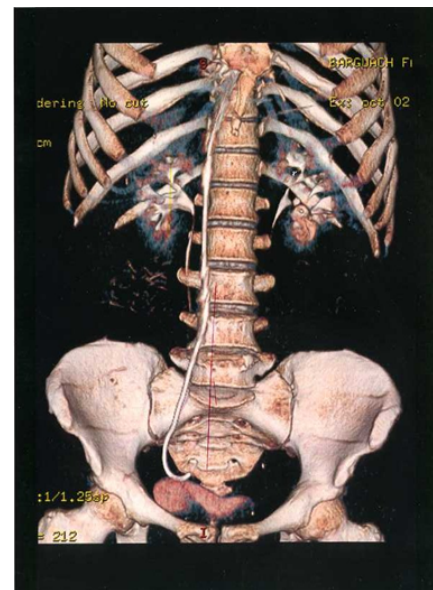


Figure 1: Computed Tomography (CT) reconstruction showing the intravenous placement of the stent through the right iliac vein into the inferior vena cava till the right atrium.

*Corresponding author: Chafiki J, Service d'Urologie Hôpital Militaire Mohamed V, Rabat, Morocco, Tel: 0661329022; E-mail: drjaouad@yahoo.fr

Received June 27, 2014; Accepted September 06, 2014; Published September 13, 2014

Citation: Chafiki J, Janane A, Ghadouane M, Ameur A, Abbar M (2014) How Far could a Ureteral Stent become a Cardiovascular Danger? Med Surg Urol 3: 141. doi:10.4172/2168-9857.1000141

Copyright: © 2014 Chafiki J, et al. This is an open-access article distributed under the terms of the Creative Commons Attribution License, which permits unrestricted use, distribution, and reproduction in any medium, provided the original author and source are credited.

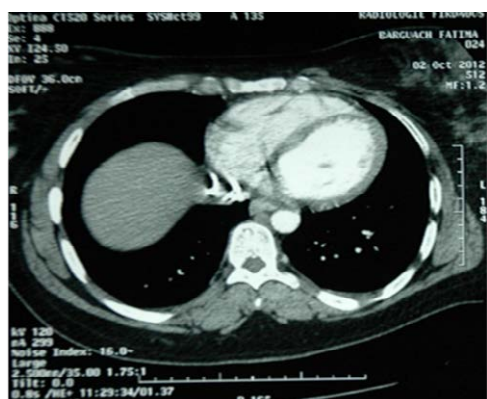


Figure 2: Computed tomography verifying the stent in the right atrium.

In our patient, the ureteral perforation and intravenous migration was generated by the forced transition of the guide wire, and the lack of use of fluoroscopy. The venous perforation is produced on the inner face of the right common iliac vein, the size is estimated at 1 to 2 millimeter, and the breach was quickly clogged after the intravenous migration.

Trauma to the iliac vessels carries a mortality of 30%, mostly from uncontrolled hemorrhage and is a potentially a devastating complication if not immediately diagnosed.

Fortunately, retroperitoneal hemorrhage was preoperatively excluded in our patient by contrast enhanced abdominal computed tomography. Furthermore, Bergqvist et al. reported a great difference in mortality rates in favor of patients undergoing surgery with a preoperative diagnosis of an arterio-ureteral fistula (0% mortality rate in 42 patients) as compared to patients in whom the diagnosis became clear during surgery (39% mortality rate in 18 patients).

Due to the rarity of venous-ureteral fistulas reported in the literature there is no data on the mortality rates of this condition. We can assume that establishing preoperative diagnosis is crucial in order to offer the best treatment. In our case a CT scan permitted to establish the diagnosis, but, late in relation to the operative complication.

Conclusion

As the use of X-ray is very limited during pregnancy, we must always be aware of the possibility of ureteral stent migration during blind placement, that's why ultrasound control might be of great help. This easy and helpful tool allows the immediate recognition of a misplacement of the stent and effective treatment of such a complication.

References

1. Mahoney PF, Stephen JG (1987) External iliac artery-ureteric fistula. *Br J Urol* 60: 374.
2. Di constanso GA, Kalman PC (1988) Erosion of the ureter by ilio-femoral arterial prosthesis. *J Vasc. Surg* 8: 190-192
3. Dervanian P, Castaigne D, Travagali JP (1992) Arterio-ureteral fistula after extended resection of pelvictumours: report of 3 cases and review as the literature. *Ann Vas Surg* 6:362-369
4. Keller FS, Barton RE, Routh WD, Gross GM (1990) Gross hematuria in two patients with ureteral-ileal conduits and double-J stents. *J Vasc Interv Radiol* 1: 69-77.
5. Zweers HM, van Driel MF, Mensink HJ (1991) Iliac artery-ureteral fistula associated with an indwelling ureteral stent. *Urol Int* 46: 213-214.
6. Bergqvist D, Pärsson H, Sherif A (2001) Arterio-ureteral fistula—a systematic review. *Eur J Vasc Endovasc Surg* 22: 191-196.
7. Chew BH, Duvdevani M, Denstedt JD (2006) New developments in ureteral stent design, materials and coatings. *Expert Rev Med Devices* 3: 395-403.
8. Michalopoulos AS, Tzoufi MJ, Theodorakis G, Mentzelopoulos SD (2002) Acute postoperative pulmonary thromboembolism as a result of intravascular migration of a pigtail ureteral stent. *Anesth Analg* 95: 1185-1188.