

## High-Flow Oxygen Therapy for Perioperative Hypoxemia during One-lung Ventilation

Antoine Duwat\*, Philippe Courivaud, Eric Dusart, Gérard Pavy and Cyrille Pila

Departments of Thoracic Surgery and Anesthesia, Les Bonnettes Hospital, Arras, France

\*Corresponding author: Antoine Duwat, Department of Thoracic Surgery and Anesthesia, Les Bonnettes Hospital, Arras, France, Tel: 0609780715; E-mail: Antoineduwat@hotmail.com

Received date: February 01, 2019; Accepted date: February 22, 2019; Published date: February 28, 2019

Copyright: © 2019 Duwat A, et al. This is an open-access article distributed under the terms of the Creative Commons Attribution License, which permits unrestricted use, distribution, and reproduction in any medium, provided the original author and source are credited.

### Introduction

Around 5-10% of patients develop hypoxemia during one-lung ventilation [1]. The change to one-lung ventilation is responsible for the development of intrapulmonary shunt and pulmonary vasoconstriction in response to hypoxia in the non-ventilated lung. The increase in blood flow towards the ventilated lung may also be accompanied by an increase in shunt as a result of hyperflow. However, these adaptive phenomena are sometimes insufficient and may lead to perioperative hypoxemia [2].

The application of an algorithm for the management of patients with hypoxemia is recommended in order to restore correct oxygenation and enable surgery under good conditions [3]. High-flow oxygen therapy (HFOT) has recently been used in the operating room and is of interest for pre oxygenation and apneic oxygenation. In addition to its use in patients with risk factors for difficult intubation, but without predictive factors for difficult face mask ventilation, the important lengthening of the time of apnea without desaturation allows the insertion of an endotracheal intubation device under the best possible conditions [4]. The post-operative use of HFOT plays an important role in the prevention or treatment of respiratory complications, particularly in thoracic surgery [5,6]. High-flow oxygenation has interesting characteristics including physiological conditioning of the air and oxygen (humidified and rewarmed), the possibility of high and adjustable  $FiO_2$ , high flow allowing irrigation of the dead space, and alveolar recruitment. In view of its recent availability in the operating room, it seemed logical to us to use this technique during one-lung ventilation for the treatment of desaturations.

### Technique: High-flow Oxygen Therapy for Hypoxemia during One-lung Ventilation

To our knowledge, this is the first report on the use of HFOT for the treatment of hypoxemia during one-lung ventilation. In patients with desaturation (saturation <92%), and after checking the position of the tube and other treatable causes (position, secretion, hemodynamic problems), we used a  $FiO_2$  of 100% and moderate positive end-expiratory pressure (PEEP) in the ventilated lung. In the case of failure and before recourse to CPAP, we used HFOT (Optiflow®; Fisher & Paykel, New Zealand) by connecting it to the non-ventilated lung. We planned the connection of the high-flow oxygen tube directly onto the tracheostomy interface (Figure 1). The parameters used were a flow of 60 L/min at a temperature of 37°C and an initial  $FiO_2$  of 100%. When

the saturation was >92%, we performed a reduction by alternating the  $FiO_2$  of the respirator to the ventilated lung and then high-flow oxygen to the excluded lung, from 10% by 10% every 5 min to obtain a saturation between 95% and 98%. Titration of the  $FiO_2$  enabled a progressive decrease of the oxygen delivered and therefore avoided potentially deleterious hypoxemia [7].

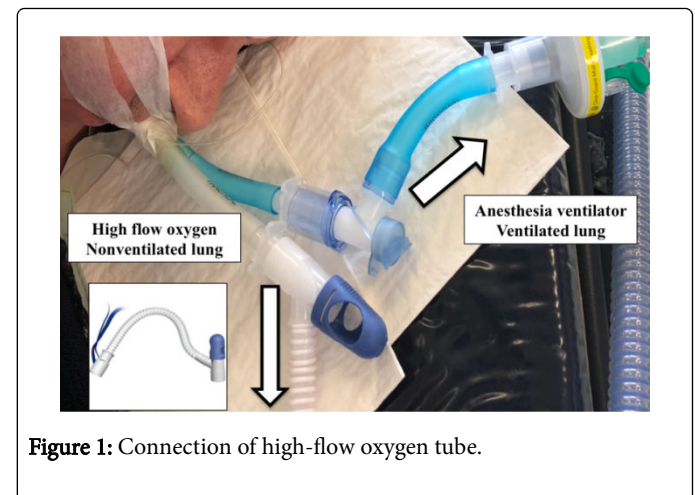


Figure 1: Connection of high-flow oxygen tube.

The parameters used were a flow of 60 L/min at a temperature of 37°C and an initial  $FiO_2$  of 100%. When the saturation was >92%, we performed a reduction by alternating the  $FiO_2$  of the respirator to the ventilated lung and then high-flow oxygen to the excluded lung, from 10% by 10% every 5 min to obtain a saturation between 95% and 98%. Titration of the  $FiO_2$  enabled a progressive decrease of the oxygen delivered and therefore avoided potentially deleterious hypoxemia [7].

In our series of lobectomy treatment for lung cancer (7 thoracotomy and 4 video-assisted thoracic surgery), 11 patients had a desaturation of <92% during one-lung ventilation despite the use of a  $FiO_2$  of 100%, moderate PEEP, and the absence of any treatable causes (Table 1). Median ( $\pm$  standard deviation (SD)) initial saturation was 86% ( $\pm$  3%) before the use of HFOT. The application of our protocol enabled titration of the  $FiO_2$  settings that would result in a saturation >95%. Median ( $\pm$  SD)  $FiO_2$  of the respirator of our patients was 70% ( $\pm$  9%) and median ( $\pm$  SD)  $FiO_2$  of HFOT was 70% ( $\pm$  10%). Median ( $\pm$  SD) time to obtaining a saturation >95% was 94 sec ( $\pm$  31 sec). No patient required CPAP. Visibility for the surgical team was considered to be excellent.

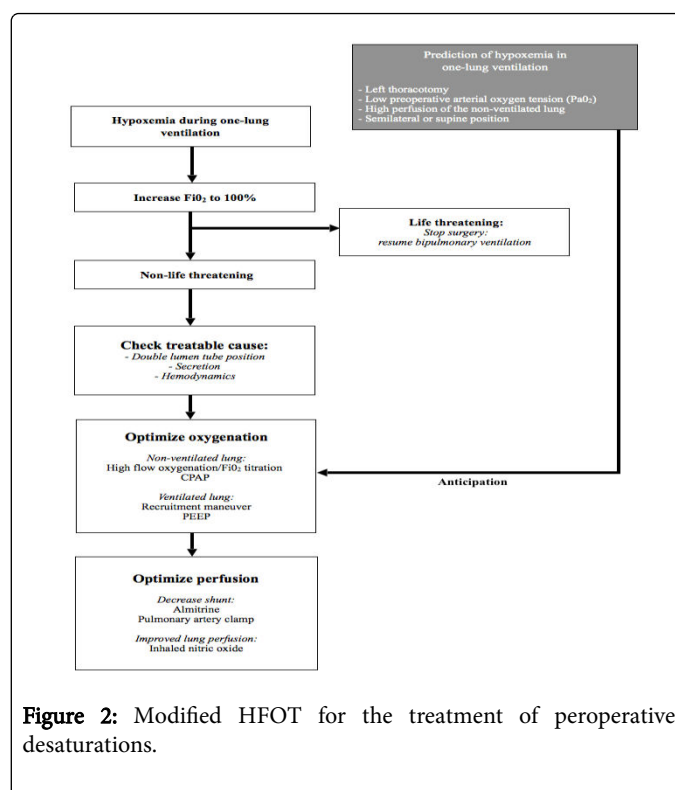
	Initial saturation with FiO <sub>2</sub> 100% (%)	Lowest FiO <sub>2</sub> of HFOT to the excluded lung (%)	Lowest FiO <sub>2</sub> of the respirator to the ventilated lung (%)	Time to obtaining a saturation >95% (sec)
Case 1	84	50	50	68
Case 2	86	60	60	48
Case 3	86	60	60	140
Case 4	84	50	50	118
Case 5	88	80	70	144
Case 6	83	60	60	78
Case 7	89	70	70	64
Case 8	85	70	70	82
Case 9	80	80	80	110
Case 10	88	70	70	94
Case 11	87	70	70	102
Median	86	70	70	94
SD	3	10	9	31

**Table 1:** Series of lobectomy treatment for lung cancer.

## Discussion

The peroperative use of HFOT is a simple, effective and well-tolerated procedure. Its good efficacy can be explained by the delivery of a high FiO<sub>2</sub> with physiological conditioning of the humidified gases. The absence of difficulties for the surgeon can be explained by the use of the cannula for tracheostomy as access to the non-ventilated lung. It has been well documented that the PEEP created by this technique is much lower than with nasal cannulae [8]. The recruitment effect is therefore relatively low and the absence of hyperinflation, which is often found with CPAP, explains the good results concerning the surgical conditions and visibility for mini-invasive surgery. In using HFOT for the treatment of peroperative desaturations, we have modified our management algorithm and have inserted this technique before resorting to CPAP (Figure 2).

In our experience, the need for CPAP has become exceptional. A larger study is necessary to confirm our results and to measure the per- and post-operative impact of this procedure. It's easy and effective use can be proposed systematically, without waiting for hypoxemia to develop in patients who are at risk with preventive treatment. The anticipated effects should be a smaller shunt, an improvement in the comfort for the surgeon and anesthesiologist with less use of CPAP or bipulmonary ventilation, a lower rate of conversion to thoracotomy, and a decrease in need for pharmacological treatment. HFOT is an important therapeutic approach in thoracic surgery with multiple applications in pre-, per- and post-operative management.



**Figure 2:** Modified HFOT for the treatment of peroperative desaturations.

## References

1. Karzai W, Schwarzkopf K (2009) Hypoxemia during one-lung ventilation: prediction, prevention, and treatment. Anesthesiology 110: 1402–1411.

2. Ribas J, Jiménez MJ, Barberà JA, Roca J, Gomar C, et al. (2001) Gas exchange and pulmonary hemodynamics during lung resection in patients at increased risk: relationship with preoperative exercise testing. *Chest* 120: 852-859.
3. Rozé H, Lafargue M, Ouattara A (2011) Case scenario: management of intraoperative hypoxemia during one-lung ventilation. *Anesthesiology* 114: 167-174.
4. Gustafsson IM, Lodenius Å, Tunelli J, Ullman J, Jonsson Fagerlund M (2017) Apnoeic oxygenation in adults under general anaesthesia using Transnasal Humidified Rapid-Insufflation Ventilatory Exchange (THRIVE)-a physiological study. *Br J Anaesth* 118: 610-617.
5. Ansari BM, Hogan MP, Collier TJ, Baddeley RA, Scarci MA (2016) A randomized controlled trial of high-flow nasal oxygen (optiflow) as part of an enhanced recovery program after lung resection surgery. *Ann Thorac Surg* 101: 459-464.
6. Stéphan F, Barrucand B, Petit P, Rézaiguia-Delclaux S, Médard A et al. (2015) High-flow nasal oxygen vs noninvasive positive airway pressure in hypoxemic patients after cardiothoracic surgery: a randomized clinical trial. *JAMA* 313: 2331-2339.
7. Xu Z, Gu L, Bian Q, Pengyi Li, Lijun W, et al. (2016) Oxygenation, inflammatory response and lung injury during one lung ventilation in rabbits using inspired oxygen fraction of 0.6 vs. 1.0. *J Biomed Res* 31: 56-64.
8. Corley A, Edwards M, Spooner AJ, Dunster KR, Anstey C et al. (2017) High-flow oxygen via tracheostomy improves oxygenation in patients weaning from mechanical ventilation: a randomised crossover study. *Intensive Care Med* 43: 465-467.