

## Herpes simplex Keratitis Mimicking Acute Corneal Hydrops

Ellen H Koo\* and Richard K Forster

Bascom Palmer Eye Institute, University of Miami Miller School of Medicine, Miami, USA

\*Corresponding author: Ellen Koo, M.D. Bascom Palmer Eye Institute, Palm Beach Gardens. 7101 Fairway Drive, Palm Beach Gardens, FL 33458, USA, Tel: 561-515-1544; E-mail: [exk126@med.miami.edu](mailto:exk126@med.miami.edu)

Received date: Jul 02, 2015, Accepted date: Aug 21, 2015, Published date: Aug 25, 2015

Copyright: © 2015 Koo EH et al. This is an open-access article distributed under the terms of the Creative Commons Attribution License, which permits unrestricted use, distribution, and reproduction in any medium, provided the original author and source are credited.

### Abstract

**Purpose:** The purpose of this paper is to present a case of a Herpes simplex keratitis presenting as a case of acute corneal hydrops.

**Methods:** Case report.

**Results:** A 57-year-old white woman presented with acute onset of pain, photophobia and decreased vision in the left eye. In the years prior, she had been under the care of her optometrist, who had previously diagnosed her with irregular astigmatism, for which she had been using rigid gas permeable contact lenses for vision correction. At the slit-lamp biomicroscope, the left eye was found to have marked corneal edema with central endothelial folds, as well as a round, paracentral area of stromal haze and opacity. The fellow eye was shown to have inferior areas of anterior stromal scarring. Corneal topography showed markedly irregular astigmatism, with inferior steepening bilaterally. These are findings that could also be seen in acute corneal hydrops. In this case, a diagnosis of Herpes Simplex keratitis was made, and patient showed marked improvement on oral valacyclovir.

**Conclusions:** Herpes simplex keratitis can often be a diagnostic challenge, as it can present itself in various forms. We report a case of Herpes simplex keratitis mimicking acute corneal hydrops.

**Keywords:** Herpes simplex keratitis; Masquerade syndrome; Acute corneal hydrops; Keratoconus; HSV

### Introduction

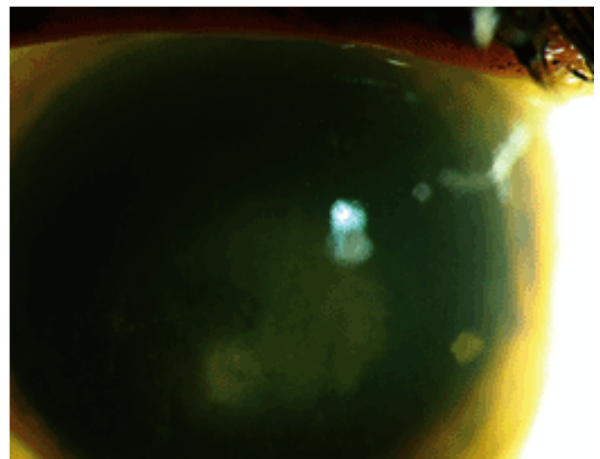
Herpes simplex virus (HSV) is a double-stranded DNA virus, and is classified as an Alphaherpesvirinae, a subgroup of the Herpesviridae family. Ocular HSV disease can be divided into a primary HSV infection, or recurrent disease. Ocular HSV disease often presents with acute onset of pain, photophobia and decreased vision. Its varying presentation can pose as a diagnostic challenge to the clinician. We describe a case of HSV keratitis with corneal edema, mimicking acute corneal hydrops in a patient who had been using rigid gas permeable contact lenses for previous diagnosis of highly irregular astigmatism.

### Case Report

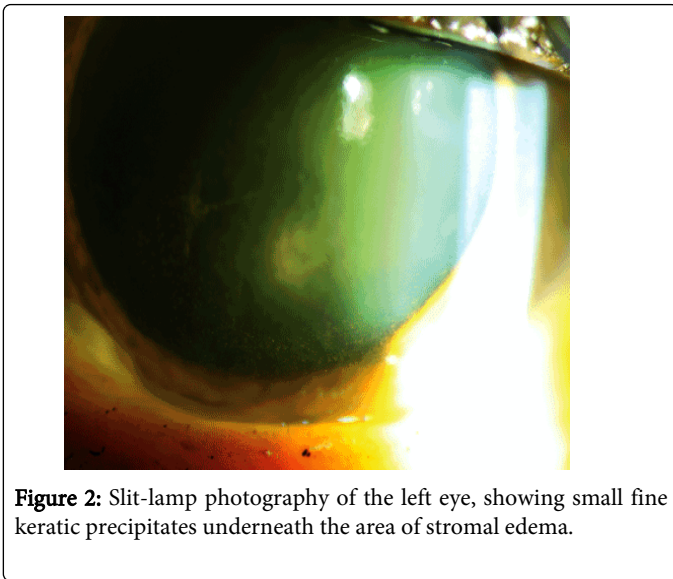
A 57-year-old woman presented with an acute onset of pain, photophobia and decreased vision in her left eye. Prior to the episode, she had been under the care of her optometrist, who had previously diagnosed her with irregular astigmatism. She enjoyed good vision correction with rigid gas permeable contact lenses, prior to presenting with this episode. Her Snellen vision at presentation was 20/20 in the right eye, and 20/300 in the left eye. Intraocular pressures on applanation, were 13mmHg in the right eye, and 18 mmHg in the left eye.

At the slit-lamp biomicroscope, the left eye was found to have marked corneal edema with central endothelial folds, as well as a round, paracentral area of stromal haze and opacity (Figure 1). There was marked anterior chamber inflammation, with a focal area of fibrin

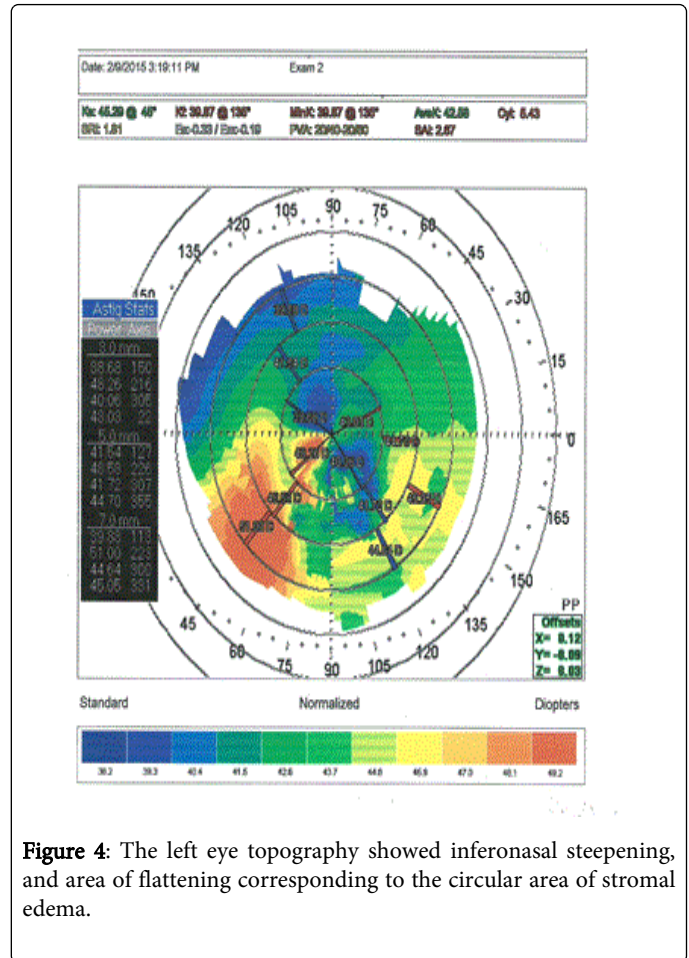
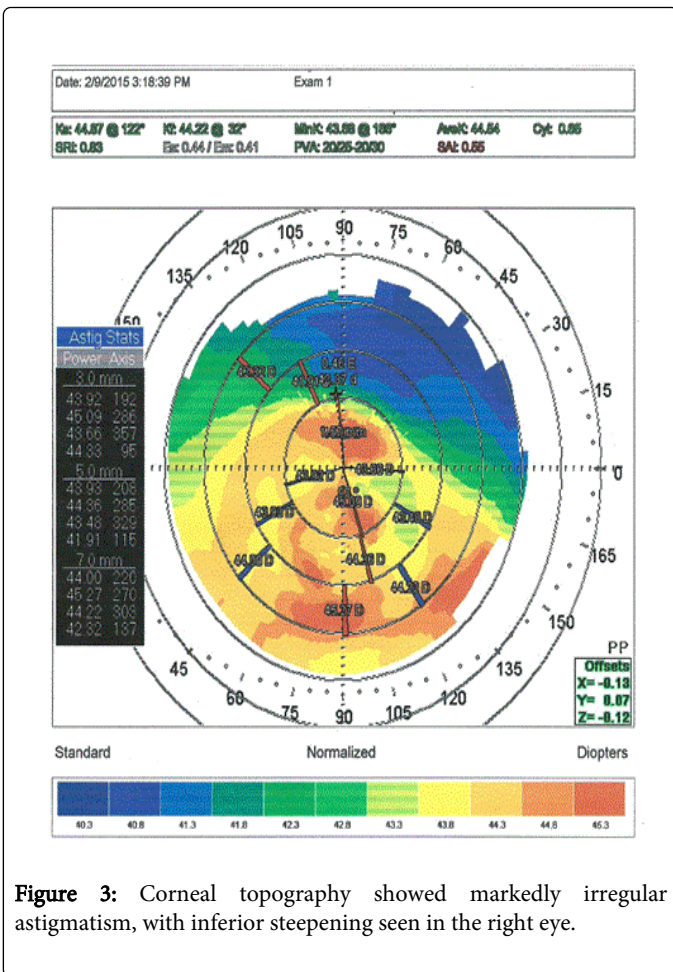
clot inferonasally. Small fine keratic precipitates were also noted underneath the area of stromal edema (Figure 2). The fellow eye was shown to have inferior areas of anterior stromal scarring.



**Figure 1:** Slit-lamp photography of the left eye, showing marked corneal edema with central endothelial folds, as well as a round, paracentral area of stromal haze and opacity.



Corneal topography showed markedly irregular astigmatism, with inferior steepening seen in the right eye (Figure 3). The left eye topography showed inferonasal steepening, and area of flattening corresponding to the circular area of stromal edema (Figure 4).



Given the clinical scenario, a tentative diagnosis of HSV disciform endotheliitis was made, and the patient was started on oral valacyclovir. Three days later, there was complete resolution of the fibrin clot and the anterior chamber reaction, with improvement of the stromal edema. The remarkable response to valacyclovir confirmed the diagnosis of HSV disciform endotheliitis. Topical steroids were initiated and tapered gradually over a 1-month period, at the end of which, patient had complete resolution of edema, inflammation, with an improvement of best-corrected vision to 20/25.

### Discussion

The diagnosis of HSV keratitis is primarily made by clinical examination. At times, the clinician is faced with a diagnostic challenge as HSV keratitis may present in various ways. Previously described, are cases of acanthamoeba keratitis being confused with HSV keratitis [1].

The four main categories of HSV keratitis are infectious epithelial keratitis, neurotrophic keratopathy, stromal keratitis, and endotheliitis [2]. HSV endotheliitis can be further classified as disciform, linear or diffuse. Disciform endotheliitis is the most common presentation of corneal endotheliitis. The most striking finding of disciform endotheliitis on slit-lamp examination is a round area of stromal edema [2]. The edema in disciform corneal endotheliitis is typically focal, with a definite boundary between affected and unaffected area.

There are numerous KPs on the corneal endothelium associated with the corneal edema [3].

Acute corneal hydrops is a complication of keratoconus, which develops when there is a split in the descemet layer and endothelium. This splitting allows aqueous to enter the cornea with gross edema of the stroma and epithelium [4]. It has also been described as a complication of pellucid marginal degeneration, keratoglobus [5,6], as well as post-LASIK ectasia [7]. The ensuing edema leads to marked decline in vision.

In this patient, the clinical presentation posed a diagnostic challenge, as she had a known prior history of irregular astigmatism requiring rigid gas permeable contact lenses in both eyes. The patient's corneal topography showed findings that could be consistent with a keratoconic patient with inferior steepening; corneal hydrops was a possible diagnosis given the above information. However, the slit-lamp findings of inflammation supported the diagnosis of disciform endotheliitis. The rapid resolution of symptoms with oral valacyclovir served to confirm this diagnosis.

The diagnosis of HSV keratitis must be made on a prompt basis, as severe cases can lead to permanent edema, scarring, and neovascularization if left untreated [8].

## References

1. Johns KJ, O'Day DM, Head WS, Neff RJ, Elliott JH (1987) Herpes simplex masquerade syndrome: acanthamoeba keratitis. *Curr Eye Res* 6: 207-212.
2. Holland EJ, Schwartz GS (1999) Classification of herpes simplex virus keratitis. *Cornea* 18: 144-154.
3. Suzuki T, Ohashi Y (2008) Corneal endotheliitis. *Semin Ophthalmol* 23: 235-240.
4. Sharma N, Mannan R, Jhanji V, Agarwal T, Pruthi A, et al. (2011) Ultrasound biomicroscopy-guided assessment of acute corneal hydrops. *Ophthalmology* 118: 2166-2171.
5. Carter JB, Jones DB, Wilhelmus KR (1989) Acute hydrops in pellucid marginal corneal degeneration. *Am J Ophthalmol* 107: 167-170.
6. Sridhar MS, Mahesh S, Bansal AK, Nutheti R, Rao GN (2004) Pellucid marginal corneal degeneration. *Ophthalmology* 111: 1102-1107.
7. Gupta C, Tanaka TS, Elner VM, Soong HK (2015) Acute hydrops with corneal perforation in post-LASIK ectasia. *Cornea* 34: 99-100.
8. Holland EJ, Harilaos SB, Schwartz GS (1997) Herpes Simplex Keratitis. In: Krachmer JH, Mannis MJ, Holland EJ (eds.) *Cornea*. Mosby, Philadelphia, pp. 1058-1059.