

## Hepatoprotective Efficacy of Gold Nanoparticle Synthesized by Green Method Using *Trigonella Foenum-Graecum* Seed Extract

Sourav Ghosh and Antony Gomes\*

Department of Physiology, University of Calcutta, India

\*Corresponding author: Antony Gomes, Department of Physiology, University of Calcutta, India, Tel: +919433139031; Fax: 91-33-2351-9755; E-mail: agomescu@gmail.com

Received date: October 21, 2016; Accepted date: November 21, 2016; Published date: December 04, 2016

Copyright: © 2016 Ghosh S, et al. This is an open-access article distributed under the terms of the Creative Commons Attribution License, which permits unrestricted use, distribution, and reproduction in any medium, provided the original author and source are credited.

### Abstract

Earlier study showed the effective hematopoietic potential of gold nanoparticle (FG-GNP) synthesized using fenugreek seed aqueous extract. The present work was an effort to establish the hepatoprotective activity of FG-GNP in animal model. Swiss albino male mice (n=4) were grouped into: Gr.1- Sham Control, Gr.2- CCl<sub>4</sub> treated (1.5 ml/kg), Gr.3- Standard Drug (Silymarin) treated (100 mg/kg/p.o.), Gr.4- Fenugreek treated (100 mg/kg/p.o.), Gr.5- FG-GNP treated (0.5 mg/kg/p.o.). Biochemical parameters (AST, ALT,  $\gamma$ GT, ACP, ALP, total bilirubin), pro-inflammatory parameters (IL 1 $\beta$ , IL 17, TNF  $\alpha$ ), anti-inflammatory parameters (IL 10, Cathepsin K), antioxidant parameters (GSH, SOD, Catalase) and prooxidant parameter (LPO) were assayed. Histology of liver tissue was done. AST and ALT release from liver tissue was done by *in vitro* liver slice model. Statistical analysis was done by one way ANOVA, values expressed as mean $\pm$ SE, P<0.05 was considered as statistically significant. CCl<sub>4</sub> induction caused significant increased the serum biochemical parameters, pro-inflammatory parameters, prooxidant and decrease in anti-inflammatory parameters and anti-oxidants in animal model and increase in AST, ALT release in *in vitro* model. Treatment with FG-GNP caused significant decrease in biochemical parameters, pro-inflammatory parameters, prooxidant and increase in anti-inflammatory parameters, anti-oxidants in animal model and decrease in AST, ALT release in *in vitro* model when compared to hepatotoxic control animals. FG-GNP partially recovered CCl<sub>4</sub>-induced damages observed in liver histology. The present study showed hepatoprotective potential of FG-GNP which was >FG. Further studies regarding molecular actions of FG-GNP are warranted.

**Keywords:** Fenugreek; *Trigonella foenum-graecum*; Gold nanoparticle; Green synthesis; Hepatotoxicity; Hepatoprotection

### Introduction

With the advancement of civilizations, hepatotoxicity is one of the major causes of large number of deaths per year worldwide.

Hepato-biliary disorders are a threat to the modern society due to changed lifestyle and misuse of drugs. More than 900 drugs, toxins, and herbs have been reported to cause liver injury. Approximately 75% of the idiosyncratic drug reactions result in liver transplantation or death [1]. Many herbs and herbal compounds have been found to be effective against hepatotoxicity. The seeds of fenugreek have hepatoprotective [2-4], anti-inflammatory [5,6] and anti-oxidant activities [7,8].

Gold nanoparticles have anti-inflammatory potential [9,10]. Gold nanoparticle (FG-GNP) synthesized using the reducing property of aqueous extract of the seed of *Trigonella foenum-graecum* (fenugreek, FG) has already been reported to have hematopoietic and antioxidant potential [11].

The present study was an approach to evaluate whether gold nanoparticle tagging with fenugreek seed extract can increase the efficacy of the herb against chemical/drug induced experimental hepatotoxicity.

### Methods

#### *Trigonella foenum graecum* (Fenugreek) seed and synthesis of gold nanoparticle (FG-GNP)

*Trigonella foenum graecum* (Fenugreek) seed was collected from M/s united Chemical and Allied Products, Kolkata, India.

100 gm of finely powdered seed was mixed with 1000 ml of distilled water and was kept at 4–8°C for 24 hours. It was then filtered and the filtrate was collected. The filtrate was centrifuged at 8000 rpm for 1 hour. The dry weight of the supernatant was measured and finally used for the experiments. This aqueous fenugreek seed extract (FS) was kept at 2–8°C for further use. Gold nanoparticle was synthesized from gold salt by using the reducing property of FG as described earlier [11].

#### Animals

Swiss albino male mice (20  $\pm$  2 gm) were obtained from authorized animal suppliers of the University of Calcutta, Kolkata India. The animals were housed in appropriate cages in a well ventilated room with controlled atmosphere (temperature: 25  $\pm$  3°C, humidity: 50  $\pm$  15% and 12:12 hour light: dark cycle). All the animals were provided with standard food and water *ad libitum*. All experimental protocols described in this study were approved by the animal ethical committee (Reference number: IAEC/ Revised Proposal/ AG-01/ 2012; dt: 01.02.2013), University of Calcutta and the animals were maintained as per the guideline of the Committee for the Purpose of Control and Supervision of Experiments on Animal (CPCSEA), Government of India.

## Hepatotoxicity induction and treatment schedule

Animals were taken in 5 groups (n=6): Group 1 (Control group), Group 2 (hepatotoxicity control group, CCl<sub>4</sub> treated), Group 3 (Standard drug Silymarin treated), Group 4 (FG treated) and Group 5 (FG-GNP treated). Animals of group 3, 4 and 5 were treated for 0-10 days with Silymarin (100 mg/kg/po), FG (100 mg/kg/ip) and FG-GNP (100 µl/kg/ip), respectively. On 11th day, CCl<sub>4</sub> was induced (1 ml/kg/po) in animals of group 2, 3, 4 and 5 animals. On 13th day, blood and liver tissues were collected from all animals and biochemical, anti-oxidant, cytokine parameters, histology of liver tissue were done and liver slice model was performed.

## Biochemical parameters

Aspartate transaminase (AST), alanine transaminase (ALT), γ-glutamyl transaminase (γGT), acid phosphatase (ACP), alkaline phosphatase (ALP) and total bilirubin from serum were estimated using biochemical kit (Labkit, India).

**Antioxidant parameters:** Reduced glutathione (expressed as µM/mg protein), superoxide dismutase (IU/mg protein) and lipid peroxidase (MDA/mg protein) were estimated from the serum [12-14]. Serum protein was estimated to express the antioxidants [15]. Heparinised blood was centrifuged for 10 min at 3000 rpm and 1% solution of packed cell volume was used as RBC lysate. From this lysate, catalase (µM/mg hemoglobin) was estimated according to Beers and Sizars [16].

**Cytokine assay:** IL 17, IL 1β, TNF α, IL 10 and cathepsin K were assayed from serum using ELISA kit (R&D, USA) as per instruction of the manufacturer.

**Histology of liver tissue:** Tissues were collected, fixed in 10% buffered formalin for 24 hrs. The tissues were then dehydrated in graded (50-100%) ethanol followed by clearing in Xylene. Paraffin (56-58°C) embedding was done at 58 ± 1°C for 4 hours, followed by paraffin block preparation. Paraffin sections of 5 µ were cut using a rotary microtome. Paraffin sections were deparaffinised with xylene, stained with hematoxylin- eosin, followed by mounting in DPX with a cover slip. Histology of liver tissue was observed with a bright field microscope (Motic, Germany) and photographs were captured with Motic software (Motic Images Plus 2.0 software).

**In vitro liver toxicity:** Mice livers were isolated from adult fasted male Swiss albino male mice and 100 mg of liver was taken in each of the groups (n=4): Group 1 (Sham control), Group 2 (Hepatotoxic control), Group 3 (Silymarin treated), Group 4 (FG treated) and Group 5 (FG-GNP treated). To avoid inter experimental variations due to the circadian rhythm of the mice, isolation of the livers was always performed between 9 and 11 A.M. Slices were prepared from the whole liver and randomly selected for incubation and sampling. As soon as the liver slices were made, they were incubated with phosphate buffered saline with 25 mM D-glucose. Slices were transferred to 5 ml tubes containing 2 ml phosphate buffered saline and oxygen was given (1 bubble/sec). Temperature was maintained at 37 ± 1°C throughout the experiment. At the start of the incubation period, 1 mM acetaminophen was added in the tubes of group 2, 3, 4 and 5 liver slices. At the same time 2.5 µg of Silymarin, FG and FG-GNP were added to tubes of group 3, 4 and 5 liver slices, respectively. All the slices were incubated for 2 hour. After 2 hour the incubated fluid was collected and AST and ALT were measured from the incubated fluid using biochemical kits (Labkit, India).

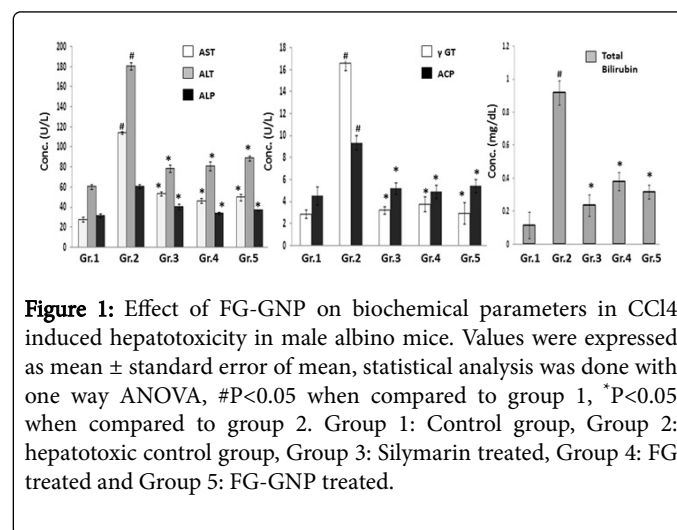
## Statistical Analysis

Statistical significance was evaluated by one way analysis of variance (ANOVA) and P<0.05 was considered statistically significant. Values were expressed as mean ± standard error of mean (n=6).

## Results

### Biochemical parameters

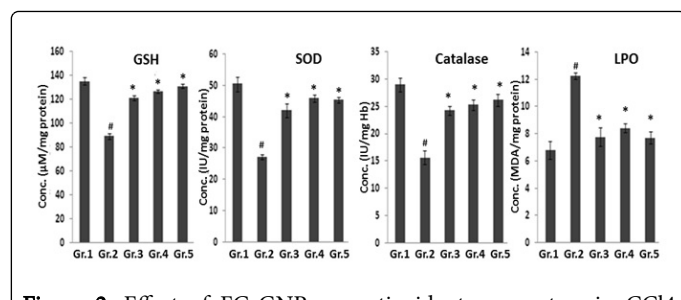
There was significant (P<0.05) increase in AST (86.8%), ALT (82.2%), γGT (49.8%), ACP (86.8%), ALP (82.2%) and total bilirubin (49.8%) in group 2 hepatotoxic control mice when compared to group 1 normal mice, suggesting CCl<sub>4</sub> induced hepatotoxicity in animals. Treatment with FG-GNP in group 5 animals caused significant (P<0.05) decrease in AST (30.5%), ALT (31.2%), γGT (17.4%), ACP (30.5%), ALP (31.2%) and total bilirubin (17.4%) in group 5 animals when compared to group 2 hepatotoxic control animals. FG treatment in group 4 animals caused significant (P<0.05) decrease in AST (36.0%), ALT (26.1%), γGT (27.9%), ACP (36.0%), ALP (26.1%) and total bilirubin (27.9%) in group 4 animals when compared to group 2 hepatotoxic control animals. Treatment with standard drug (Silymarin) in group 3 animals caused significant (P<0.05) decrease in AST (33.6%), ALT (30.3%), γGT (18.2%), ACP (33.6%), ALP (30.3%) and total bilirubin (18.2%) in group 3 animals when compared to group 2 hepatotoxic control animals (Figure 1).



**Figure 1:** Effect of FG-GNP on biochemical parameters in CCl<sub>4</sub> induced hepatotoxicity in male albino mice. Values were expressed as mean ± standard error of mean, statistical analysis was done with one way ANOVA, #P<0.05 when compared to group 1, \*P<0.05 when compared to group 2. Group 1: Control group, Group 2: hepatotoxic control group, Group 3: Silymarin treated, Group 4: FG treated and Group 5: FG-GNP treated.

### Antioxidant parameters

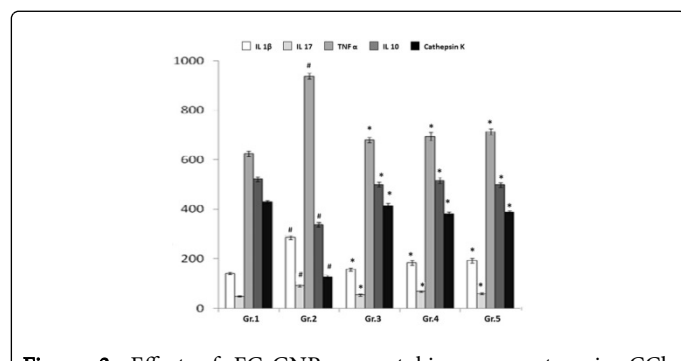
There was significant (P<0.05) decrease in GSH (27.2%), SOD (46.1%), catalase (45.9%) and increase in LPO (80.5%) in group 2 hepatotoxic control mice when compared to group 1 normal mice, suggesting CCl<sub>4</sub> induced oxidative stress in animals. Treatment with FG-GNP in group 5 animals caused significant (P<0.05) increase in GSH (33.1%), SOD (66.5%), catalase (67.2%) and decrease in LPO (37.3%) when compared to group 2 hepatotoxic control animals. FG treatment in group 4 animals caused significant (P<0.05) increase in GSH (28.7%), SOD (68.6%), catalase (61.4%) and decrease in LPO (31.2%) when compared to group 2 hepatotoxic control animals. Treatment with standard drug (Silymarin) in group 3 animals caused significant (P<0.05) increase in GSH (21.9%), SOD (44.2%), catalase (57.8%) and decrease in LPO (31.9%) when compared to group 2 hepatotoxic control animals (Figure 2).



**Figure 2:** Effect of FG-GNP on antioxidant parameters in CCl<sub>4</sub> induced hepatotoxicity in male albino mice. Values were expressed as mean ± standard error of mean, statistical analysis was done with one way ANOVA, #P<0.05 when compared to group 1, \*P<0.05 when compared to group 2. Group 1: Control group, Group 2: hepatotoxic control group, Group 3: Silymarin treated, Group 4: FG treated and Group 5: FG-GNP treated.

### Cytokine parameters

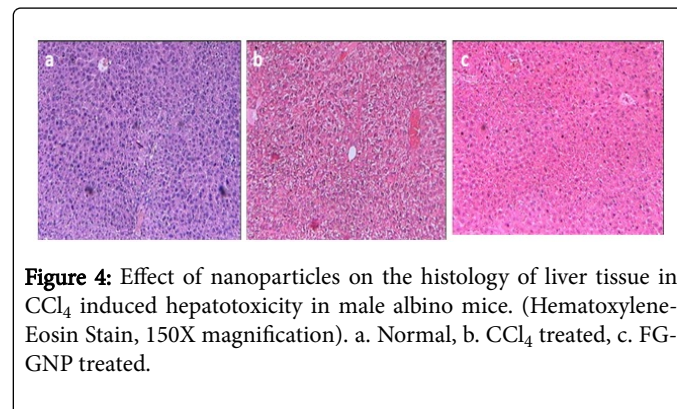
There was significant (P<0.05) increase in IL 17 (83.3%), IL 1β (102.2%), TNF α (50.3%) and decrease in IL 10 (35.2%), cathepsin K (70.4%) in group 2 hepatotoxic control mice when compared to group 1 normal mice, suggesting CCl<sub>4</sub> induced oxidative stress in animals. Treatment with FG-GNP in group 5 animals caused significant (P<0.05) decrease in IL 17 (34.9%), IL 1β (32.7%), TNF α (24.1%) and increase in IL 10 (47.4%), cathepsin K (205.2%) when compared to group 2 hepatotoxic control animals. FG treatment in group 4 animals caused significant (P<0.05) decrease in IL 17 (24.8%), IL 1β (35.4%), TNF α (26.1%) and increase in IL 10 (53.0%), cathepsin K (199.5%) when compared to group 2 hepatotoxic control animals. Treatment with standard drug (Silymarin) in group 3 animals caused significant (P<0.05) decrease in IL 17 (41.8%), IL 1β (47.0%), TNF α (24.1%) and increase in IL 10 (48.2%), cathepsin K (161.1%) when compared to group 2 hepatotoxic control animals (Figure 3).



**Figure 3:** Effect of FG-GNP on cytokine parameters in CCl<sub>4</sub> induced hepatotoxicity in male albino mice. Values were expressed as mean ± standard error of mean, statistical analysis was done with one way ANOVA, #P<0.05 when compared to group 1, \*P<0.05 when compared to group 2. Group 1: Control group, Group 2: hepatotoxic control group, Group 3: Silymarin treated, Group 4: FG treated and Group 5: FG-GNP treated.

### Histology of liver

Histology of liver of group 1 control animals showed normal architecture, intact central canal and prominent hepatocytes. After induction of CCl<sub>4</sub> in group 2 hepatotoxic animals, there was disruption of central canals, centrilobular necrosis, nuclear disintegration, vacuolization and fatty infiltration. Treatment with FG-GNP showed partial recovery of cellular architectures (less necrosis, less vacuolization, intact nucleus and less fatty infiltration as compared with group 2 hepatotoxic control) as shown in Figure 4.



**Figure 4:** Effect of nanoparticles on the histology of liver tissue in CCl<sub>4</sub> induced hepatotoxicity in male albino mice. (Hematoxyline-Eosin Stain, 150X magnification). a. Normal, b. CCl<sub>4</sub> treated, c. FG-GNP treated.

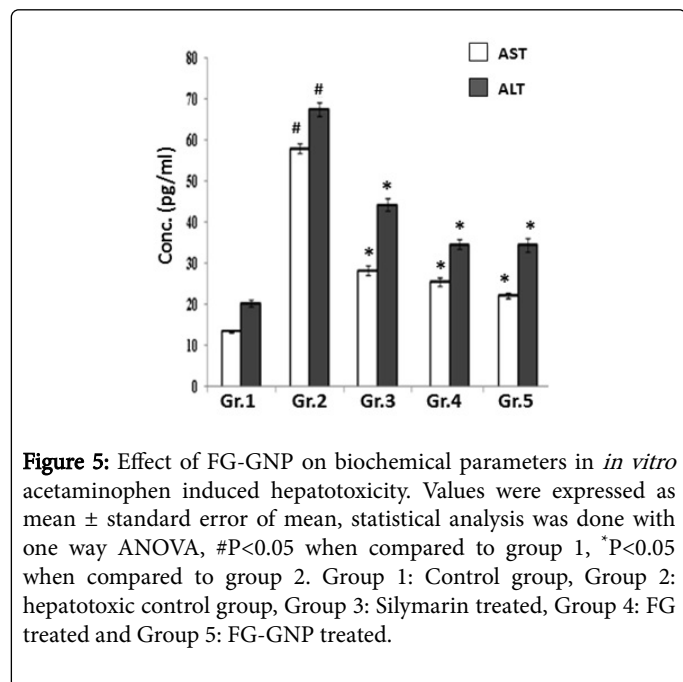
### In vitro liver toxicity

There was significant (P<0.05) increase in AST (86.8%) and ALT (82.2%) release in group 2 hepatotoxic control liver slice when compared to group 1 normal liver slice. Standard drug (iron-sucrose) treatment in group 3 liver slice caused significant (P<0.05) decrease in AST (33.6%) and ALT (30.3%) release when compared to group 2 hepatotoxic liver slice group. FG treatment in group 4 liver slice caused significant (P<0.05) decrease in AST (36.0%) and ALT (26.1%) release when compared to group 2 hepatotoxic control group. FG-GNP treatment in group 5 liver slice caused significant (P<0.05) decrease in AST (30.5%) and ALT (31.2%) release when compared to group 2 hepatotoxic control group (Figure 5).

### Discussion

Hepatotoxicity is one of the major health hazards in the present society and is still one of the major causes of casualties worldwide. There are many limitations of hepatoprotective therapeutics, which lead to the need of development of alternative treatment protocol against. In many traditional systems of medicine, there were mention of herbs and herbal products used in protecting liver function. Medicinal plants along with metals and minerals have been found useful in the treatment and management of pathophysiological conditions [17,18]. Literatures show that processing of medicinal herbs and metallic formulations (including mercury, gold, silver copper, iron, tin lead, zinc etc.) may bring down its size to nanometer range [19,20]. Being so small in size, they are more powerful because the constituent metals and minerals do not react with the tissues of the body [21]. In recent years, metal nanoparticles are being synthesized using the reducing property of herbs with effective therapeutic potential. Green metal nanoparticle produced by using this method is beneficial against anemia, cancer, metastasis, diabetes, drug delivery etc. [22]. The seed of fenugreek has already been reported as hepatoprotective agent [2-4]. In the present study, combination of fenugreek seed extract with gold

nanoparticle was done in order to increase the hepatoprotective efficacy of fenugreek seed extract in animal models.



**Figure 5:** Effect of FG-GNP on biochemical parameters in *in vitro* acetaminophen induced hepatotoxicity. Values were expressed as mean  $\pm$  standard error of mean, statistical analysis was done with one way ANOVA, <sup>#</sup>P<0.05 when compared to group 1, <sup>\*</sup>P<0.05 when compared to group 2. Group 1: Control group, Group 2: hepatotoxic control group, Group 3: Silymarin treated, Group 4: FG treated and Group 5: FG-GNP treated.

Experimental hepatotoxicity can be induced by several agents among which using carbon tetrachloride, acetaminophen, galactosamine, thioacetamide, lead, bromobenzene, alcohol, azathioprine etc. are common [23]. In the present study, carbon tetrachloride was used for convenience (availability, route of application, dose standardization etc.). CCl<sub>4</sub> is activated by cytochrome in the liver, forms trichloromethyl radical (CCl<sub>3</sub>) and causes fatty degeneration, fibrosis, hepatocyte death, and carcinogenicity. CCl<sub>3</sub> radical can bind to cellular molecules (nucleic acid, protein, lipid) and interfere with crucial cellular processes such as lipid metabolism leading to fatty degeneration. This radical can also react with oxygen to form highly reactive oxygen species i.e., trichloromethylperoxy radical (CCl<sub>3</sub>OO<sup>\*</sup>), initiating lipid peroxidation of biological membranes. CCl<sub>4</sub> activates TNF  $\alpha$ , nitric oxide, and transforming growth factors in the cell which direct the cell towards fibrosis [24]. Normally transaminases and other enzymes are present inside the hepatocytes and they do not appear in circulation. CCl<sub>4</sub>-induced hepatotoxicity causes membrane rupture of hepatocytes which in turn causes the enzymes to be leaked out from the cells. As a result, blood transaminase levels increase. Treatment with FG-GNP caused decrease in transaminases, phosphatases and total bilirubin in serum, which indicated the hepatoprotective role of the particle in animal model.

As CCl<sub>4</sub> forms highly reactive oxygen species, it mediates oxidative stress during pathogenesis of hepatotoxicity [25,26]. Very likely, the herbal compounds present in fenugreek (terpenoids, flavonoids, alkaloids etc.) mediated antioxidant effects to inhibit the pathogenesis of hepatotoxicity. Previous studies confirmed the association of proinflammatory and anti-inflammatory cytokines in progression of hepatotoxicity [27,28]. In the present study induction of CCl<sub>4</sub> caused an increase in proinflammatory cytokines (such as IL 17, IL 1 $\beta$  and TNF  $\alpha$ ) and decrease in anti-inflammatory cytokines (IL 10 and cathepsin K), suggesting a proinflammatory environment inside the

liver. Treatment with FG-GNP caused decrease in proinflammatory cytokines and increase in anti-inflammatory cytokines level.

Studies have already established the hepatotoxicity induced by CCl<sub>4</sub> at molecular/cellular level, which could be examined through histological studies of liver [29,30]. CCl<sub>4</sub> causes fatty degeneration, fibrosis, hepatocyte death, and carcinogenicity. In the present study, there was disruption and necrosis of central canal, fatty infiltration, vacuolization and nuclear disintegration after CCl<sub>4</sub> induction. Treatment with FG-GNP caused partial recovery of the cellular structures. There were intact nucleus, less fatty infiltration, less vacuolization and less necrosis of central canal after treatment with FG-GNP.

The herbal compounds present in fenugreek seed (terpenoids, flavonoids and alkaloids) exerted their anti-inflammatory and antioxidant activities, which, in combination with gold nanoparticle helped to ameliorate chemical/drug- induced hepatotoxicity in animal model. It was observed from the present study that hepatoprotective potential of FG-GNP>fenugreek. Very likely, it was due to the combination of gold nanoparticle and fenugreek, which helped targeted delivery of FG-GNP.

## Conclusion

To conclude, FG-GNP exerted its hepatoprotective effects in experimental animals by acting as an anti-inflammatory agent, and its antioxidant property helped to reduce the pathogenesis of chemical/drug-induced hepatotoxicity. Further work may uncover the detailed mechanism of the management of hepatotoxicity by using the herbal-nanoparticle combination.

## Acknowledgement

Center for Research in Nanoscience and Nanotechnology, University of Calcutta, Kolkata, India is acknowledged for providing instrumentation support.

## References

- Ostapowicz G, Fontana RJ, Schiodt FV, Larson A, Davron JT, et al. (2002) Results of a prospective study of acute liver failure at 17 tertiary care centers in the United States. *Ann Intern Med* 137: 947-954.
- Singh P, Kakkar P, Singh RL (2016) Protective effect of trigonella foenum-graecum and foeniculum vulgare mature leaf against t-bhp induced toxicity in primary rat hepatocytes. *J Exp Food Chem* 2: 111-118.
- Wani SA, Kumar P (2016) Fenugreek: A review on its nutraceutical properties and utilization in various food products. *J Saudi Soc of Agri Sci*.
- Aher RR, Belge SA, Kadam SR, Kharade SS, Misal AV, et al. (2016) Therapeutic importance of fenugreek (*Trigonella foenum-graecum* L.): A review. *J Plant Sci Res* 3: 149.
- Pundarikakshudu K, Shah DH, Panchal AH, Bhavsar GC (2016) Anti-inflammatory activity of fenugreek (*Trigonella foenum-graecum* Linn) seed petroleum ether extract. *Indian J Pharmacol* 48: 441-444.
- Abbas N, Naz M, AlSulaim MN (2016) A comparative study of analgesic, antipyretic and anti-inflammatory effect of ethanolic extract of trigonella foenum-graecum with indomethacin and diclofenac sodium. *Br J Pharm Res* 10: 1-8.
- Hussain PR, Suradkar P, Javaid S, Akram H (2016) Influence of postharvest gamma irradiation treatment on the content of bioactive compounds and antioxidant activity of fenugreek (*Trigonella foenum-graecum* L.) and spinach (*Spinacia oleracea* L.) leaves. *Innov Food Sci & Emerg Technol* 33: 268-281.

8. Mukthamba P, Srinivasan K (2016) Hypolipidemic and antioxidant effects of dietary fenugreek (*Trigonella foenum-graecum*) seeds and garlic (*Allium sativum*) in high-fat fed rats. *Food Biosci* 14: 1-9.
9. Yang H, Kozicky L, Saferali A, Fung SY, Afacan N (2016) Endosomal pH modulation by peptide-gold nanoparticle hybrids enables potent anti-inflammatory activity in phagocytic immune cells. *Biomaterials* 111: 90-102.
10. Somasuntharam I, Yehl K, Carroll SL, Maxwell JT, Martinez MD, et al. (2016) Knockdown of TNF- $\alpha$  by DNAzyme gold nanoparticles as an anti-inflammatory therapy for myocardial infarction. *Biomaterials* 83: 12-22.
11. Ghosh S, Sengupta J, Datta P, Gomes A (2014) Hematopoietic and antioxidant activities of gold nanoparticles synthesized by aqueous extract of fenugreek (*Trigonella foenum-graecum*) seed. *Adv Sci Eng Med* 6: 546-552.
12. Ellman GL (1959) Tissue sulfhydryl groups. *Arch Biochem Biophys* 82: 70-77.
13. Pryor WA (1973) Free radical reactions and their importance in biochemical systems. *Fed Proc* 32: 1862-1869.
14. Buege JA, Aust SD (1978) Microsomal lipid peroxidation. *Methods Enzymol* 52: 302-310.
15. Lowry OH, Rosebrough NJ, Farr AL, Randall RJ (1951) Protein measurement with the Folin phenol reagent. *J Biol Chem* 193: 265-275.
16. Beers RF, Sizer IW (1952) A spectrophotometric method for measuring the breakdown of hydrogen peroxide by catalase. *J Biol Chem* 195: 133-140.
17. Madhavacharya (1964) *Sarvadarshanasamgraha*.
18. Virupaksha Gupta KL, Pallavi G, Patgiri BJ, Kodlady N (2011) Relevance of rasa shastra in 21st century with special reference to lifestyle disorders (LSDs). *Int J Res Ayurveda Pharm* 2: 1628-1632.
19. Kulkarni SS (2013) Bhasma and nanomedicine. *Int Res J Pharm* 4: 10-16.
20. Chaudhary A (2011) Ayurvedic bhasma: nanomedicine of ancient India--its global contemporary perspective. *J Biomed Nanotechnol* 7: 68-69.
21. Paul S, Chugh A (2011) Assessing the role of Ayurvedic 'Bhasmas' as Ethnonanomedicine in the metal based nanomedicine patent regime. *J Intellectual Property Rights* 16: 509-515.
22. Gomes A, Ghosh S, Sengupta J, Datta P, Gomes A (2014) Herbonanoceticals: A new step towards herbal therapeutics. *Med Aromat Plants* 3: 3.
23. Singh G, Dhadwal N, Harikumar SL (2015) Experimental models for hepatotoxicity. *Asian J Pharm Clin Res* 8: 70-74.
24. Weber LWD, Boll M, Stampfl A (2003) Hepatotoxicity and mechanism of action of haloalkanes: carbon tetrachloride as a toxicological model. *Crit Rev Toxicol* 33: 105-136.
25. Shaikh ZA, Vu TT, Zaman K (1999) Oxidative stress as a mechanism of chronic cadmium-induced hepatotoxicity and renal toxicity and protection by antioxidants. *Toxicol Appl Pharmacol* 154: 256-263.
26. Reid AB, Kurten RC, McCullough SS, Brock RW, Hinson JA (2005) Mechanisms of acetaminophen-induced hepatotoxicity: role of oxidative stress and mitochondrial permeability transition in freshly isolated mouse hepatocytes. *J Pharmacol Exp Ther* 312: 509-516.
27. Jaeschke H, Williams CD, Ramachandran A, Bajt ML (2012) Acetaminophen hepatotoxicity and repair: the role of sterile inflammation and innate immunity. *Liver Int* 32: 8-20.
28. Luster MI, Simeonova PP, Gallucci RM, Bruccoleri A, Blazka ME, et al. (2001) Role of inflammation in chemical-induced hepatotoxicity. *Toxicol Lett* 120: 317-321.
29. Ikejima K, Honda H, Yoshikawa M, Hirose M, Kitamura T, et al. (2001) Leptin augments inflammatory and profibrogenic responses in the murine liver induced by hepatotoxic chemicals. *Hepatology* 34: 288-297.
30. Maddrey WC (2000) Hepatotoxicity: the adverse effects of drugs and other chemicals on the liver. *Gastroenterology* 118: 984-985.