

Granuloma Annulare in the Setting of Ipilimumab Therapy

Haselden VN^{1*}, Vyas R², Koon H³ and Gerstenblith MR²

¹University of Louisville School of Medicine, Louisville, Kentucky, USA

²Department of Dermatology, University Hospitals Case Medical Center, Case Comprehensive Cancer Center, Case Western Reserve University School of Medicine, Louisville, Kentucky, USA

³Division of Hematology and Oncology, Department of Internal Medicine, University Hospitals Case Medical Center, Case Comprehensive Cancer Center, Case Western Reserve University School of Medicine, Louisville, Kentucky, USA

Received date: November 17, 2014, Accepted date: December 21, 2014, Published date: December 27, 2014

Copyright: © 2015 Haselden VN et al. This is an open-access article distributed under the terms of the Creative Commons Attribution License, which permits unrestricted use, distribution, and reproduction in any medium, provided the original author and source are credited.

*Corresponding author: Virginia N. Haselden, University of Louisville School of Medicine, 323 East Chestnut Street, Louisville, KY 40202, USA, Tel: (502) 852-5192; Fax: (502) 852-5871; E-mail: vnhase01@louisville.edu

Summary:

We present a patient who developed granuloma annulare during ipilimumab therapy. Many adverse events of ipilimumab therapy are well documented, such as rash, colitis, hepatotoxicity, and endocrinopathies [1]. Here, we describe a case of granuloma annulare as a side effect of ipilimumab therapy.

Keywords: Melanoma; Granuloma annulare; Immunotherapy; Ipilimumab; CTLA-4

Case Report:

A 29-year-old Caucasian man presented to an outside clinic with an erythematous, exophytic, eroded tumor on his right heel; a biopsy showed acral lentiginous malignant melanoma, with a Breslow depth of 2.01 mm, ulceration, and one dermal mitosis per square millimeter. He underwent wide local excision with 3 cm margins as well as right popliteal and right inguinal sentinel lymph node biopsies, which revealed one popliteal lymph node and two right inguinal lymph nodes with metastatic melanoma. Subsequently, a completion lymph node dissection was performed, which was negative. He was enrolled in a clinical trial for his stage IIIB melanoma evaluating adjuvant interferon vs. ipilimumab and was randomized to the low-dose ipilimumab arm. He received an induction dose of 3 mg/kg every three weeks for a total of four doses, followed by maintenance dosing of 3 mg/kg every twelve weeks for a total of four doses.

At a cumulative dose of 9 mg/kg after six weeks of treatment with ipilimumab, he noted a new, asymptomatic red lesion on his elbow. Examination showed an 8mm × 7mm annular erythematous plaque on the right extensor elbow. A biopsy was performed, and histopathology revealed a palisaded infiltrate of histiocytes with a moderate superficial and mid-dermal perivascular lymphocytic infiltrate, consistent with granuloma annulare (GA) (Figure 1). Since he was asymptomatic, he declined treatment and decided to continue with the ipilimumab therapy, which he completed after one year. Two months after the appearance of the elbow lesion, he was noted to have additional annular erythematous plaques on his right elbow and right hand, after which there was further progression to the bilateral dorsal hands, bilateral dorsal feet, and right anterior lower leg. Ten months after completing therapy, only one remaining plaque was noted on the left dorsal foot.

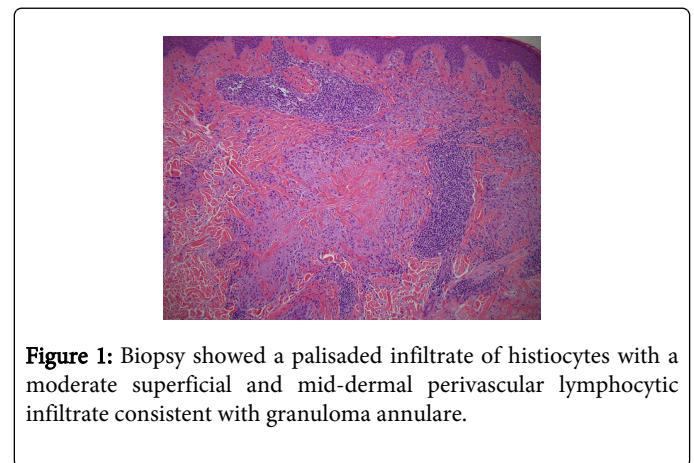


Figure 1: Biopsy showed a palisaded infiltrate of histiocytes with a moderate superficial and mid-dermal perivascular lymphocytic infiltrate consistent with granuloma annulare.

Discussion:

Ipilimumab is an FDA-approved immunomodulatory checkpoint inhibitor, which can increase survival in patients with metastatic melanoma [2]. Its use as an adjuvant treatment in the setting of stage II and III melanoma is still under investigation. Ipilimumab is a monoclonal antibody that blocks cytotoxic T-lymphocyte antigen-4 (CTLA-4) and increases the immune response against melanoma by decreasing the inhibitory effect of CTLA-4 on effector T-cells and/or reducing regulatory T-cells [3]. Recent studies suggest ipilimumab's effects may be due to increased T-cell motility [3].

The adverse events associated with ipilimumab therapy are usually attributed to its immunological mechanism of action, called immune-related adverse events (irAEs) [4,5]. The ipilimumab risk evaluation and management guide states that all signs and symptoms of enterocolitis, hepatitis, neuropathy, endocrinopathy, and dermatitis occurring during ipilimumab therapy should be considered immune-related, unless there is an identifiable alternative etiology [6]. Immune-related adverse events have been reported to affect 50-60% of patients, with colitis and dermatitis being the most common, though less than 20% of patients experience severe reactions, grade 3 or 4 [5,7]. In a recent retrospective cohort study of 198 patients receiving ipilimumab, the presence of irAEs correlated with the probability of response to therapy and prolonged survival; however, larger studies have not confirmed these findings [4].

Dermatologic adverse events are typically the first to manifest, after an average of 3-4 weeks [5,7]. In a recent safety analysis from a phase 3 trial of ipilimumab in advanced melanoma, gastrointestinal irAEs were

observed 8 weeks after beginning treatment, and endocrine at a median of 7-20 weeks [7]. Skin and endocrine disorders were the most likely to persist. The most common dermatologic adverse event observed during ipilimumab therapy is a morbilliform rash, though pruritus, alopecia, and vitiligo may also occur [5,8]. Stevens-Johnson syndrome/toxic epidermal necrolysis and rare irAEs, such as cutaneous sarcoidosis with systemic manifestations, have been reported [5,9].

GA is a clinicopathologic entity with a largely unknown etiology. The histology of this disorder, showing palisading granulomas, mucin deposition, lymphohistiocytic infiltrate, and degenerated collagen, suggests that it may represent a delayed-type hypersensitivity reaction [10]. Generalized GA has been associated with autoimmune diseases such as diabetes mellitus, thyroid disease, and rheumatoid arthritis [11]. Our patient had no prior history of diabetes or other autoimmune diseases. In a reported case of GA developing in the setting of anti-TNF therapy, activated auto-reactive T cells were hypothesized to have induced GA [12]. Activated auto-reactive T cells could be the mechanism of GA induction in our patient as well. Though there are few studies on treatment of GA, the localized form is most commonly treated with topical high potency corticosteroids [11]. Treatment is not always necessary, as in our patient, because the disease may be asymptomatic.

Conclusion:

Dermatologic adverse events are associated with ipilimumab therapy, and early recognition and treatment are vital to prevent morbidity and enable adequate therapy. It is important for dermatologists and oncologists to be aware of the possibility of GA as a potential side effect of ipilimumab therapy.

Acknowledgements:

The authors thank Dr. Kord Honda for assistance with the Figure.
Author Contributions:

Virginia Haselden and Drs. Vyas and Gerstenblith had full access to all of the data in the study and take responsibility for the integrity of the data and the accuracy of the data analysis.

Study concept and design: Gerstenblith

Acquisition of data: Vyas, Gerstenblith, Koon

Analysis and interpretation of data: Haselden, Vyas, Gerstenblith

Drafting of the manuscript: Haselden, Vyas, Gerstenblith

Critical revision of the manuscript for important intellectual content: Haselden, Vyas, Gerstenblith

Study supervision: Gerstenblith

Financial Disclosure:

RV and VNH have no disclosures. MRG has received grants from The Char and Chuck Fowler Family Foundation and the Dermatology Foundation Career Development Award in Medical Dermatology.

References:

1. Mavropoulos JC, Wang TS (2014) Managing the skin toxicities from new melanoma drugs. *Curr Treat Options Oncol* 15: 281-301.
2. Hodi FS, O'Day SJ, McDermott DF, Weber RW, Sosman JA, et al. (2010) Improved survival with ipilimumab in patients with metastatic melanoma. *N Engl J Med* 363: 711-723.
3. Pentcheva-Hoang T, Simpson TR, Montalvo-Ortiz W, Allison JP (2014) Cytotoxic T lymphocyte antigen-4 blockade enhances antitumor immunity by stimulating melanoma-specific T-cell motility. *Cancer Immunol Res* 2: 970-980.
4. Eigentler TK, Schlaak M, Hassel JC, Loquai C, Stoffels I, et al. (2014) Effectiveness and tolerability of ipilimumab: experiences from 198 patients included in a named-patient program in various daily-practice settings and multiple institutions. *J Immunotherapy* 37: 374-381.
5. Lacouture ME, Wolchok JD, Yosipovitch G, Kähler KC, Busam KJ, et al. (2014) Ipilimumab in patients with cancer and the management of dermatologic adverse events. *J Am Acad Dermatol* 71: 161-169.
6. (2011) YERVOY (ipilimumab): Immune-mediated Adverse Reaction Management Guide, Risk Evaluation and Mitigation Strategy (REMS). Bristol-Myers Squibb, USA.
7. Weber JS, Dummer R, de Pril V, Lebbé C, Hodi FS; MDX010-20 Investigators (2013) Patterns of onset and resolution of immune-related adverse events of special interest with ipilimumab: detailed safety analysis from a phase 3 trial in patients with advanced melanoma. *Cancer* 119: 1675-1682.
8. Assi H, Wilson KS (2013) Immune toxicities and long remission duration after ipilimumab therapy for metastatic melanoma: two illustrative cases. *Curr Oncol* 20: 165-169.
9. Tissot C, Carsin A, Freymond N, Pacheco Y, Devouassoux G (2013) Sarcoidosis complicating anti-cytotoxic T-lymphocyte associated antigen-4 monoclonal antibody biotherapy. *European Respiratory Journal* 41: 246-247.
10. Fayyazi A, Schweyer S, Eichmeyer B, Herms J, Hemmerlein B, et al. (2000) Expression of IFN γ , coexpression of TNF α and matrix metalloproteinases and apoptosis of T lymphocytes and macrophages in granuloma annulare. *Arch Dermatol Res* 292: 384-390.
11. Thornsberry LA, English JC 3rd (2013) Etiology, diagnosis, and therapeutic management of granuloma annulare: an update. *Am J Clin Dermatol* 14: 279-290.
12. Exarchou SA, Voulgari PV, Markatseli TE, Zioga A, Drosos AA (2009) Immune-mediated skin lesions in patients treated with anti-tumour necrosis factor alpha inhibitors. *Scand J Rheumatol* 38: 328-331.