

# Glaucoma as a Tax on Hominid Evolution. Constraints of the Experimental Animal Models of Glaucoma

Francisco Javier Carreras\*

Department of Surgery (Ophthalmology), Faculty of Medicine, University of Granada, Avenida de la Investigación nº 11, 18016 Granada, Spain

\*Corresponding author: Francisco Javier Carreras, Department of Surgery (Ophthalmology), Faculty of Medicine, University of Granada, Avenida de la Investigación nº 11, 18016 Granada, Spain, Tel: 34 958 249926; E-mail: [fcarrera@ugr.es](mailto:fcarrera@ugr.es)

Received date: November 02, 2015; Accepted date: February 27, 2016; Published date: February 29, 2016

Copyright: © 2015 Javier Carreras F. This is an open-access article distributed under the terms of the Creative Commons Attribution License, which permits unrestricted use, distribution, and reproduction in any medium, provided the original author and source are credited.

## Abstract

Glaucoma continues to be a mysterious disease. High intraocular pressure (IOP), once the landmark of the disease, has been relegated to the humble role of risk factor, despite the fact that lowering IOP continues to be the only partially successful treatment. Even with an IOP successfully controlled to statistical standards, many patients still mysteriously continue to progressively lose neural tissue. A novel pathogenetical mechanism has recently been put forward as the main agent of the disease. In this new light, some structural details of the human eye, the result of the peculiar evolutionary development, take on an unexpected role in the presentation of the disease. As results of cladistics analysis, the human eye appears as particularly prone to suffering glaucoma as a consequence of the evolutionary path taken. That makes glaucoma essentially a human (and related hominid) scourge. Exclusive features of the human eye compared to other vertebrates involve both the anterior and posterior segment. Those features that facilitate glaucoma in humans are absent in many of the purported animal models for the disease, and this inadequacy further convolutes the mystery of glaucoma. This suggests the division of the animal models into those that mimic the whole disease and those that only reproduce a pertinent histological feature. Unfortunately most animal models are based on high intraocular pressure which excludes most cases of low or moderate pressure. For any animal model, it is important the researcher accurately establishes the constraints of the model in order to avoid jumping to conclusions.

**Keywords:** Glaucoma; Eye evolution; Vertebrates; Invertebrates; Animal models

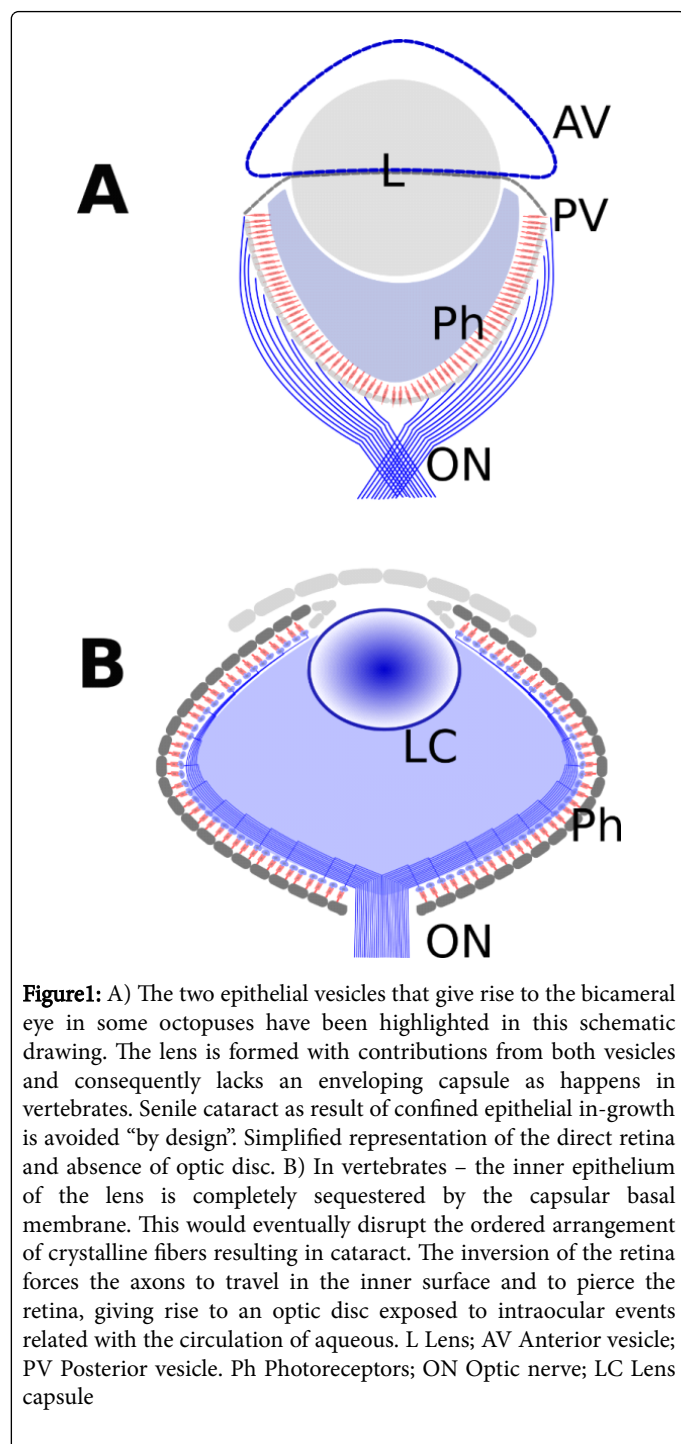
## Introduction

Since the famous and, according to some, dangerous [1] Dobzhansky's dictum, "Nothing in biology makes sense except in the light of evolution" [2], few articles in ophthalmology have been directly related to evolutionary themes. An early exception by L. Bito deals with the evolutionary aspects of ocular hypertension [3]. The frequent use of animal models in ophthalmic diseases, such as glaucoma [4-6] and diabetic retinopathy [7], would warrant close examination of the similitudes between the eyes of different species and, most importantly, of the differences. While it is assumed that similar diseases must affect similar organs, the fact that several million years of evolution separate some of the species in question should be enough to impel a detailed examination of the susceptibility to disease in the eyes of the species used as models. When it concerns a complex disease such as glaucoma, measures must be strengthened. Glaucoma is a complex disease that puzzles researchers [8], but also one that has a dense clinical trial history that cannot be overlooked.

Recently, in the wake of the explosion of genetic studies, the use of simple animals has been advanced as a means to elicit occult the formative patterns that could be at the base of diseases such as glaucoma-this suggestion includes fishes [9]. However, due to the similitude of basic genes such as Pax6, which encodes a transcription factor implicated in the development of eyes. There is interest in Mollusca [10], such interest even extending to urochordates [11].

Just for the sake of clarity, let us give an extreme example of senile cataracts and the octopus eye (Figure 1A). In vertebrates, including humans, senile cataract are a possibility based on the fact that the lens is formed during development as a cyst or bursae, with the epithelium lining the interior surface (Figure 1B). This fact implies that, given enough time, the ever-growing epithelium will compact itself to the point of losing its ordered structure and, consequently, its transparency, among other things. Let us suppose that for undisclosed and, for the sake of our discussion, irrelevant motives, a researcher wants to use an animal model, based on cursory groundwork, and decides to resort to the octopus as an animal model. However, the fact is that while the lens in the bicameral eye of the octopus may resemble the lens in vertebrates, it lacks an enveloping capsule [12]. The basal membrane of the lens in the octopus is situated in the equator of a double lens, and is consequently free of the space constraints of the vertebrate lens. This essential fact supersedes any potential similitude and counsels that the model be discarded.

In order to know whether an animal model is suitable for the study of glaucoma, a detailed comparison of the structures playing a part in the disease must be based on a general hypothesis of the pathogenesis, or at least in the pathology, of glaucoma. The subject of the pathogenesis of glaucoma is still the focus of much debate [13,14], but a great wealth of information has been amassed regarding the isolated pathological mechanisms that take place during the manifestation of the clinical disease. On top of that, the knowledge that is clinically extractable from the diseased subject is both a valuable aid as well as a rigorous constraint.



### Glaucoma: How Many Different Diseases?

The pathogeny of glaucoma is considered multifactorial [15], obscure [16], or unknown [17]. Theories abound. Due to the still unresolved uncertainties in the pathological domain, it is important to highlight that “Glaucoma” is (still) a clinical term and concept. The consequences of this seemingly tautological remark are huge, because it implies that the reference for the contrasting of experimental research is human clinical knowledge. If research or a model does not

comply with the clinical exigencies that characterize the disease, it can be put in doubt and, at least, questioned.

Although it is a well-established clinical fact that very high intraocular pressure (IOP), higher than blood perfusion pressure, is able to induce ischemic damage [18], the presence of glaucomatous changes in patients with moderately increased, normal or even low pressure, without demonstrable pressure spikes, cannot be directly attributed to pressure, and thus additional explanations have been sought [19]. Raised intraocular pressure has been discarded as “the” causative factor and now ranks alongside other risk factors. As the number of known risk factors multiplies, complex mathematical approaches are deemed necessary in order to tackle the tangled relationships between them [16].

Rather than one pathological process, the clinical recognition of Low-pressure Glaucoma has brought about complementary explanations, creating different categories of glaucoma with different pathogenesis. The search for a common element in all types of glaucoma is scattered in a gulag of independent pathogenies. “Independent” research from scientists, ranging from molecular biologists to geneticists, has added a huge amount of still unordered data. Some even leave the eye behind in order to venture into the Central Nervous System in search of an explanation. Currently, glaucoma is seen either as a hereditary degenerative disorder [20], a CNS disease [21] or as an autoimmune process [22], among other labels.

Although dissatisfaction with a single approach based on ocular hypertension has helped promote direct anti-ischemic and neuro-regenerative therapeutic approaches, these have largely been abandoned as sterile, when not outright dangerous [23].

Lowering IOP continues to be the only modifiable risk factor, and the mainstay of glaucoma treatment. But the progression of open angle glaucoma (OAG) in many cases, despite IOP treatment, strongly suggests that other factors must play a part in the development of the disease [24]. Glaucoma is pending a rigorous pathological definition, and some ophthalmologists still miss the days when glaucoma could be explained by a single unifying factor.

If we take chronic open angle glaucoma (COAG) as the reference (standard), a process has to share some of the basic and inexcusable features of COAG in order to be included among the glaucoma.

Those features (morphological and functional) are:

- 1) Damage to the axons in sequential order: basis for the pattern visual field loss.
- 2) Progressive optic atrophy with excavation: based on the loss of astrocytes of the prelaminar region.

As a corollary to 1: Retinal ganglion cells (RGCs) are healthy until they die. Axons die because of a local insult.

As a corollary to 2: Astrocytes disappear first, axons follow, then somas...

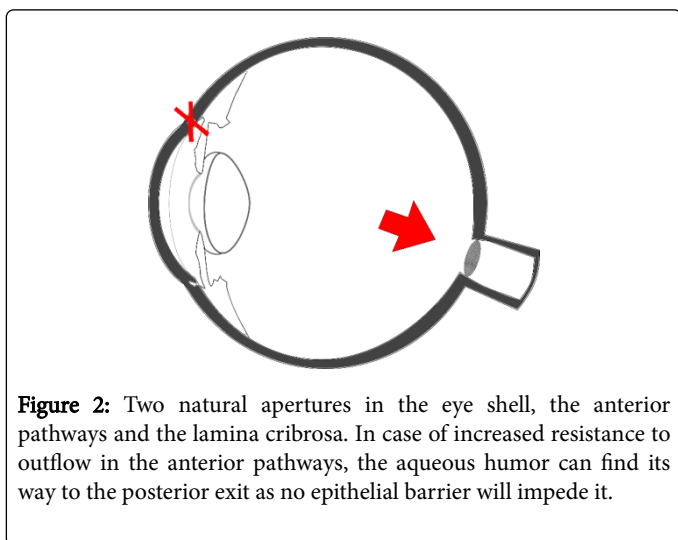
Is glaucoma a single disease with multiple clinical manifestations? Or is there a syndrome with a number of separated pathological paths? Here, we are still looking for an occult common element in all cases of glaucoma, an occult still undefined “quality” that characterizes a case of glaucoma as such.

## Our Proposal?

The misdirection of aqueous outflow is, purportedly, the common occult quality (Figure 2).

## Current Paradigms

There are two aspects to glaucoma that can be treated separately, and which have been aptly summarized in two questions: what causes the neural death?; and why is IOP increased? One refers to damage in the posterior segment and the other to damage in the anterior segment of the eye. Here we will mention only the more conspicuous paradigms currently considered by researchers in relation to the first question, although there are more.



**Figure 2:** Two natural apertures in the eye shell, the anterior pathways and the lamina cribrosa. In case of increased resistance to outflow in the anterior pathways, the aqueous humor can find its way to the posterior exit as no epithelial barrier will impede it.

The first and already classical paradigm is the biomechanical hypothesis [25,26], in which stress forces acting through the lamina cribrosa sclerae are transmitted to axons. Second historically but perhaps the most accepted is the ischemic hypothesis [27], in which the blood perfusion of the neural tissue is compromised. A metabolic hypothesis has its clinical fundament in the clinically attested relationship between steroid hormones and drugs and glaucoma in a segment of the population [28]. Finally, and increasing in acceptance, is the genetic hypothesis [29,30], used in the search for the genes responsible for the disease and which, naturally, encompasses both hypertensive and normotensive cases, and defines glaucoma as a neuro-degenerative disease. We will begin with the last.

## Genetic Paradigm

It is crucial to separate heredity, which is clinical, and genetic, which depends on DNA. Simply because a disease runs in families, a genetic defect in the DNA cannot be concluded, ignoring epigenetics at our own risk. The animal models of glaucoma, based on an implied genetic defect are currently receiving much attention, and are even displacing previous models based on artificially increased IOP [31]. But clinically, "genetic glaucoma" pedigrees are not the norm (less than 5% of cases). Myocilin glaucoma accounts for less than 1.5 % of cases and it courses with high IOP [32]. In that case it could be classified as secondary glaucoma. What this paradigm implies is that occult defects in DNA are responsible for the still unknown 95%. However, while there is clearly the possibility that new case of genetic glaucoma may be unearthed, to attribute the whole of glaucoma to a genetic defect is to

enter into serious contradiction with the clinical concept of the disease as already delineated. In primary OAG cellular loss in the exit pathways is a consequence of an insult to normal cells, as happens with axons in the ONH. But a genetic defect assumes neuro-degenerative diseases with its clinical implications. The main clinical obstacles are the progression of the defect in an orderly manner, and the shape of the scotomas that situate the initial insult in the axon, not in the soma of the RGC. However, perhaps the most difficult justification lies with the disappearance of astrocytes along with the RGCs. Genetic animal models diverge from OAG in those critical aspects. As visual fields are not a reasonable demand on animal models (although this has been attempted), the progressive enlargement of the central excavation with a preserved peripheral neural rim in early stage is a good substitute.

## Ischemic-Mechanic Paradigm

Both the ischemic and mechanic paradigms are respectful of the clinical aspects of glaucoma. It was no accident that they were developed mainly by clinicians, a reason why they were favored in the last century.

**Difficulties with the mechanic model are:** it is exclusively axon-centered; but why do the astrocytes disappear? Axons are wrapped by astrocytes. Why it is those axons that never touch the collagen beams are damaged? And most importantly: how to explain low tension glaucoma?

**Difficulties with the ischemic model are:** astrocytes are more resistant to ischemia than axons. The proof is ischemic optic neuropathy without excavation in which axons have disappeared but the astrocytes remain. An additional problem difficult to interpret at the ultra-structural level is how a process that causes progressive damage over decades, and which projects a consistent diagnostic pattern in the visual fields, is produced by pressure oscillations in a single, not lobulated, capillary bed in an area of 2.5 mm<sup>2</sup>, which is part of a vascular bed with auto regulatory capabilities? (Image) Similarly, how to explain ordered disappearance in a non-lobulated capillary bed? How to explain why, in spite of cellular death taking place, no clinical signs of vascular dysfunction are present, especially in auto regulated (40%) territory? Taking into account that not only axons but also astrocytes disappear, it implies the formation of micro infarcts in a continuous and successive manner, all without evident inflammatory reaction and a total lack of clinically perceptible vascular response.

## Glaucoma and the Brain

The fact some patients continue to lose vision in spite of IOP reduction suggests that something other than pressure in the eye may also help to explain disease progression. Some look to the brain [33] to justify at least a group of patients, splitting the diseases into several groups with different etiologies. Apart from the difficulty of answering some of the questions asked of other models, clinically neuroprotection at the eye level has been deemed useless and even dangerous [23]. However, protection of the CNS neurons has recently been proposed as an adjunct therapy with less inherent risks [17].

## A New Member of the Metabolic Paradigm?

The metabolic paradigm is based in the glaucoma-inducing effect of steroidal drugs, both topical and systemic. It has given rise to much research, but related mainly to the hypertensive side effect [28,34], and not to a possible effect on the ONH. Nevertheless, it can be used as the

head of a group within which the hypothesis of the misdirection of aqueous humor towards the posterior pole could be included.

There is also a possible effect of steroids, among many others, on junction complex in the ONH [35]. In brief, this hypothesis blames not the raised intraocular pressure but rather the misdirection of the flow of aqueous towards the posterior pole of the eye as the main culprit in glaucoma, causing first loss of astrocytes by anoikis, and, secondarily, axonal destruction with a subsequent apoptosis in the retinal ganglion cell [36]. The prelaminar region of the optic nerve holds a capillary net surrounded by astrocytes feet, and axons of retinal ganglion cells wrapped by astrocytic expansions. Glucose transporters help carry glucose from the capillary lumen into the astrocyte [37]. A part is consumed, another part is transported to the axons through glucose transporters, and a further main part is transformed into lactate. Lactate is then transported into the axons through monocarboxylate transporters (MCT) [38]. Gap junctions, also present in the prelaminar tissue [39], allow astrocytes to share glucose and lactate. Critical to the maintenance of correct cellular relationships is the presence of adherens junctions rich in N-Cadherine, a calcium-dependent adhesion molecule. If aqueous humor, poor in  $Ca^{++}$  relative to plasma, displaces extracellular fluids, the adherens junctions separate and trigger a form of apoptosis known as anoikis. The consequence is initially axonal compartmentalized destruction and, secondarily, retinal ganglion cell apoptosis, the landmark of glaucoma.

Misdirection of aqueous humor may take place in the presence of normal or elevated intraocular pressure, the common feature of glaucoma being the flow of aqueous through the optic nerve head. This may take place irrespective of the cause of elevated resistance to the outflow of aqueous [40,41]. Glaucoma can be complicated by ischemic processes if the IOP rises to levels incompatible with blood perfusion. But this is a secondary element independent of proper glaucomatous damage, although more directly related to the circulation of aqueous humor than any other risk factor. This close relationship has acted as a screen preventing the occult effect of the misdirection of aqueous from being spotted.

We will compare current paradigms with the misdirection of aqueous hypothesis in different species used as animal models, highlighting the eye structure more pertinent to each glaucoma paradigm

### **A Short Walk down The Path of the Species (Cladistic Analysis)**

We can consider, via a cladistic analysis, how glaucoma is an improbable outcome in types of eyes different from hominid eyes. It would make sense that the more removed from our position in the evolutionary tree, the more unlikely it is that glaucoma will occur.

Some glaucoma paradigms are not exclusive of others. For example, ischemia may play a role in any paradigm provided a sufficient rise in IOP occurs, while in the much-debated low pressure glaucoma, ischemia or shear stress is not easily justifiable. If an animal model is used to provoke the disease, then depending on the characteristics of the eye, some paradigms will fit more properly than others. Vertebrate eyes differ widely in some features that can condition the results of the model from the beginning.

Several areas of the eye are most important in glaucoma, both in the anterior and posterior segment. We will review some of them in the animal models and elicit the differences of the ocular features between

the species: Exit pathways; Ciliary body; and vascular structures in relation to Vitreous body, Optic nerve head and Retina. As a result of the mechanism of damage, different tissular elements must be highlighted as essential in order for glaucoma pathological mechanisms to be feasible:

### **The Great Divide: The inversion of the retina**

The majority of invertebrates have a direct retina [42], but all vertebrates have an inverted retina [43]. In inverted retina the axons of the ganglion cells are situated in the internal layer of the retina. In order to abandon the eye, the axons have to bend and pierce the ocular layers, including the retina itself, so as to reach the nuclei of the CNS. The bending of the axons takes place at the optic disc in the contributing to the inner wall of the vitreous cavity. The presence of astrocytes enveloping the axons in the neural rim of the optic disc is a salient feature in many species. An optic disc is absent in invertebrates (Mollusca) as the retinas are direct and neural fibers abandon the eye from the back thereof rather than from the surface of the retina as in vertebrates. Even bicameral eyes that resemble the vertebrate eye, such as the octopus eye, do not possess an optic disc. Optic disc damage is substantial to glaucoma, as we know it, and irrespective of the mechanism, the absence of the disc makes it almost impossible to think of glaucoma.

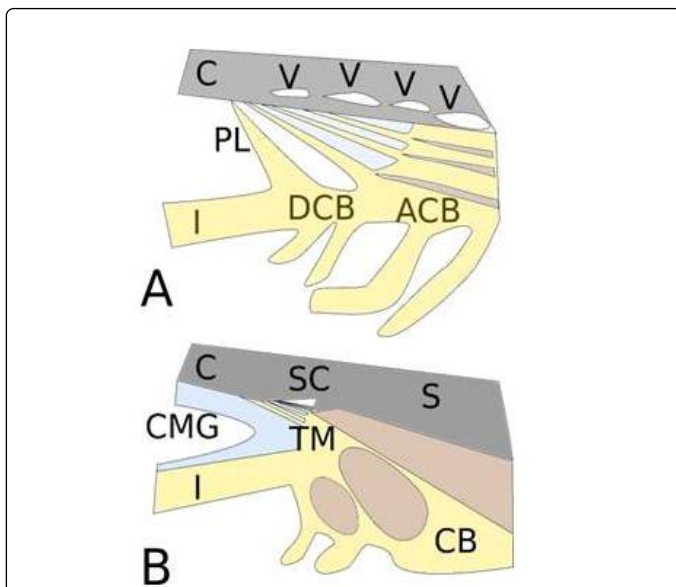
### **Ciliary Body and the Exit Pathways**

In hominids, the great development of the mass of the ciliary muscle for the gaining of accommodation, concurrent with high central visual acuity, obliterates all the posterior vessels, sparing only the anterior one, which becomes the Schlemm's canal [44]. Passive funnel distension is reduced and partially substituted by ciliary muscle contraction and relaxation, which ceases with presbyopia (Figure 3).

Classically, an increase in the difficulty of the evacuation of the aqueous humor is at the base of IOP increment. This is related to the special structure of the aqueous outflow pathways in humans as a result of the acquisition of accommodation capabilities.

This difference in the number of evacuation vessels helps to explain a tendency towards an increase in resistance to outflow in humans, as well as why is it so difficult to have a sustained elevated IOP in most mammals.

An angular vascular plexus is the norm in big mammals with lax extra-cellular material controlled by connective cells, although in mice and rats it is so small as to contain only a vessel and very scarce angular tissue. In humans the vascular plexus is reduced to the anteriorly situated Schlemm's canal. The reduction of the detached ciliary body in humans displaces the GAGs towards the anterior chamber. Coloidosmotic glycosaminoglycans (GAGs) give rise to the Cameral Mucous Gel (CMG) [45,46]. The CMG is more difficult to control because in its new position it is not made available to ciliary body connective and endothelial cells. While the passage through the ciliary tissue in mammals contains variable amounts of extracellular material (ECM) and GAGs, cellular elements of the connective tissue have enhanced destruction capabilities for ECM. In humans the CMG is displaced to the anterior chamber, outside the control of the connective cells. CMG is difficult to control in humans compared to other mammals. Colloidosmotic properties of CMG depend essentially on the secreting ciliary epithelium.



**Figure 3:** Enhanced central vision coincides with newly acquired accommodation capabilities. Engrossment of the ciliary muscle impedes the access of aqueous to the posterior angular plexus and modifies the chamber structures in a way that partially relates facility of outflow with ciliary muscle activity. This dependency may impact outflow in the age of presbyopia. **A** Chamber angle in low mammals with detached and attached portions. A variable number of vessels in the angular plexus evacuates the aqueous humor, after permeating a portion of connective tissue with cells and colloid osmotic GAGs in the extracellular material. **B** Chamber angle in hominids with uveo-scleral and corneo-scleral meshwork, but not detached ciliary body. The angular plexus has been substituted by a single anterior vessel. The ciliary muscle pulls the scleral spur to open the meshwork, a function that diminishes with age. Colloid osmotic GAGs form the cameral mucous gel (CMG) and are left to the uveo-scleral meshwork, with no remaining of the angular connective tissue. C Cornea; V Vessel from the angular plexus, PL Pectinate ligament; I Iris; DCB Detached ciliary body; ACB Attached ciliary body; SC Schlemm's Canal; S Sclera; CMG Cameral mucous gel; TM Trabecular meshwork; CB Ciliary body (and ciliary muscle).

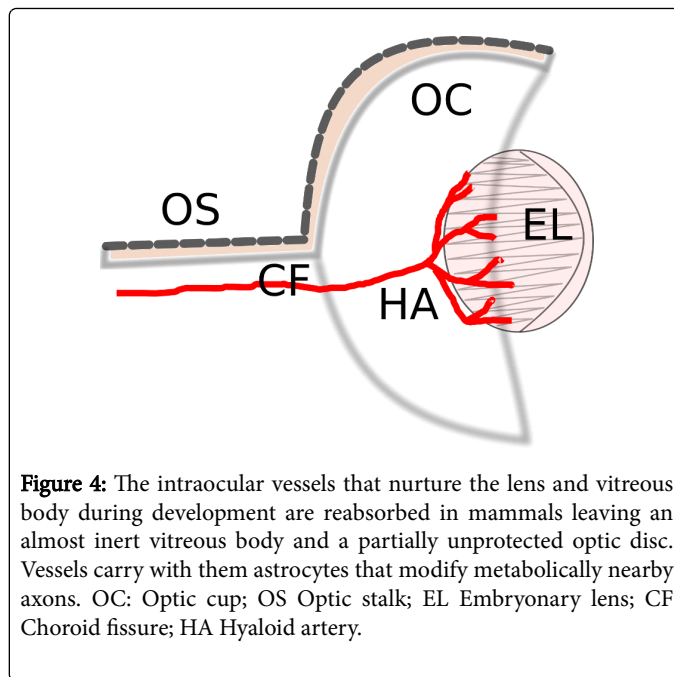
As a self-fulfilling prophecy, an almost complete destruction of the anterior exit pathways is needed in experimental models with low mammals before a clear increase in IOP is reached. The model is not considered successful until ischemic damage is present, thus closing the circle.

### The Reabsorption of the Hyaloid Artery and the Optic Cup

The optic cup and the reabsorption of the hyaloid artery are features of mammals not present in other classes [45] (Figure 4). Due to the different conformation of the papilla among different classes, susceptibility to POAG should vary accordingly. Teleostean, reptiles and birds do not experience reabsorption of the equivalent of the hyaloid vessels, and the papillae show vascular formations (falciform process, conus, pecten). These structures would reinforce the

supportive tissue at the bending of the axons. In mammals the hyaloid system is always reabsorbed, and conjointly with the optic cup, the risk of POAG appears.

In addition to receiving nourishment from the choroidal vascular bed, in some nonmammalian vertebrates the retina may also be supplemented by a range of extra retinal or intra vitreal vascular structures, such as the hyaloid system in amphibians, the pecten in birds or the conus in reptiles. In noneutherian mammals (monotremes and marsupials) both vascular (holangiogenic or euangiogenic), partially vascularized (merangiogenic and paurangiogenic) and avascular (angiogenic) retinas are observed. All eyes with pecten or similar imply a well-preserved vitreous body and resistance to ischemia.



**Figure 4:** The intraocular vessels that nurture the lens and vitreous body during development are reabsorbed in mammals leaving an almost inert vitreous body and a partially unprotected optic disc. Vessels carry with them astrocytes that modify metabolically nearby axons. OC: Optic cup; OS Optic stalk; EL Embryonic lens; CF Choroid fissure; HA Hyaloid artery.

### The Optic Nerve

As the site of neural damage in glaucoma, the structure of the optic nerve head is of outstanding interest. In the mechanic model the strength of the lamina cribrosa is a must. In the ischemic hypothesis the culprit is a deficit in the circulation in a capillary network. Both mechanisms may combine in opposing intra-axonal flow [46]. In the misdirection hypothesis the permeability of the anterior surface of the disc is the feature to be characterized [40,41].

Reptiles and avians are an unsuitable model for the misdirection paradigm due to the capillary plexus on the surface (conus). On the contrary, in mammals the salient feature is the absence of an impermeable barrier (epithelia) between the vitreous body and the optic nerve head. Of similar importance is the spreading of the retinal trunks (arterial and venous) on the surface of the ONH, contributing with their glial sheath to the Elschnig's astrocytic limitant. Equally consequential is the perivascular glial sheath, and its spaces, with a limited lymphatic-like function. A computer modeling of the anterior optic pathways has elaborated on the feasibility of the protective role of the vessels through their effects on the visual field defects [47,48].

The presence of structured union complexes in the axon-wrapping astrocytes of the prelaminar region implies a signaling mechanism of

mesenchymal epithelial transition, a two-way process together with a correlation with metabolic coupled molecules, as mentioned earlier.

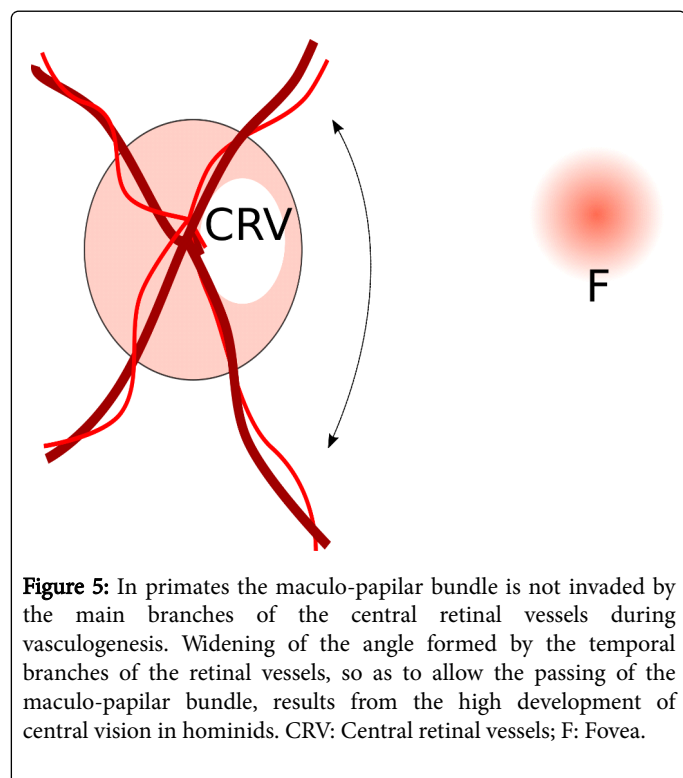
A salient case is the rabbit. In rabbits there is a steady flow of aqueous humor through the optic nerve head. Does it contradict our hypothesis of a distressing aqueous humor? Quite the contrary as the axons at the ONH in the rabbit are myelinated, covered by oligodendrocytes, rather than astrocytes, and so protected from the deleterious effects of the calcium-starved aqueous humor.

## The Vitreous Body

The vitreous body is probably the most neglected ocular structure [49]. The presence of the conus-pecten has been related to vitreous preservation. In mammals this role is no longer possible and no substitute structure is evident. While mention of the vitreous is absent in any other hypothesis, vitreous permeability is a necessity for the misdirection hypothesis.

## The macula of the primates

A central fringe of increased cellularity (area centralis) accompanied by an increment in visual acuity is a tendency among higher mammals and birds. In many species with low central visual acuity, the distribution of the branches of the central vessels of the ONH follow a radial pattern [50,51].



**Figure 5:** In primates the maculo-papillary bundle is not invaded by the main branches of the central retinal vessels during vasculogenesis. Widening of the angle formed by the temporal branches of the retinal vessels, so as to allow the passing of the maculo-papillary bundle, results from the high development of central vision in hominids. CRV: Central retinal vessels; F: Fovea.

In primates, the formation of the macula, with its massive maculo-papillary bundle, coincides with a widening of the angle that separates the temporal branches of the central retinal vessels (Figure 5). The development of the central vision is responsible for the displacement of the temporal vessels by the papilo-macular bundle. This renders the temporal half of the papilla devoid of robust vessels. Give that vessels play a protective role against aqueous perfusion, the temporal papilla weakens and the susceptibility to POAG increases. Attainment of a

good central acuity coincides with accommodation increasing the susceptibility to glaucoma, in humans.

To sum up this section, there are five milestones in the evolution of the human eye that connect the human eye to glaucoma:

- Inverted retina: an inner ONH exposes to intraocular fluids.
- Total reabsorption of the hyaloid artery: Absence of conus/pecten, central cup of the disc and meniscus of Kuhnt. Limited life-span of the vitreous body.
- Vascular vs. avascular retina. Vascular retina with massive presence of astrocytes in the ONH in higher mammals.
- Central vision (Macular development) and two important consequences: Accommodation and ciliary muscle increase with modification of the exit pathways.
- And displacement of the vascular arcades exposing the temporal neural rim.

## A Reference to Selection Pressure

From the perspective advocated herein, it appears as if the evolutionary path that led to hominization of the eye has progressively increased the chances of suffering glaucoma.

We must consider that evolutionary features are the result of the balance of one or several trade-offs. A trade-off exists when a change in a trait that increases reproductive success causes changes in another trait that decreases reproductive success. There are some well-known trade-offs, for instance, the price the fruit fly pays for improved reproduction is a decreased chance of survival, and for birds increased reproduction is linked to increased susceptibility to pathogens. We can also think of auto-immune diseases as the price paid for protection against pathogens [52]. In the visual pathways and the outflow pathways, as in any other organismal design, a number of trade-offs are involved. Excessive tissue in the chamber angle structures may be responsible for congenital glaucoma, and insufficient cellularity could be responsible for adult POAG. Obviously, while the first situation may impede the transmission of genes, the second does not.

We can apply the same type of analysis to any other trait in the structures incumbent to glaucoma. The optic cup is the result of the reabsorption of the hyaloid artery. Features that favour glaucoma are optic disc size and excavation. The bigger the disc, the smaller the area protected by the vessels. If increased reabsorption favours POAG, no barrier to the transmission of the trait would be found provided the subjects are able to reach reproductive age. Vitreous permeability is also directly related.

Given that in principle all the genetically and epigenetically transmitted traits of the structures related to glaucoma-cellularity at the chamber angle, and features of the ONH-- can combine randomly, so will susceptibility to POAG. POAG is the result of a combination of genes that make the ONH stable and functional up to reproductive age, but which can fail thereafter. We have seen how the path followed in the evolution of mammals had some critical moments such as the inverted retina, reabsorption of the hyaloid artery, and so on. From this perspective POAG appears to be the result of numerous trade-offs, the majority of which remain obscure to us.

In this light, rather than being a degenerative disease [53], POAG appears to be a valid alternative for the survival of the species. The traits transmitted to the glaucomatous patient not only allow reproduction but, when combined in a different manner with other

traits, give rise to individuals without POAG. So to speak, POAG is the result of an unfortunate combination of numerous traits that in many other cases combine more harmoniously and preserve the sight of the individual long after reproductive age.

### Would You Dare To Call It Glaucoma?

One of the problems with animal models is that once they have found a place among researchers, they come to replace the real thing. A typical case would be a model of congenital OAG in mice, which is obviously not glaucoma but rather a true neuro-degenerative disease that induces an inflammatory reaction, with participation of microglia and so on. Activated microglia becomes an undetected problem in "glaucoma", while in clinical glaucoma neither inflammation nor activated microglia is a recognized feature.

According to most paradigms, glaucoma is not a degenerative disease. The neural part of the disease is caused by an insult into normal neurons (RGCs). Once the axon is destroyed, the soma enters into apoptosis. Any intent to fight this apoptotic process is useless as the axon will never grow to its correct connections.

All genetic glaucoma is of the hypertensive variety. They are a reality, although marginal. On the other hand, ocular hypertension plays an important role in some glaucomas and must be acknowledged as such, given that it can be an important cause of ischemia. However, this is only a complication of high IOP (more important in acute angle closure glaucoma) and is not the defining feature of glaucoma, which is present in all glaucomas, including the low tension variety. This common element, as defended here, is the misdirection of aqueous through the ONH and the ionic stress it causes.

Although the whole eye may not be suitable as a model, selected animal tissues (even in culture) can nevertheless provide adequate information about isolated processes, common to many diseases, that may be part of the more complex pathological mechanisms, including glaucoma.

### Conclusions

Chronic OAG is not alien to the core structure of the human eye. It is an intrinsic disease, a natural means of self-destruction of the eye. If we were addressing creationists, we would say that glaucoma is the result of a "bad design", meaning "forced adaptation". But other mammals are progressively less prone to suffering the disease, depending on the divergence of the structural and tissular arrangement as compared to humans.

Genetic models, in which RGCs degenerate, irrespective of IOP or aqueous circulation, are not bound to reproduce sequential visual field loss, a landmark for glaucoma, based on orderly fiber loss.

Animal eyes that lack a firm lamina cribrosa, from mouse to rabbit, cannot reproduce damage related to shear stress.

Animals that lack astrocytic wrapping of axons in the ONH are not suitable for studies of the interference with metabolic shuttle.

Animals in which the ONH is separated from the vitreous cavity by capillary plexus (conus, pecten) are not suitable for whole eye models of posterior aqueous deviation.

Any invertebrate eye is unsuitable for modeling the pathophysiology of glaucomatous nerve damage in vertebrates.

High IOP models are prone to reproducing only ischemic damage, and not glaucomatous damage, to the nerve.

### Acknowledgement

This research received funding from the Consejería de Salud of the Junta de Andalucía, Spain.

### References

1. John SE (2002) Dobzhansky's Dangerous Epigram. *BioScience* 52: 614-615.
2. Janus C, Dubnau J (2003) Modeling behavior: the quest to link mechanisms to function. *Genes Brain Behav* 2: 56-61.
3. The American Biology Teacher 35: 125-129.
4. Bito L Z (1992) Glaucoma: A Physiologic Perspective with Darwinian Overtones. *J Glaucoma* 1: 193-205.
5. Johnson TV, Tomarev SI (2010) Rodent models of glaucoma. *Brain Res Bull* 81: 349-358.
6. Urcola JH, Hernández M, Vecino E (2006) Three experimental glaucoma models in rats: comparison of the effects of intraocular pressure elevation on retinal ganglion cell size and death. *Exp Eye Res* 83: 429-437.
7. Bouhenni RA, Dunmire J, Sewell A, Edward DP (2012) Animal models of glaucoma. *J Biomed Biotechnol* 2012: 692609.
8. Timmers AM, Miller CM, Zhu L (2009) Animal Models of Diabetic Retinopathy 46: 113-138.
9. Frezzotti R (2000) The glaucoma mystery from ancient times to the 21st century. The glaucoma mystery: ancient concepts. *Acta Ophthalmol Scand Suppl*: 14-18.
10. Biehlaier O, Neuhauss SC, Kohler K (2001) Onset and time course of apoptosis in the developing zebrafish retina. *Cell Tissue Res* 306: 199-207.
11. Serb JM (2008) Toward developing models to study the disease, ecology, and evolution of the eye. *Mollusca Amer Malac Bull* 26: 3-18.
12. Irvine SQ, Fonseca VC, Zompa MA, Antony R (2008) Cis-regulatory organization of the Pax6 gene in the ascidian *Ciona intestinalis*. *Dev Biol* 317: 649-659.
13. Jagger WS, Sands PJ (1999) A wide-angle gradient index optical model of the crystalline lens and eye of the octopus. *Vis Res* 39: 2841-2852.
14. Rieck J (2013) The pathogenesis of glaucoma in the interplay with the immune system. *Invest Ophthalmol Vis Sci* 54: 2393-2409.
15. Dekeyser E, Aerts J, Valiente-Soriano F, De Groef L, Salinas-Navarro M, et al. (2014) Glaucoma pathology: an eye on the brain. *Acta Ophthalmol* 92: 0.
16. Munemasa Y, Kitaoka Y (2013) Molecular mechanisms of retinal ganglion cell degeneration in glaucoma and future prospects for cell body and axonal protection. *Front Cell Neurosci* 6: 60.
17. Guidoboni G, Harris A, Arciero JC, Siesky BA, Amireskandari A, et al. (2013) Mathematical modeling approaches in the study of glaucoma disparities among people of African and European descents. *J Coupled Syst Multiscale Dyn* 1: 1-21.
18. Nucci C, Osborne NN, Bagetta G, Cerulli L (2008) Glaucoma: an open-window to neurodegeneration and neuroprotection. Preface. *Prog Brain Res* 173: xi.
19. De Moraes CG, Juthani VJ, Liebmann JM, Teng CC, Tello C, et al. (2011) Risk factors for visual field progression in treated glaucoma. *Arch Ophthalmol* 129: 562-568.
20. Gramer E, Grehn F (2012) Pathogenesis and Risk Factors of Glaucoma. Springer Science & Business Media.
21. Fingert JH (2011) Primary open-angle glaucoma genes. *Eye (Lond)* 25: 587-595.
22. Nucci C, Osborne NN, Bagetta G, Cerulli L (2008) Glaucoma: an open-window to neurodegeneration and neuroprotection. Preface. *Prog Brain Res* 173: xi.

23. Bosco A, Steele MR, Vetter ML (2011) Early microglia activation in a mouse model of chronic glaucoma. *J Comp Neurol* 519: 599-620.
24. Caprioli J, Coleman AL; Blood Flow in Glaucoma Discussion (2010) Blood pressure, perfusion pressure, and glaucoma. *Am J Ophthalmol* 149: 704-712.
25. Almasieh M, Wilson AM, Morquette B, Cueva Vargas JL, Di Polo A (2012) The molecular basis of retinal ganglion cell death in glaucoma. *Prog Retin Eye Res* 31: 152-181.
26. Burgoyne CF (2011) A biomechanical paradigm for axonal insult within the optic nerve head in aging and glaucoma. *Exp Eye Res* 93: 120-132.
27. Ross Ethier C, Barocas VH, Crawford Downs J (2008) Ocular Biomechanics in Glaucoma In: Mechanisms of the Glaucomas. Disease Processes and Therapeutic Modalities. Humana Press, New York.
28. Cioffi GA (2001) Three common assumptions about ocular blood flow and glaucoma. *Surv Ophthalmol* 45 Suppl 3: S325-331.
29. Lo WR, Rowlette LL, Caballero M, Yang P, Hernandez MR, Borra's T (2003) Tissue Differential Microarray Analysis of Dexamethasone Induction Reveals Potential Mechanisms of Steroid Glaucoma. *Invest Ophthalmol Vis Sci* 44: 473-485.
30. Rao KN, Nagireddy S, Chakrabarti S (2011) Complex genetic mechanisms in glaucoma: an overview. *Indian J Ophthalmol* 59 Suppl: S31-42.
31. Libby R, Gould DB, Anderson MG, John SW (2005) Complex genetics of glaucoma susceptibility. *Annu Rev Genomics Hum Genet* 6: 15-44.
32. Janssen SF, Gorgels TG, Ramdas WD, Klaver CC, van Duijn CM, et al. (2013) The vast complexity of primary open angle glaucoma: disease genes, risks, molecular mechanisms and pathobiology. *Prog Retin Eye Res* 37: 31-67.
33. Tamm ER (2002) Myocilin and glaucoma: facts and ideas. *Prog Retin Eye Res* 21: 395-428.
34. Sponsel WE, SL, Satsangi N, Maddess T, Reilly MA (2014) Refined Data Analysis Provides Clinical Evidence for Central Nervous System Control of Chronic Glaucomatous Neurodegeneration. *Transl Vis Sci Technol* 3: 1.
35. Lam DS, Fan DS, Ng JS, Yu CB, Wong CY, et al. (2005) Ocular hypertensive and anti-inflammatory responses to different dosages of topical dexamethasone in children: a randomized trial. *Clin Experiment Ophthalmol* 33: 252-258.
36. Lecanda F, Cheng SL, Shin CS, Davidson MK, Warlow P, et al. (2000) Differential regulation of cadherins by dexamethasone in human osteoblastic cells. *J Cell Biochem* 77: 499-506.
37. Carreras FJ (2014) Pathogenesis of glaucoma: how to prevent ganglion cell from axonal destruction? *Neural Regen Res* 9: 2046-2047.
38. Carreras FJ, Aranda CJ, Porcel D, Rodriguez-Hurtado F, Martínez-Agustin O, et al. (2015) Expression of Glucose Transporters in the Prelaminar Region of the Optic-Nerve Head of the Pig as Determined by Immunolabeling and Tissue Culture. *PLoS ONE* 10: e0128516.
39. Carreras FJ, Porcel D, Zarzuelo A, Galisteo M (2011). Expression of Metabolic Coupling and Adhesion Proteins in the Porcine Optic Nerve Head: Relevance to a Flow Model of Glaucoma Glaucoma.
40. Carreras FJ, Porcel D, Alaminos M, Garzón I (2009) Cell-cell adhesion in the prelaminar region of the optic nerve head: a possible target for ionic stress. *Ophthalmic Res* 42: 106-111.
41. Carreras FJ, Porcel D, Muñoz-Avila JI (2010) Mapping the surface astrocytes of the optic disc: a fluid-conducting role of the astrocytic covering of the central vessels. *Clin Experiment Ophthalmol* 38: 300-308.
42. Carreras FJ, Porcel D, Guerra-Tschuschke I, Carreras I (2010) Fenestrations And Preferential Flow Routes In The Prelaminar Optic Nerve Through Wet Scanning Electron Microscope And Perfusion Of Tracers. *Clin Experiment Ophthalmol* 38: 705-717.
43. Cagen R, Reh T (2010) Invertebrate and Vertebrate Eye Development. Academic Press. San Diego, USA.
44. Rodieck RW (1973) The vertebrate retina: Principles of structure and function. Oxford, England.
45. Uribe-Troncoso M (1948) A treatise in Gonioscopy. FA Davis Co. Philadelphia, USA.
46. Elliott JD, Elliott GB (1973) The hyaloid vessel and physiologic optic cup. *Microvasc Res* 6: 93-98.
47. Vidal-Sanz M, Salinas-Navarro M, Nadal-Nicolás FM, Alarcón-Martínez L, Valiente-Soriano FJ, et al. (2012) Understanding glaucomatous damage: anatomical and functional data from ocular hypertensive rodent retinas. *Prog Retin Eye Res* 31: 1-27.
48. Carreras FJ, Medina J, Ruiz-Lozano M, Carreras I, Castro JL. (2014) Virtual Tissue Engineering and Optic Pathways: Plotting the Course of the Axons in the Retinal Nerve Fiber Layer. *Invest Ophthalmol Vis Sci* 55: 3107-3119.
49. Carreras FJ, Rica R, Delgado AV (2011) Modeling the patterns of visual field loss in glaucoma. *Optom Vis Sci* 88: E63-79.
50. Sebag J (2014) Vitreous in Health and Disease. Springer-Verlag New York Inc.
51. Duke-Elder S (1958) System of Ophthalmology. The Eye in Evolution. Henry Kimpton, London.
52. McMenamin PG (2007) The unique paired retinal vascular pattern in marsupials: structural, functional and evolutionary perspectives based on observations in a range of species. *Br J Ophthalmol* 91: 1399-1405.
53. Stearns SC (1999) Introducing evolutionary thinking. Chapter 1 in Evolution in Health and disease. Stephen C Stearns (Eds.) Oxford University Press.
54. Schwartz M, Yoles E (2000) Neuroprotection: a new treatment modality for glaucoma? *Curr Opin Ophthalmol* 11: 107-111.