

# Giant Lipoma Originating from the Right Ventricular Infundibulum - A Case Report

Lucian Florin Dorobantu<sup>1</sup>, Ovidiu Stiru<sup>1</sup>, Catalina Andreea Parasca<sup>1\*</sup>, Vlad Anton Iliescu<sup>1</sup> and Serban Ion Bubenek-Turconi<sup>2</sup>

<sup>1</sup>Department of Cardiovascular Surgery, "CC Iliescu" Emergency Institute for Cardiovascular Diseases, Bucharest, Romania

<sup>2</sup>Department of Intensive Care, "CC Iliescu" Emergency Institute for Cardiovascular Diseases, Bucharest, Romania

\*Corresponding author: Catalina Andreea Parasca, Department of Cardiovascular Surgery, "CC Iliescu" Emergency Institute for Cardiovascular Diseases, Bucharest, Romania, Tel: +40-773-842-692; Fax: + 40-21-317-52-21; E-mail: [catalina.parasca@gmail.com](mailto:catalina.parasca@gmail.com)

Received date: June 7, 2015; Accepted date: June 25, 2015; Published date: June 30, 2015

Copyright: ©2015 Dorobantu FL, et al. This is an open-access article distributed under the terms of the Creative Commons Attribution License, which permits unrestricted use, distribution, and reproduction in any medium, provided the original author and source are credited.

## Abstract

Known as a rare benign cardiac tumor, epicardial lipoma is often an asymptomatic condition discovered due to increasing use of diagnostic imaging techniques. We report a case of a 54-year old patient referred to our institution with mild dyspnea, cough and an enlarged cardiac silhouette on a routine chest X-ray. A large intrapericardial mass suggestive for lipoma encompassing the left and right ventricles was detected by echocardiographic examination and computer tomography scan. Resection of a 650 g mass with right ventricular infundibulum origin was performed via sternotomy, with histopathological confirmation of epicardial lipoma.

**Keywords:** Benign tumour; Epicardial lipoma; Surgery

## Introduction

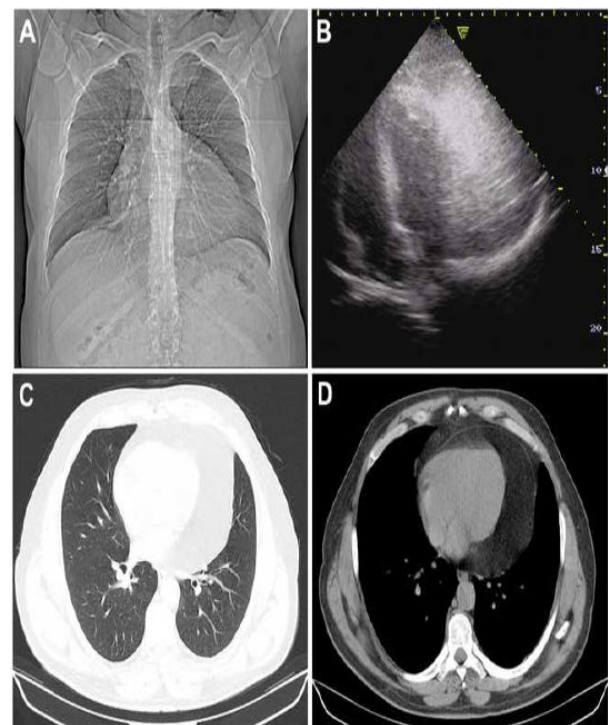
Cardiac lipoma accounts for 10% of the benign tumors of the heart, generally consisting of encapsulated fatty tissue with variable origin and location [1]. Although they can present with symptoms such as fatigue, dyspnea, palpitations, chest pain or discomfort, many of the diagnosed cardiac lipomas are asymptomatic and represent an incidental finding on imaging studies [2]. In rare cases, when the tumoral mass becomes very large in size, electrocardiographic abnormalities, ventricular tachycardia and even sudden death have been described, together with pronounced symptoms of left or right outflow tract obstruction [3].

## Case report

A 54-year-old man with New York Heart Association (NYHA) class III dyspnea and non-productive cough presented in a medium-care hospital. Beside hypertension and obesity class 1, there were no remarkable findings on physical examination. All laboratory testing, including erythrocyte sedimentation rate, serum C-reactive protein concentration and white blood cell count were within normal limits, yet the patient had a history of previously diagnosed and treated dyslipidemia. The electrocardiogram showed normal sinus rhythm with no additional pathological findings. The chest X-ray revealed an enlargement of the cardiac silhouette and bilateral hilar abnormalities, without evidence of pleural effusion (Figure 1a).

As further investigations were required, the patient was referred to our clinic. While standard initial testing was unremarkable, on echocardiographic examination a large intrapericardic mass was described, approximately 11 cm length, 6 cm width and 2 cm thickness, encapsulated, with moderate echogenicity and surrounding the right and left ventricle. Although suggestive for lipomatous tumor, a CT scan was performed to exclude other possible conditions with pericardial involvement. Diagnostic imaging confirmed initial suspicion of intrapericardic lipomatous tumor (Figures 1b and 1c). As

the patient was symptomatic, there was a clear indication for surgical resection of the intrapericardic tumor.

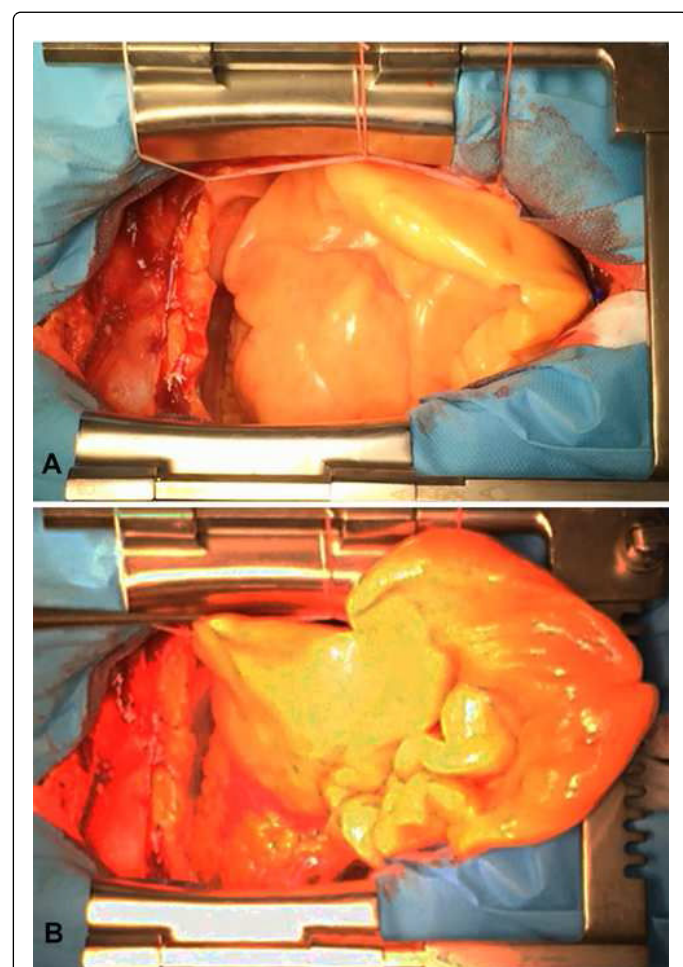


**Figure 1:** Preoperative imaging studies: (A) Chest X-ray showing enlargement of the cardiac silhouette; (B) Echocardiography examination showing a echogenic large intrapericardic mass; (C, D) CT-scan showing intrapericardic mass mimicking pericardial effusion.

Patient underwent surgery via median sternotomy without cardiopulmonary support. Median pericardiotomy revealed an intrapericardial mass enclosing the entire antero-lateral surface of the right and the left ventricles (Figure 2). By cranial displacement of the tumor connection with the infundibular region of the right ventricle was evident (Figure 3). Complete resection was achieved, followed by hemostasis and chest tube placement. Gross evaluation of the tumor described a yellow, lobulated, and homogenous mass, covered by a fine fibrous capsule, suggestive for lipoma (Figure 4a). Histopathologic examination confirmed the nature of the examined specimen as cardiac lipoma (Figure 4b). Uncomplicated evolution allowed hospital discharge on the 6<sup>th</sup> postoperative day.

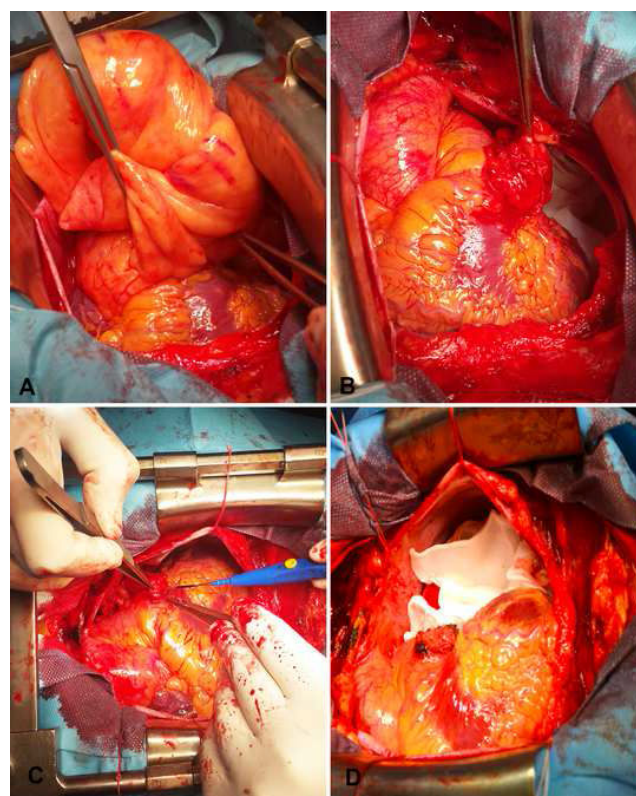
## Discussion

Accounting for approximately 10-19% of cardiac and pericardial tumors, cardiac lipoma is a benign tumor which can cause outflow obstruction, coronary or mediastinal compression manifested as mild dyspnea, chest pain, or discomfort, palpitations, or even sudden cardiac death [4,5]. As with common use of diagnostic imaging, cardiac lipomas are more often an incidental finding in asymptomatic patients [6].



**Figure 2:** Intraoperative aspect: (A) *In-situ* encapsulated lipomatous tumor on the anterior surface of right ventricle. (B) *In-situ* epicardial mass with cranial displacement.

In our case, the NYHA III dyspnea is an uncommon finding, probably due to the big mass and the origin on the infundibulum of the right ventricle. Although a wide range of location have been described, cardiac lipoma originates from the epicardial fat tissue occupying the pericardial sac, usually from the left atrium and left ventricle [7]. The origin on the right ventricular infundibulum is very rare, to our knowledge this being the first case described so far. Occasionally it can present as an intramyocardic mass displacing myocardial fibers, causing electrical abnormalities and arrhythmias. Typically with a slow grow rate, large tumors surrounding and compressing the heart chambers may lead to hemodynamic alteration mimicking subacute or chronic pericardial effusion [2]. At this point a thorough differential diagnosis should be considered; including malignancy, metabolic abnormalities, infectious diseases, systemic inflammatory or autoimmune diseases, and imaging techniques are the best next diagnostic step.

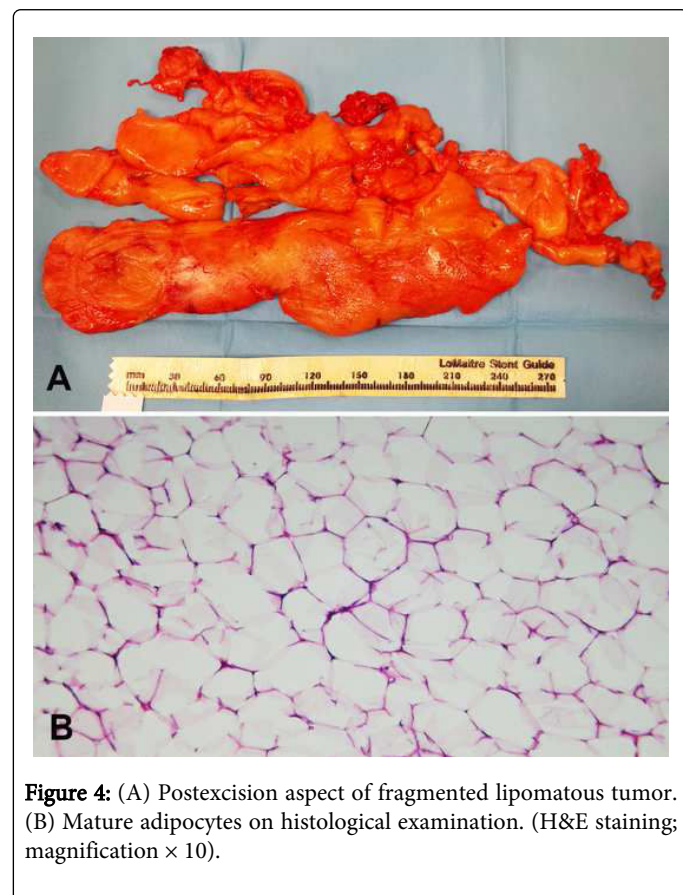


**Figure 3:** Intra-operative aspects: (A) Displacement of epicardial tumor revealing right ventricle infundibulum origin; (B-D) Right ventricle infundibulum aspect during and after resection of epicardial lipoma.

Echocardiography usually describes a homogenous echogenic mass, playing an important role in establishing the presumptive diagnosis of cardiac lipoma. For accurate diagnosis CT scan can be helpful in differentiating low radiodensity lipomatous tumors, from other tissues, while MR imaging is able to provide a typical aspect of fat intensity comparable to that of subcutaneous tissue [7]. While CT scan is useful in determining tumor extension prior to intervention, coronary angiography should be performed to exclude their affection

by the tumor [8] or by more common atherosclerotic disease that could influence the intra- and post-operative evolution [9].

Because of its slow growth rate, it is generally considered that asymptomatic patients should undergo routine echocardiographic evaluations at short intervals until symptoms or aspect changes should appear on imagistic studies [6]. In symptomatic cases, the surgical treatment include resection via median sternotomy or left/right anterior thoracotomy, although good results have been reported with less invasive methods such as video assisted thoracoscopic surgery [10].



**Figure 4:** (A) Postexcision aspect of fragmented lipomatous tumor. (B) Mature adipocytes on histological examination. (H&E staining; magnification  $\times 10$ ).

In our case, the size and the placement of the tumor, surrounding the both ventricles, made the sternotomy mandatory, without using

the cardiopulmonary bypass. As in all the previous reported cases, the postoperative course was uneventful. This case report represents an example of a rare cardiac tumor with an exceptional localization and its associated management, while current imagistic methods simplify decisions-making in the clinical practice.

## Conclusion

The lipoma originating from the right ventricular infundibulum is a very rare situation. Although the majority of intrapericardial lipomas are usually asymptomatic, presenting as incidental findings of common diagnostic imaging, symptomatic intrapericardial masses have a surgical indication. Surgical resection is necessary not only for the alleviation of symptoms, but also for diagnostics reasons.

## References

1. McAllister HA Jr, Hall RJ, Cooley DA (1999) Tumors of the heart and pericardium. *Curr Probl Cardiol* 24: 57-116.
2. Kelly DJ, Ramachandran S, Arya S (2007) Epicardial lipoma mimicking pericardial effusion. *Heart* 93: 612.
3. Bardakci H, Altintas G, Unal U, Kervan U, Arda K, et al. (2008) Giant cardiac lipoma: report of a case. *J Card Surg* 23: 254-256.
4. Bagwan IN, Sheppard MN (2009) Cardiac lipoma causing sudden cardiac death. *Eur J Cardiothorac Surg* 35: 727.
5. Friedberg MK, Chang IL, Silverman NH, Ramamoorthy C, Chan FP (2006) Images in cardiovascular medicine. Near sudden death from cardiac lipoma in an adolescent. *Circulation* 113: e778-779.
6. Gurrbach F, Mohr FW, Misfeld M (2012) Epicardial lipoma-a rare differential diagnosis in cardiovascular medicine. *European journal of cardio-thoracic surgery: official journal of the European Association for Cardio-thoracic Surgery* 41: 699-701.
7. Ganame J, Wright J, Bogaert J (2008) Cardiac lipoma diagnosed by cardiac magnetic resonance imaging. *Eur Heart J* 29: 697.
8. Achouh PE, Zegdi R, Azarine A, Fabiani JN (2009) Cardiac epicardial tumor with coronary artery compression. *Eur J Cardiothorac Surg* 35: 362.
9. Kanemitsu S, Hirano K, Shimono T, Shimpo H (2014) A case of a large cardiac lipoma with coronary artery disease. *Asian Cardiovasc Thorac Ann* 22: 604-606.
10. Sciuchetti JF, Corti F, Ballabio D, Formica F, Aiello A, et al. (2008) Video-assisted thoracic surgical resection of giant cardiac lipoma: a case report. *Int J Cardiol* 123: e57-58.