

Gastrocolic Fistula as a First Sign of Crohn's Disease Started during Pregnancy and Treated Effectively without Any Neonatal Harm – Case Report

Klaudia Farkas¹, Anita Bálint¹, Renáta Bor¹, László Tiszlavicz², Ferenc Nagy¹, Zoltán Szepes¹ and Tamás Molnár^{1*}

¹First Department of Medicine, University of Szeged, Szeged, Hungary

²Department of Pathology, University of Szeged, Szeged, Hungary

*Corresponding author: Tamás Molnár, First Department of Medicine, University of Szeged, H-6720, Korányi fasor 8-10, Szeged, Hungary, Tel: +36-62-545186; Fax: +36-62-545185; E-mail: mot@in1st.szote.u-szeged.hu

Received date: June 06, 2014, Accepted date: July 18, 2014, Published date: July 25, 2014

Copyright: © 2014 Farkas et al. This is an open-access article distributed under the terms of the Creative Commons Attribution License, which permits unrestricted use, distribution, and reproduction in any medium, provided the original author and source are credited.

Abstract

Gastrocolic fistula is a rare complication of Crohn's disease (CD). Due to its asymptomatic presence in the majority of the cases, the diagnosis may be delayed. Anti TNF- α therapy has previously been shown to be effective in the induction and maintenance therapy of fistulizing CD. Anti TNF- α therapy is graded as probably safe in pregnancy. We report a case of gastrocolic fistula secondary to CD in a young pregnant woman who avoided surgery and achieved remission after receiving infliximab induction therapy.

Keywords: Crohn's disease; Gastrocolic fistula; Pregnancy; Infliximab

Abbreviations:

CD: Crohn's Disease; CRP: C - Reactive Protein; ECCO: European Crohn's and Colitis Organisation; TNF: Tumor Necrosis Factor

Background

Different, usually mild-to-moderate gastrointestinal symptoms are relatively common even during normal pregnancy. Increased levels of female sex hormones may cause or contribute to symptoms such as heartburn, nausea, vomiting or constipation [1]. In contrary, beginning of Crohn's disease (CD) during pregnancy is extremely rare, and if the leading symptoms are not characteristics, diagnosing the disease is also challenging. Anyway, pregnancy is a special condition in the diagnosis and in the management of CD. It is important to consider the risks, benefits, and optimal timing of diagnostic evaluation such as endoscopy or imaging studies in pregnant women. Endoscopy should be performed in case of strong indication and should be postponed to the second trimester when possible [2]. However, occurrence of debilitating symptoms during pregnancy is essential to be investigated, because the risk of inflammatory disease during pregnancy carries a significant risk to adverse outcome. In case of proven inflammatory bowel disease the main goal is to maintain remission not even at the time of conception but during pregnancy. Anti TNF- α therapy proved its efficacy to maintain remission and to treat flares of CD during pregnancy. Although anti-TNF- α agents are also effective in the management of fistulizing CD, no case report have published the outcome of anti TNF- α therapy in a pregnant women with gastrocolic CD diagnosed during pregnancy.

Case Presentation

A 35-year-old, 14 weeks pregnant women was admitted to our clinic in December 2012 with long-standing mild diarrhea, worsening left subcostal pain, and odorous belching. Her complaints were

provoked by eating and despite a normal appetite; she lost weight of 10 kg within a year. Her medical history was not remarkable and there was no history of fever, chills or bloody stools in the previous period. Gastroscopy and colonoscopy were performed in a rural hospital some weeks before her admission. The endoscopic findings suggested the presence of stenotizing CD or malignancy in the pylorus and the splenic flexure of the colon and resection surgery was recommended with the termination of the pregnancy to avoid the development of mechanical ileus. On admission to our clinic, the patient was afebrile. On physical examination no significant abnormality was observed. The laboratory findings showed moderately elevated C-reactive protein (CRP) level of 53.4 mg/l (normal level: <2 mg/l) and erythrocyte sedimentation rate of 32 mm/h with mild anaemia (hematocrit: 33%, haemoglobin: 108 g/l). Abdominal ultrasonography included irregular wall thickening of the splenic flexure attached with the stomach. Repeated gastroscopy revealed a fistula opening at the corpus-antrum transition zone with feculent discharge (Figure 1). However, free passage was observed through the pylorus suggesting the misinterpretation of the findings of the first gastroscopy. Colonoscopy was performed to 50 cm at the splenic flexure at which point the mucosa was severely edematous and friable with pseudopolyps, the lumen was narrowed and the fistulous opening could also be visualized (Figure 2). After a consultation with a radiologist, abdominal MRI was not performed due to the possible toxic effect of gadolinium. Histology confirmed CD both in the gastric and the colonic samples with granuloma formation and excluded malignant disease (Figure 3). Oral methylprednisolone therapy was started in a dose of 48 mg daily. Screening examinations were performed and infliximab 5 mg/kg was introduced with good efficacy. Methylprednisolone was tapered gradually and stopped after 12 weeks. After the induction therapy the patient achieved clinical remission and biological therapy was discontinued considering the oncoming third trimester. In May 2013 the patient had an uncomplicated delivery after 34 weeks, the weight of the newborn was 1990 g, and the height was 48 cm. In August 2013 she had only mild symptoms (mild abdominal pain and diarrhea) without significant activity and with normal CRP and blood count. Control abdominal ultrasonography showed significant improvement with the decrease of wall thickening and

disappearance of gastrocolic fistula. Control gastroscopy also revealed the closure of the fistula (Figure 4). Colonoscopy is planning to be repeated after stopping breastfeeding to decide about the continuation of infliximab therapy.

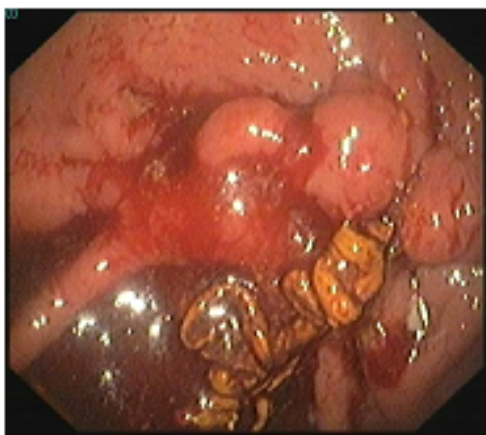
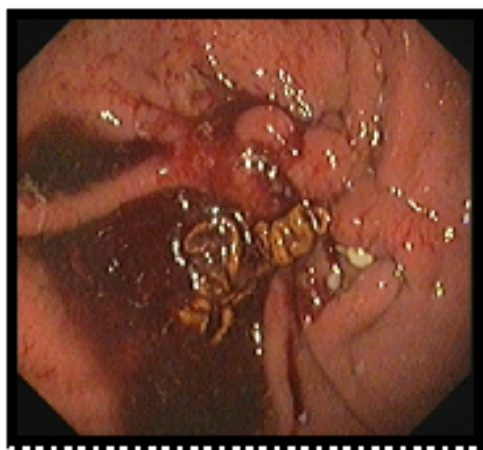
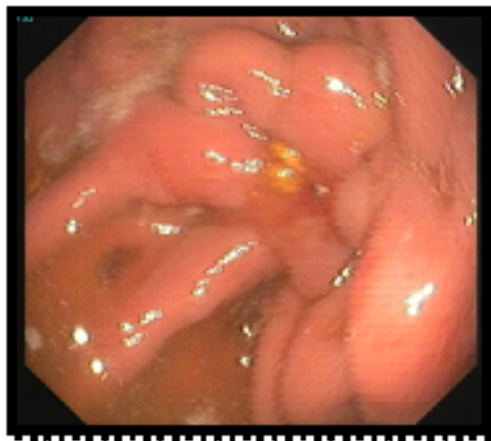
Figure 1: Gastroscopy revealed a fistula opening at the corpus-antrum transition zone with feculent discharge.

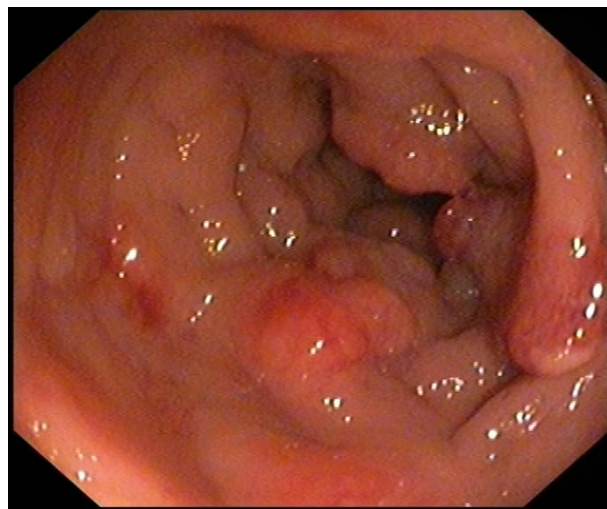


Figure 2: Severe inflammation at the splenic flexure with the fistulous opening.

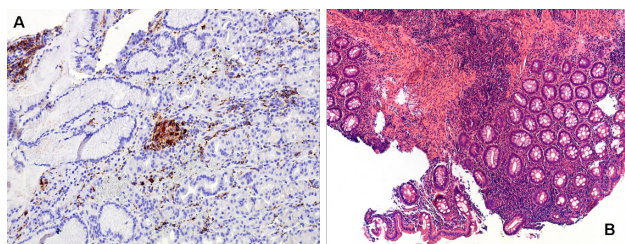


Figure 3: Histology confirmed the presence of Crohn's disease both in the gastric and the colonic samples with granuloma formation.

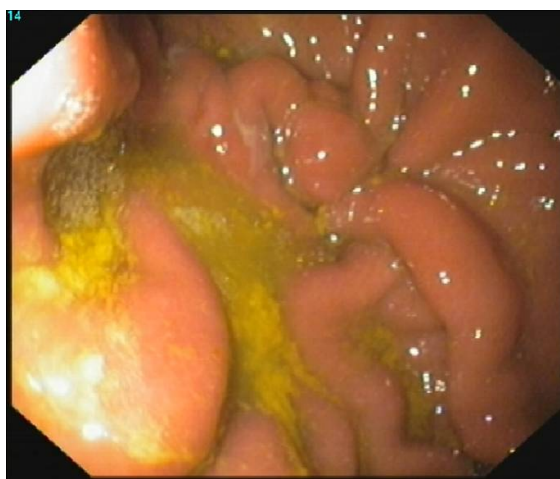

Figure 4: Closure of the fistula during control gastroscopy

Discussion

Here we reported a CD case with many rarities: first, CD was diagnosed during pregnancy; second, gastrocolic fistula was the first manifestation and third, successful anti-TNF- α induction therapy was introduced during pregnancy.

Enterocutaneous or perianal fistulas develop in approximately 35% of CD patients. Internal fistulas, secondary to transmural inflammation of the bowel, may be asymptomatic for a long time therefore delaying the diagnosis [3]. In the population-based cohort by Schwartz et al. the cumulative incidence of fistulizing CD was 33% after 10 years and 50% after 20 years [3]. In this study 24% of the fistulizing episodes were from entero-enteric fistulas. Gastrocolic fistulas, however, are rare in CD. Development of a gastrocolic fistula secondary to CD is thought to be a result of inflammation in the transverse colon with deep ulceration and subsequent fibrosis and therefore fistula formation to the adjacent stomach [4]. The classic triad of symptoms in CD patients with gastrocolic fistulas is diarrhea, weight loss and fecal halitosis or vomiting, although, abdominal pain is also frequently presented in combination with diarrhea and weight loss. Gastrocolic fistulas require surgical intervention in the majority of the cases, followed by treatment with a combination of antibiotics, immunosuppressants, and anti-TNF- α therapy to control of fistula drainage and prevention of abscess formation.

In a review of 14 cases of CD with gastrocolic or duodenocolic fistulas seen over 20 years at one institution, 1 patient had closure with prednisolone and the other 13 patients all underwent surgery [5]. In a series of six patients with gastrocolic fistulas seen at Mount Sinai Hospital over 23 years, two patients responded to 6-mercaptopurine [5].

Previous studies confirmed the efficacy of anti-TNF- α agents in the induction and maintenance therapy of fistulizing CD [6-8], although prospective study focusing on the efficacy of anti-TNF α agents in the treatment of entero-enteral fistula was never been performed. According to the European Crohn's and Colitis Organisation (ECCO) opinion on drug safety during pregnancy, infliximab is graded as probably safe [9]. Since infliximab crosses the placenta particularly in the second and third trimester and can be detected in the circulation through the first 6 months of life, timing of the last dose of anti TNF therapy should be as early in the third trimester of pregnancy to limit the transport of the drug to foetus [ECCO Statement 4F EL5 RG D] [9]. In the study of Mahadevan et al. detectable infliximab levels were shown in 8 healthy infants delivered after pregnancies during which mothers were receiving infliximab every 8 weeks, with the last infusion being delivered at the mean time of 66 days before birth. At birth, levels were higher in infants, and were measurable for 2 to 7 months [10].

Our case report demonstrates the diagnostic and therapeutic difficulties of this rare complication of CD in a pregnant woman. The management of internal fistulas has been changed substantially over the last decades. Surgery was previously the only treatment, but now more conservative alternatives including medical therapy, such as anti TNF- α therapy and surgical intervention are available. Caution should be taken when anti TNF agents are used during pregnancy and it should be temporary discontinued to avoid severe complications of the infants. In our case, surgery would have led to the termination of the pregnancy, thus as an ultimatum, infliximab therapy was introduced. Induction therapy was successful, the therapy was stopped in time and the patient gave birth to a healthy baby. To our knowledge, this is the first case when infliximab led to the closure of gastrocolic fistula in a pregnant CD patient avoiding resection surgery and the early termination of the pregnancy.

References

1. Keller J, Frederking D, Layer P (2008) The spectrum and treatment of gastrointestinal disorders during pregnancy. *Nat Clin Pract Gastroenterol Hepatol* 5: 430-443.
2. ASGE Standard of Practice Committee, Shergill AK, Ben-Menachem T, Chandrasekhara V, Chathadi K, et al. (2012) Guidelines for endoscopy in pregnant and lactating women. *Gastrointest Endosc* 76: 18-24.
3. Schwartz DA, Loftus EV Jr, Tremaine WJ, Panaccione R, Harmsen WS, et al. (2002) The natural history of fistulizing Crohn's disease in Olmsted County, Minnesota. *Gastroenterology* 122: 875-880.
4. Khanna MP, Gordon PH (2000) Gastrocolic fistulization in Crohn's disease: a case report and a review of the literature. *Can J Surg* 43: 53-56.
5. Levy C, Tremaine WJ (2002) Management of internal fistulas in Crohn's disease. *Inflamm Bowel Dis* 8: 106-111.
6. Present DH, Rutgeerts P, Targan S, Hanauer SB, Mayer L, et al. (1999) Infliximab for the treatment of fistulas in patients with Crohn's disease. *N Engl J Med* 340: 1398-1405.
7. Sands BE, Blank MA, Diamond RH, Barrett JP, Van Deventer SJ (2006) Maintenance infliximab does not result in increased abscess development in fistulizing Crohn's disease: results from the ACCENT II study. *Aliment Pharmacol Ther* 15: 1127-1136.
8. Colombel JF, Sandborn WJ, Rutgeerts P, Enns R, Hanauer SB, et al. (2007) Adalimumab for maintenance of clinical response and remission in patients with Crohn's disease: the CHARM trial. *Gastroenterology* 132: 52-65.
9. van der Woude CJ, Kolacek S, Dotan I, Oresland T, Vermeire S, et al. (2010) European evidenced-based consensus on reproduction in inflammatory bowel disease. *J Crohns Colitis* 4: 493-510.
10. Mahadevan U, Wolf DC, Dubinsky M, Cortot A, Lee SD, et al. (2013) Placental transfer of anti-tumor necrosis factor agents in pregnant patients with inflammatory bowel disease. *Clin Gastroenterol Hepatol* 11: 286-292.