

Gastric and Duodenal Pseudomelanosis in a Patient with Anaemia

Marcelo Campos Appel-da-Silva^{1*}, Rafael Bergesch D'Incao¹, Eduardo Marques Corrêa¹, Bruno Galperim¹ and Mariana Guimarães Coelho²

¹Department of Gastroenterology and Endoscopy, Hospital Mãe de Deus, Porto Alegre, Brazil

²Department of Pathology, Hospital Mãe de Deus, Porto Alegre, Brazil

*Corresponding author: Marcelo Campos Appel-da-Silva, Rua Jose de Alencar, 286 Porto Alegre, RS 90880-480, Brazil, Tel: +5551991134418; E-mail: marceloappel@yahoo.com.br

Received date: May 31, 2017; Accepted date: June 02, 2017; Published date: June 06, 2017

Copyright: © 2017 Appel-da-Silva MC, et al. This is an open access article distributed under the terms of the Creative Commons Attribution License, which permits unrestricted use, distribution, and reproduction in any medium, provided the original author and source are credited.

Citation: Appel-da-Silva MC, D'Incao RB, Corrêa EM, Galperim B, Coelho MG (2017) Gastric and Duodenal Pseudomelanosis in a Patient with Anaemia. J Hepatol Gastroint Dis 3: i105. doi:[10.4172/2475-3181.1000i105](https://doi.org/10.4172/2475-3181.1000i105)

Clinical Image

An 87-year-old man with diabetes mellitus, hypertension, past history of colonic cancer and a current treatment for prostate cancer was admitted to the Oncology Ward for evaluation of iron-deficiency anaemia. He was taking gosereline, zoledronic acid and dexametasone. An upper gastrointestinal endoscopy was performed and revealed a mucosal abnormality characterized by discoloration of the posterior wall of part of his gastric corpus, antrum and over the duodenum (Figure 1). No ulcers, erosions, or any other causes for bleeding were identified. Histopathology report confirmed the presence of loose aggregates of macrophages containing a granular black pigment within the superficial lamina própria, which tested positive for iron at Perl's stain (Figure 2). *Helicobacter pylori* organism was absent. Patient informed recent use of ferrous sulfate.

Pseudomelanosis of the gastrointestinal tract is a rare endoscopic mucosal finding, characterized, endoscopically as discrete, flat, small, black spots in a speckled pattern on a flat mucosa, representing the accumulation of iron in macrophages of the lamina propria of the stomach and duodenum.

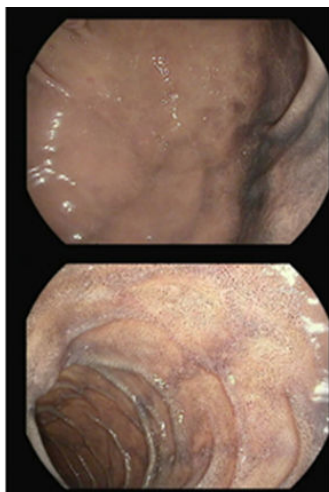


Figure 1: Discoloration of the posterior wall of part of his gastric corpus, antrum and over the duodenum.

The clinical significance and long term sequelae have not been clarified yet. However, this benign condition is associated with a variety of clinical conditions, such as chronic renal disease, hypertension, diabetes mellitus, oral iron supplementation, antihypertensive medications.

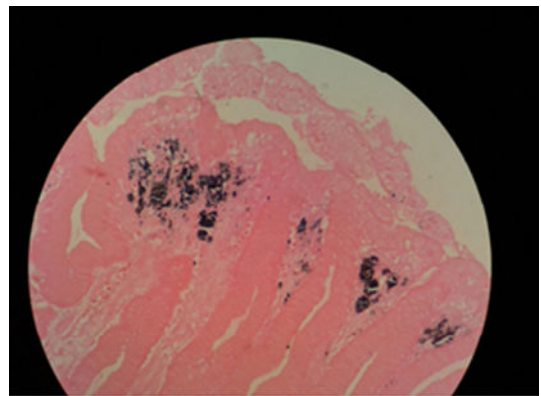


Figure 2: Loose aggregates of macrophages containing a granular black pigment within the superficial lamina própria.

References

1. Qureshi NU, Younus MF, Alavi K, Sheikh MY (2016) Gastric and duodenal pseudomelanosis: An extended unusual finding in a patient with end stage kidney disease. Case Rep Gastrointest Med pp: 3.
2. Alraies MC, Alraiyes AH, Baibars M, Shaheen K (2014) Pseudomelanosis of the stomach. Q J Med 107: 83-84.
3. Vuppalachchi R, Vakili ST, Kahi CJ (2007) Isolated melanosis of the gastric antrum: An unusual endoscopic finding. Clin Gastroenterol Hepatol 5: e2.
4. Weinstock LB, Katzman D, Wang HL (2003) Pseudomelanosis of stomach, duodenum and jejunum. Gastrointest Endosc 58: 578.