

Fugo Plasma Blade Assisted Ablation of Conjunctival Nevi- A Series of 2 Cases

Swati Singh^{1*} and Daljit Singh²

¹Department of Ophthalmology, L J Eye Institute, Ambala, India

²Department of Ophthalmology, Daljit Eye Centre, Amritsar, India

*Corresponding author: Swati Singh, Department of Ophthalmology, Dacryology and Ocular Oncology services, L J Eye Institute, Ambala, India, Tel: +91 7036981646; E-mail: dr.swati888@yahoo.com

Received date: July 12, 2018; Accepted date: August 07, 2018; Published date: August 17, 2018

Copyright: ©2018 Singh S, et al. This is an open-access article distributed under the terms of the Creative Commons Attribution License, which permits unrestricted use, distribution, and reproduction in any medium, provided the original author and source are credited

Abstract

Surgical excision of conjunctival nevi results in good cosmetic outcome but with its associated side effects like pyogenic granuloma, pseudopterygium and limbal stem cell deficiency. We report a novel non-surgical, Fugo blade assisted ablation of one giant conjunctival nevus and one superficial conjunctival nevus in adolescent females. Plasma assisted ablation of pigmented layers was performed with minimal tissue handling under topical anesthesia, with resultant satisfactory cosmesis and almost no scarring. Fugo blade assisted removal of pigmented lesions of conjunctiva results in ocular surface restoration without the need of amniotic membrane. It might be a good alternative to the use of amniotic membrane in conjunctival nevi removal.

Keywords: Conjunctival nevus; Fugo blade; Amniotic membrane

Introduction

Most commonly presenting pigmented conjunctival tumour is benign conjunctival nevi which accounts for 52% out of all melanocytic origin tumours (53%) [1,2]. Observation with periodic photographs is the preferred modality for its management. 3 Clinical factors predictive of surgical excision in a conjunctival nevus are greater age, documented tumour growth, limbal location with corneal involvement and prominent feeder vessels [3-5]. Simple surgical excision with amniotic membrane transplantation (AMT) has been the traditional choice of treatment [6]. Laser ablation using argon laser and PASCAL has been tried for superficial conjunctival pigmentation with successful results, however in small numbers with inherent potential risk of ciliary body detachment, collateral damage [7,8].

Fugo blade has been employed for iridotomy, glaucoma surgeries and capsulotomies in the past [9-11]. However, its use has never been reported before for ocular surface. We report a novel technique for the treatment of diffuse superficial conjunctival nevi using Fugo plasma blade.

Methods

Retrospective chart analysis and documentation was done for cases of conjunctival nevi operated at a private eye center over a period of one year. Study was conducted in adherence to principles of declaration of Helsinki. Informed consent was obtained from both the patients prior to procedure.

Surgical Technique

The surgery is done with the patient lying supine. Topical anaesthetic paracaine drops were instilled and wire speculum was placed. Lignocaine 2% (0.3 cc) was injected sub-conjunctivally under the lesion so that it gets raised away from the sclera. Under operating

microscope, Fugo blade (Medisurg Research & Management) 500 micron tip is used at medium power and medium/high intensity. It is used to ablate the pigmented area layer by layer until the normal tissue is visible (Video attached). No bleeding was noted during the procedure. In case of extensive surface involvement, we prefer to remove lesion in multiple sittings. However, exact guidelines regarding the extent and number of sitting would be available after analyzing large number of cases. Topical antibiotic drops were prescribed for 1 week along with lubricants. Patient was reviewed periodically.

Case 1

A 19-year-old girl presented with pigmented lesion in left eye since birth. Slit lamp examination revealed a flat pigmented lesion measuring 16 × 10 mm in left nasal bulbar conjunctiva extending from 8 to 11'o (limbal) clock hours (Figure 1A). Another small 3 × 1.5 mm similar kind of lesion was also observed just temporal to plica semilunaris with a stalk like extension from the main lesion. Multiple intralesional clear cysts were observed.

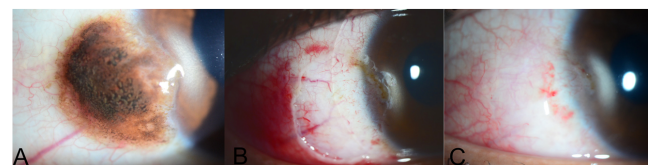


Figure 1: (A) A 19-year-old girl with giant pigmented nevus with intra-lesional cysts involving left nasal bulbar conjunctiva, (B) showing 60% reduction in the size of lesion post one sitting of ablation, and near complete tumour resolution after 2nd sitting of ablation with healthy ocular surface (C).

There was no corneal/caruncular/forniceal conjunctival involvement without any underlying fixity to sclera. Clinical diagnosis

of left giant conjunctival nevus was made. Patient was keen for surgical excision due to cosmetic concern. Considering the extensive involvement of bulbar conjunctiva, surgical ablation of lesion using Fugo blade was performed in 2 sittings, 2 months apart (Figure 1B). At one year follow up, there was no evidence of limbal stem cell deficiency (LSCD) or pterygium (Figure 1C). The little visible pigment was also removed. She had satisfactory cosmesis.

Case 2

A 12-year-old female presented with pigmented nodular lesion in right temporal bulbar conjunctiva measuring $4.5 \times 2 \times 1$ mm extending for 2 o'clock hour with limbal involvement (Figure 2A). A single prominent feeder vessel was visible which was neither engorged nor tortuous. Clinical diagnosis of right conjunctival nevus was made. Surgical ablation using Fugo blade was carried out using the above-described technique. A bandage contact lens was placed at the end of surgery (Figure 2B). The contact lens was removed after 3 weeks. Complete resolution of lesion was noted with restoration of ocular surface (Figure 2C). At last follow up of 6 months, there was no evidence of any residual/recurrence. Patient did not raise any concern for very mild residual pigmentation. No evidence of limbal stem cell deficiency or pseudo-ptyerygium or dry eye was noted.

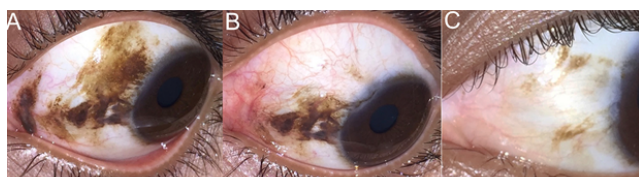


Figure 2: (A) A 12-years-old female with elevated pigmented nevus involving right temporal conjunctiva with limbal involvement and a prominent feeder vessel, (B), showing BCL over conjunctival epithelial defect one day post ablation with visible and intact underlying tenon's, and complete healing at 1 month with healthy ocular surface (C).

Discussion

Minimal collateral damage with precision of tissue cutting helps in layer by layer removal of conjunctival nevi, resulting in an ocular surface with minimal scarring. Fugo blade assisted removal of giant pigmented lesions restores ocular surface without the need of amniotic membrane transplantation.

Surgical excision of conjunctival tumors is traditionally performed using no touch Shields technique with cryotherapy to margins followed by ocular surface reconstruction with an amniotic membrane. Askolis et al. observed superficial peripheral corneal vascularisation and opacification as a sign of partial limbal stem cell deficiency in 2 eyes out of 9 eyes (5 were nevi) post amniotic membrane use for reconstruction [12]. Long term results of use of amniotic membrane in large ocular surface tumor by Palamar et al. revealed limbal stem cell deficiency in three eyes and mild symblepharon in one eye out of 21 eyes [13]. Shields et al. reported nevus recurrence in 4 cases (17%), pterygium in 1 (4%), dry eye in 1 (4%), and eyelid blepharoptosis in 1 (4%) post excisional biopsy in their series of 23 giant nevi [14]. AMT has produced good surgical results but with associated side effects of LSCD, pyogenic granuloma and peripheral

vascularisation. In benign tumors, there is no need to excise till episclera. Minimal invasive approach to pterygium (where tenon's is left undisturbed) has shown lesser recurrence rates when compared to deeper dissection till episclera [15]. With the use of Fugo blade, layered ablation helps in preserving healthy uninvolved tissue and minimises tissue handling especially of tenon's layer. Application on corneal surface was not needed in any of our cases as there was no corneal component.

The Fugo blade is an electrosurgical device that produces non-cauterising haemostasis and precise tissue cutting while minimally affecting the adjacent tissue and sterilizing the wall of the incision (Information provided by Medisurg Ltd. and R. Fugo) [11]. The blunt instrument produces a microscopic plasma cloud around a filament that dissolves the molecular bonds of the target tissue when activated (Figure 2A). U.S. Food and Drug Administration have approved this plasma blade for capsulotomy, iridotomy and transscleral filtration. It is a portable device with solid-state system that uses C-cell batteries. Histologic studies at the University of South Carolina and Louisiana State University on the incision walls created by this plasma blade have demonstrated pristine, clean incision walls based on nanotechnology stripping of tissue molecules, thereby eliminating the charring or incision wall damage seen in most other standard electrosurgical systems.

Additional cost of amniotic membrane is not incurred, making this a cost effective technique. We recommend avoiding it or performing an incision biopsy in suspicious lesions for histopathological confirmation. Utilizing this technique in large number of cases will give evidence for any long-term complications.

To conclude, Fugo blade assisted removal of conjunctival nevus especially giant ones, results in restoration of ocular surface, saving the need of amniotic membrane.

References

1. Shields CL, Demirci H, Karatza E, Shields JA (2004) Clinical survey of 1643 melanocytic and nonmelanocytic conjunctival tumors. *Ophthalmology* 111: 1747-1754.
2. Shields JA, Shields CL (1999) *Atlas of Eyelid and Conjunctival Tumors*. Philadelphia: Lippincott Williams & Wilkins p243-251.
3. Shields CL, Fasiuddin A, Mashayekhi A, Shields JA (2004) Conjunctival nevi: clinical features and natural course in 410 consecutive patients. *Arch Ophthalmol* 122: 167-175.
4. Levecq L, De Potter P, Jamart J (2010) Conjunctival nevi clinical features and therapeutic outcomes. *Ophthalmology* 117: 35-40.
5. Folberg R, Jakobiec FA, Bernardino VB, Iwamoto T (1989) Benign conjunctival melanocytic lesions: clinicopathologic features. *Ophthalmology* 96: 436-461.
6. Oellers P, Karp CL (2012) Management of pigmented conjunctival lesions. *Ocul Surf* 10: 251-263
7. Shin KH, Hwang JH, Kwon JW (2013) Argon laser photocoagulation of superficial conjunctival nevus: results of a 3-year study. *Am J Ophthalmol* 155: 823-828.
8. Park YM, Lee JE, Lee JS (2016) Efficacy of Pattern Scan Laser photocoagulation for superficial conjunctival nevi ablation. *Lasers Med Sci* 31: 1037-1039.
9. Peponis V, Rosenberg P, Reddy SV, Herz JB, Kaufman HE (2006) The use of the Fugo Blade in corneal surgery: a preliminary animal study. *Cornea* 25: 206-208.
10. Trivedi RH, Wilson ME Jr, Bartholomew LR (2006) Extensibility and scanning electron microscopy evaluation of 5 pediatric anterior

-
- capsulotomy techniques in a porcine model. J Cataract Refract Surg 32: 1206-1213.
11. Singh D, Singh K (2002) Transciliary filtration using the Fugo Blade. Ann Ophthalmol 34: 183-187.
12. Asoklis RS, Damijonaityte A, Butkiene L, Makselis A, Petroska D, et al. (2011) Ocular surface reconstruction using amniotic membrane following excision of conjunctival and limbal tumors. Eur J Ophthalmol 21: 552-558.
13. Palamar M, Kaya E, Egrilmez S, Akalin T, Yagci A (2014) Amniotic membrane transplantation in surgical management of ocular surface squamous neoplasias: long-term results. Eye (Lond) 28: 1131-1135.
14. Shields CL, Regillo AC, Mellen PL, Kaliki S, Lally SE, et al. (2013) Giant conjunctival nevus: clinical features and natural course in 32 cases. JAMA Ophthalmol 131: 857-863.
15. Bozkir N, Yilmaz S, Maden A (2008) Minimally invasive pterygium surgery: a new approach for prevention of recurrence. Eur J Ophthalmol 18: 27-31.