

Fresh Seed Supplementation of *Syzygium Cumini* Attenuated Oxidative Stress, Inflammation, Fibrosis, Iron Overload, Hepatic Dysfunction and Renal Injury in Acetaminophen Induced Rats

Md Abu Taher Sagor*, Md Mohabulla Mohib, Nabila Tabassum, Ishfaq Ahmed, Hasan Mahmud Reza and Md Ashraful Alam

Department of Pharmaceutical Sciences, School of Life Sciences, North South University, Bangladesh

*Corresponding author: Md Abu Taher Sagor, Department of Pharmaceutical Sciences, North South University Bangladesh, Tel: +8801719130130; E-mail: sagor2008nsu@gmail.com, abu.taher@northsouth.edu

Received date: April 22, 2016; Accepted date: May 18, 2016; Published date: May 29, 2016

Copyright: © 2016 Sagor MAT, et al. This is an open-access article distributed under the terms of the Creative Commons Attribution License, which permits unrestricted use, distribution, and reproduction in any medium, provided the original author and source are credited.

Abstract

Nowadays, the drug induced organ damage has increased drastically. Similarly, number of Adverse Drug Reactions (ADR) is on the rise. Unwanted and harmful effects of a drug have been a good reason for early withdrawal of a good molecule from the market or clinical trial. In the present study, we have investigated the preventive role of *Syzygium cumini* against Acetaminophen induced organ damage. In this study, four different groups of rats were evaluated. Group A serves as a control group, Group B serves as control + *Syzygium cumini* group, Group C serves as disease group and Group D serves as disease + treatment group. Only two groups have been treated and exposed to an overdose of acetaminophen. However, liver and kidney markers like Aspartate Aminotransferase (AST), Alkaline Phosphatase (ALP), Alanine Transaminase (ALT), Creatinin and Uric acid (UA) were measured respectively. Moreover, oxidative stress markers such as Malondialdehyde (MDA), Nitric Oxide (NO) and Advanced Oxidation Protein Product (AOPP) were found higher in acetaminophen overdose rats compared to control rats. Furthermore, antioxidant enzymes like Catalase (CAT), Superoxide Dismutase (SOD) and Linear Peptide Glutathione (GSH) were restored significantly by *Syzygium cumini* seed treatment. Finally, our study revealed that supplementation of 1% *Syzygium cumini* seed with food attenuated inflammatory cell infiltration, collagen secretion, extracellular matrix deposition and iron overload in both hepatic and kidney. We assume that the protection might be achieved due to having strong antioxidant properties of *Syzygium cumini*.

Keywords: Hepatic and renal dysfunction; Fibrosis; Inflammation; Oxidative stress; *Syzygium cumini*

Introduction

Hepatic dysfunctions due to chronic alcoholism or drug induced liver injuries have been identified as a serious issue especially in western countries [1-3]. In USA, around 30,000 people are dying solely due to chronic liver diseases [4] which have been a new challenge for the current health care associates [5]. There are, however, drug induced liver injuries are primarily held responsible for hepatic dysfunctions which often turn to liver failure [6-8]. Unfortunately, hepatic dysfunctions sometimes occur within its therapeutic range or when a therapy is failing [9]. It has also been investigated that hepatic dysfunctions are often mediated through mast cell accumulation [10], collagen deposition [11], iron overload [12] and most importantly oxidative stress [13]. Recent studies also found out that chronic kidney diseases might trigger hepatic damage and vice versa [14].

Acetaminophen, an over the counter (OTC) drug is generally used as an antipyretic and nonnarcotic analgesic which was found quite safe and well tolerated in the therapeutic ranges but often possesses liver toxicity at overdose [15,16]. It has been noticed that around 56,000 people in USA visit in the hospital emergency department and among them over 500 people die due to acetaminophen toxicity [17]. Several possible theories have been proposed for acetaminophen induced hepatic dysfunctions. It is mostly believed that N-acetyl-p-benzoquinone Imine (NAPQI), a highly reactive metabolite which primarily damages necessary genetic materials and the cytoplasm by

depleting glutathione level [18,19]. Although, other liver enzymes like CYP2E1, CYP1A2 and CYP3A4 are also identified for liver toxicity [20]. Mitochondrial damage has frequently been blamed and accepted motive for liver damage [21]. Overdose of acetaminophen produces its metabolite, NAPQI, which primarily inhibits mitochondrial oxidative phosphorylation that further stops ATP synthesis resulted increase of Ca⁺⁺ level, decreases mitochondrial membrane potential and ultimately triggers oxidative stress [22,23] that further induces immune cell infiltration, higher extracellular matrix production, Heme Oxygenase (HO) degradation and cellular damage [24]. On the other hand, overdose of acetaminophen often causes renal injury by producing Lipid Peroxides (LPO) which directly damage kidney cell membranes. Although renal toxicity of acetaminophen is yet to be clear, but it is suggested that N-deacetylase, glutathione S-transferase and Prostaglandin Endoperoxidase Synthase (PGES) are hypothesized for kidney dysfunctions [25]. Studies also revealed that acetaminophen induced kidney injury is considerable associated with oxidative stress and production of tumor necrosis factor (TNF)-α [26].

Current medicinal therapies are not only suggested for synthetics, but also focuses on herbal based treatment strategies as these are considered to be a much safer alternative than synthetics or semi-synthetics. Use of plant products for the control of human diseases have certain advantages apart from the fact that it is cheaper to produce, biodegradable and readily available. *Syzygium cumini* is a well investigated plant and most of the parts of this plant have multiple pharmacological activities. However, it is commonly known as jam, jambolan, Malabar plum, black plum, Indian blackberry and purple plum. This plant has been highly investigated, especially in South

Asian countries like Bangladesh, India, Sri Lanka and many other countries of the world [27]. *Syzygium cumini* seed possesses several antioxidant molecules like polyphenols, flavonoids, tannins, oils, carbohydrates and alkaloids which provide multiple biological actions [28,29]. Taken together, *Syzygium cumini* has been evaluated for several purposes like anti-diarrheal, anti-ulcerogenic, antifungal, antiviral, antibacterial, anti-diabetic, chemopreventive, anti-inflammatory, anti-allergic, free radical scavenging, antioxidant and hepatoprotective [30]. Hence, hepato-Reno protective activity against acetaminophen induced injury is not well investigated. Though N-Acetylcysteine (NAC) and Montilucast have been suggested in acetaminophen induced organ dysfunctions [31] but due to having limited data and low therapeutic window [32], a new effective and safe molecule must be established for the current clinical purpose. Therefore, this study will explore the effective role of the *Syzygium cumini* seed against acetaminophen induced organ injury.

Materials and Methods

Eight to ten weeks old, 30 Long Evans female rats (160-170 g each) were obtained from Animal production unit of Animal House at Department of Pharmaceutical Sciences, North South University and were kept in individual cages in an air conditioned room where the temperature was monitored around $22 \pm 3^\circ\text{C}$ with a 12 hour dark/light cycles. Rats had the access to standard laboratory feed (Pellet foods) and mineral water, according to the study protocol, which was approved by the Ethical Committee of Department of Pharmaceutical Sciences, North South University for animal care and experimentation. To observe the Hepatic-Reno protective effects of *Syzygium cumini*, rats were divided into four different groups (6-8 rats in each group)

	Group A	Group B	Group C	Group D
Number	7-8	7-8	7-8	7-8
Duration	14 days	14 days	14 days	14 days
Treatment	Given only oral olive oil 3 ml/kg	1% w/w <i>Syzygium cumini</i> with food alone with oral olive oil 3 ml/kg	Given 1gm/kg body weight acetaminophen twice a week dissolving in PEG 400	Given 1 gm/kg body weight acetaminophen twice a week dissolving in PEG 400 alone with 1% w/w <i>Syzygium cumini</i>

Table 1: Different animal groups and their treatment strategies used in this study.

Chemicals and Reagents

The raw Acetaminophen powder was received as a gift sample from Square Pharmaceuticals Ltd, Dhaka. Thiobarbituric Acid (TBA) was purchased from Sigma Chemical Company (USA). Reduced Glutathione (GSH) and Trichloroacetic Acid (TCA) were purchased from J.I. Baker (USA). AST, ALT, ALP, Uric Acid (UA), creatine assay kits were obtained from DCI diagnostics (Budapest, Hungary), 50, 50-dithiobis-2-nitrobenzoate (Ellman's reagent) from Sigma (USA) and sodium hydroxide from Merck (Germany). All other chemicals and reagents used were of analytical grade.

Assessment of Biochemical Parameters

Liver and kidney markers like Aspartate Aminotransferase (AST), Alkaline Phosphatase (ALP), Alanine Transaminase (ALT), Uric Acids (UA) and creatinin were estimated in plasma by using Diatech diagnostic kits (Hungary) according to the manufacturer's protocol.

named as Control (Group A), Control + *Syzygium cumini* (Group B), acetaminophen over dose (Group C) and acetaminophen overdose + *Syzygium cumini* (Group D). Only rats of group B and D were provided *Syzygium cumini* seed supplement. All animals were checked for body weight, food and water intake on a daily basis. After 14 days of grouping, all animals were weighted, sacrificed, and all internal organs such as heart, kidney and spleen. Immediately after collection of the organs, they were weighted and stored in neutral buffered formalin (pH 7.4) to be processed for histology. Rat blood was homogenized and centrifuged at 8000 RPM for 10 minutes, then the clear plasma was taken. Immediately after collecting solutions, plasma was kept storage in 20°C for further biochemical analysis to observe the possible oxidative mediated hepatic and renal dysfunctions.

Administration of acetaminophen and treatment with *Syzygium cumini*

This study was not aimed to evaluate for acute toxicity rather than two weeks of the period. In our previous experiment, 2.5% (dried) *Syzygium cumini* fruit's seed supplement found very protective in high fat diet ret model (unpublished data). Thus, an approach has been made to evaluate from ripe but not dried seed on rats. Therefore, ripe and fresh *Syzygium cumini* fruits were purchased from the local market, then washed properly and dried at room temperature. Later, seeds were collected from ripe fruits and crashed a mixture in a blender and 1% w/w given every day with the chow food. *Syzygium cumini* has been identified by Mr. Sarker Nasir Uddin, Senior Scientific Officer, of the National Herbarium, Mirpur, Dhaka, Bangladesh and a receipt was deposited (Acc No. 40845) for future investigation.

Determination of Lipid Peroxidation (LPO) as Malondialdehyde (MDA)

Lipid peroxidation in plasma was estimated calorimetrically measuring malondialdehyde followed by previously described by [10,33]. Samples (1 mL) were mixed with 1 mL of 0.67% thiobarbituric acid and placed in a boiling water bath for 10 min. The mixture was cooled and diluted with 1 mL distilled water. The absorbance of the solution was then read using spectrophotometer at 532 nm. The content of Malondialdehyde (MDA) (nmol/mL) was then calculated, by reference to a standard curve of MDA solution.

Determination of Nitric Oxide (NO)

Nitric Oxide (NO) was determined according to the method described by [13,34] as nitrate. In the study, Griess-Illosvoy reagent was modified by using naphthyl ethylene diamine dihydrochloride (0.1% w/v) instead of 1-naphthylamine (5%). The reaction mixture (3

mL) containing plasma sample (2 mL) and phosphate buffer saline (0.5 mL) was incubated at 25°C for 150 min. A pink colored chromophore was formed in diffused light after addition of modified Griess-Illosvoy reagent. The absorbance of these solutions was measured at 540 nm against the corresponding blank solutions. NO level was measured by using standard curve and expressed as nmol/mL.

Determination of Advanced Protein Oxidation Products (APOP) Assay

Determination of APOP levels were performed by modification of the method by [11,35,36]. Briefly, 2 mL of plasma sample was diluted 1:5 in PBS: 0.1 mL of 1.16 M potassium iodide was then added to each tube, followed by 0.2 mL acetic acid after 2min. The absorbance of the reaction mixture was immediately read at 340 nm against a blank containing 2 mL of PBS, 0.1 mL of KI, and 0.2 mL of acetic acid. The chloramines-T absorbance at 340 nm was found linear within the range of 0-100 nmol/mL, APOP concentrations were expressed as nmol·mL⁻¹ chloramines-T equivalents.

Determination of Catalase Activity

CAT activities were determined using previously described method by [12,37,38] with few modifications. The reaction solution of CAT activities contained: 2.5 ml of 50 mmol phosphate buffer (pH 5.0), 0.4 ml of 5.9 mmol H₂O₂ and 0.1 ml enzyme extract. Changes in absorbance of the reaction solution at 240 nm were determined after one minute. One unit of CAT activity was defined as an absorbance change of 0.01 as units/min.

Determination of Reduced Glutathione Assay (GSH)

Reduced glutathione was estimated by the method of [24,39]. 1.0 ml sample of 10% plasma sample was precipitated with 1.0 ml of (4%) sulfosalicylic acid. The samples were kept at 4°C for 1 hr and then centrifuged at 1200×g for 20 min at 4°C. The total volume of 3.0 ml assay mixture composed of 0.1 ml filtered aliquot, 2.7 ml phosphate buffer (0.1 M, pH 7.4) and 0.2 ml DTNB (5,5-dithiobis-2-nitrobenzoic acid), (100 mM). The yellow color of the mixture was developed, read immediately at 412 nm on a Smart Spec TM plus Spectrophotometer and expressed as ng/mg protein.

Determination of Superoxide Dismutase (SOD)

The determination of SOD was performed by a modified procedure [14,40]. Briefly, each 300 µl reaction mixture contained 50 mM sodium phosphate (pH 7.8), 13 mM methionine, 75 mM Nitrobluetetrazolium (NBT), 2 mM riboflavin, 100 mM EDTA, and 2 ml of tissue sample. The change in absorbance of each sample was then recorded at 560 nm followed the production of blue formazan. Results were expressed as percentage activity of SOD enzyme. The equation for measuring the activity of SOD was = [(Initial absorption-subsequent absorption at 30 s interval)/Initial absorption]×100.

Estimation of Total Protein Concentration

Total protein in plasma was determined by BCA protein acid kit (Thermo Scientific) according to the manufacturer's protocol.

Histopathological Determination of Inflammation, Fibrosis and Iron Overload

For microscopic evaluation liver and kidney tissue was fixed in neutral buffered formalin and embedded in histology graded paraffin, sectioned at 5 µm with the help of Microtom and subsequently stained with hematoxylin and eosin to evaluate inflammatory cell migration. Sirius red staining was also performed to evaluate the fibrosis in liver and kidney sections. Milligan's Trichrome also showed collagen deposition in liver architectures. Moreover, Prussian blue staining was also performed to determine the iron overload in liver and kidney tissues. The slides were basically examined for pathomorphological changes. Sections were studied under light microscope at 40X magnifications.

Statistical Analysis

The values are expressed as mean ± Standard Error of Mean (SEM). The findings were analyzed by using with the help of Graph Pad Prism 6.0 software.

Results

Effect of acetaminophen and *Syzygium cumini* on body weight, food and water intake

Body weight of each rat was recorded every day during the experiment, and percentage change was calculated for all groups. It was found that the body weight increased consistently in only Group A and B, on the other hand, body weight of Group C was decreased gradually but found improvement in group D. Food intake and water intake were also found increased except for the disease group. Gradual weight loosing as well as loosing food habit might be due to acetaminophen intoxication and illness.

Parameters	Control (Group A)	Control <i>Syzygium cumini</i> (Group B)	+ Acetaminophen (Group C)	+ <i>Syzygium cumini</i> (Group D)
Initial Body weight	165.03 ± 2.54	165.48 ± 1.76	170.69 ± 3.44	171.70 ± 2.68
Final Body weight	178.82 ± 3.41	177.93 ± 1.92	167.20 ± 3.55	174.47 ± 3.99
Food intake/day	19.30 ± 2.21	19.18 ± 1.91	17.21 ± 2.62	18.04 ± 1.92
Water intake/day	18.86 ± 2.05	18.72 ± 2.05	16.78 ± 1.85	19.08 ± 2.13
Both kidney wet weight	0.62 ± 0.02	0.64 ± 0.02	0.60 ± 0.02	0.61 ± 0.04
Heart wet weight	0.34 ± 0.01	0.34 ± 0.01	0.33 ± 0.01	0.33 ± 0.00
LV wet weight	0.25 ± 0.02	0.26 ± 0.01	0.24 ± 0.01	0.24 ± 0.01
RV wet weight	0.06 ± 0.01	0.06 ± 0.00	0.05 ± 0.00	0.05 ± 0.02

Spleen wet weight	0.36 ± 0.01	0.36 ± 0.01	0.40 ± 0.03	0.38 ± 0.02
-------------------	-------------	-------------	-------------	-------------

Table 2: Effect of acetaminophen and *Syzygium cumini* various parameters in different group of rats. Values are presented as mean ± SEM. N=7-8 in each group or otherwise specified. One-way ANOVA with Bonferroni tests were done as post hoc test. Values are considered significance at $p < 0.05$. In all the cases values are found to be not significant.

Effect of acetaminophen and *Syzygium cumini* on organ wet weight

Table 2 shows the various effects of acetaminophen and *Syzygium cumini* organs wet weight. The wet weight of heart and kidney were decreased of acetaminophen rats when compared with Control. However, spleen wet weight was increased in acetaminophen treated group compared to control rats.

Effects on acetaminophen and *Syzygium cumini* on liver markers

From our biochemical assay, it was found that plasma AST, ALT and ALP concentrations were quite high may be due to acetaminophen frequent administration and activation of free radical pathogenic pathways. In all cases the liver markers (AST, ALT and ALP) values found to be reduced by the treatment (Figure 1).

Effects on acetaminophen and *Syzygium cumini* on kidney markers

It was found that plasma uric acid and creatinine concentrations were observed remarkably high may be due to acetaminophen toxicity. On the other hand kidney markers (uric acid and creatinine) values found to be lowered by treatment (Figure 2).

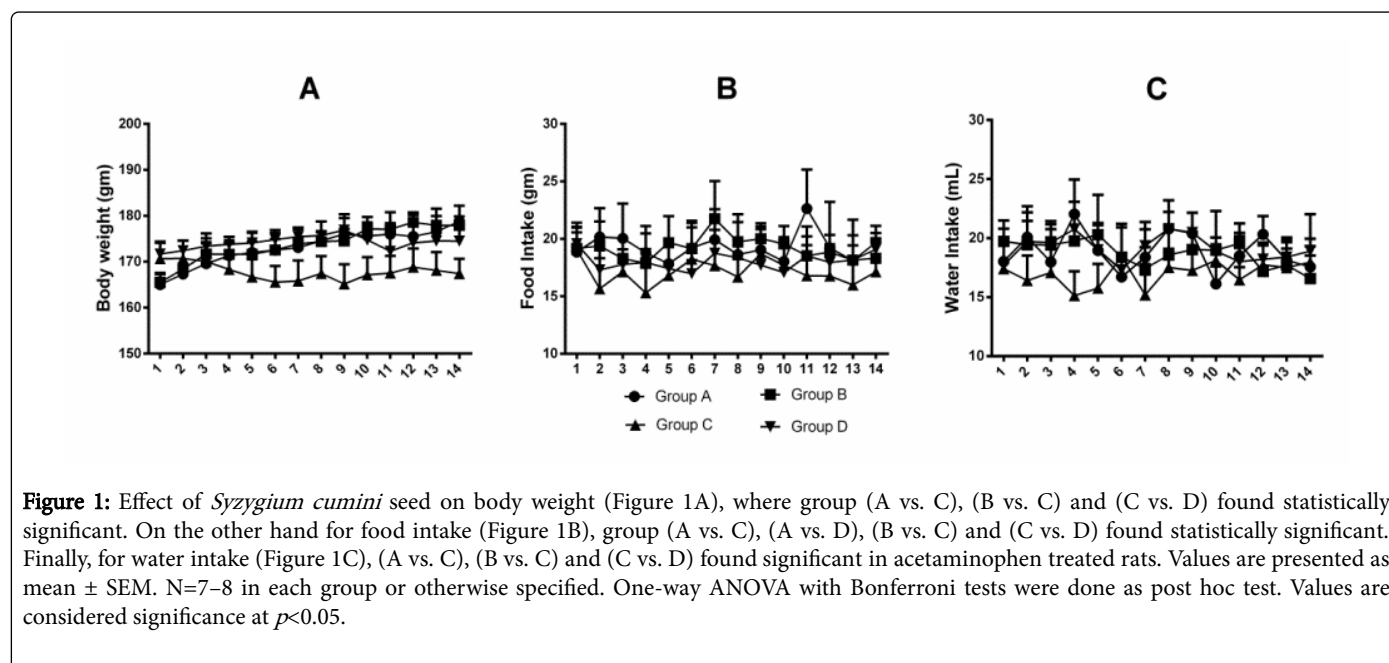


Figure 1: Effect of *Syzygium cumini* seed on body weight (Figure 1A), where group (A vs. C), (B vs. C) and (C vs. D) found statistically significant. On the other hand for food intake (Figure 1B), group (A vs. C), (A vs. D), (B vs. C) and (C vs. D) found statistically significant. Finally, for water intake (Figure 1C), (A vs. C), (B vs. C) and (C vs. D) found significant in acetaminophen treated rats. Values are presented as mean ± SEM. N=7-8 in each group or otherwise specified. One-way ANOVA with Bonferroni tests were done as post hoc test. Values are considered significance at $p < 0.05$.

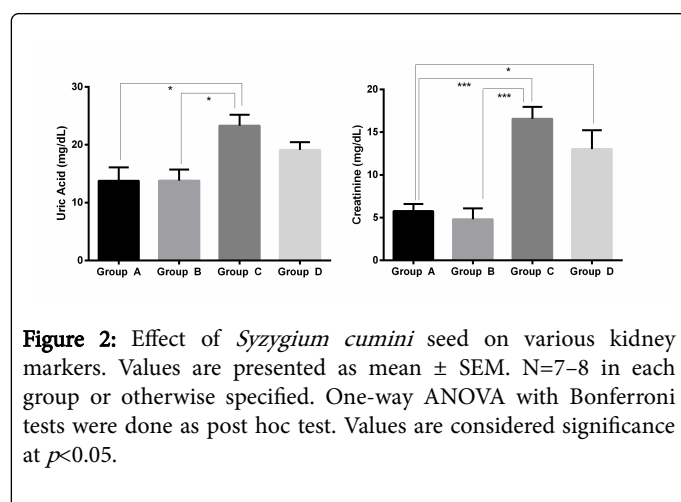


Figure 2: Effect of *Syzygium cumini* seed on various kidney markers. Values are presented as mean ± SEM. N=7-8 in each group or otherwise specified. One-way ANOVA with Bonferroni tests were done as post hoc test. Values are considered significance at $p < 0.05$.

Effects of acetaminophen and *Syzygium cumini* of natural antioxidant capacity system

Glutathione, which is considered as a potent antioxidant found (17.73 ± 1.63) in control plasma, on the other hand, acetaminophen toxic group showed (12.45 ± 2.23) ng/mg protein. Interestingly, treatment with *Syzygium cumini* improved very well and the level found more than control group (22.24 ± 1.50). In case of SOD activity, acetaminophen toxic group found the activity (15.07 ± 1.51) %, which is quite less than of control group (22.52 ± 0.88) and treatment (21.85 ± 1.91) improved almost near to control group. Surprisingly, Catalase found much improved in the treatment group (8.96 ± 1.16) which found near to the control (9.53 ± 1.81). In all cases, treatment with *Syzygium cumini* found safe when other groups were compared with Group B (Figure 3).

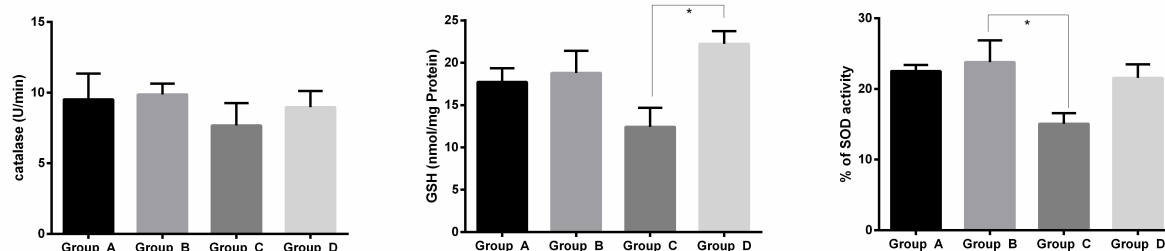


Figure 3: Effect of *Syzygium cumini* seed on various antioxidant markers. Values are presented as mean \pm SEM. N=7-8 in each group or otherwise specified. One-way ANOVA with Bonferroni tests were done as post hoc test. Values are considered significance at $p < 0.05$.

Effects of acetaminophen and *Syzygium cumini* on oxidative stress markers

NO, MDA and AOPP are the 3 most important markers which have been evaluated in this present study and found very high due to acetaminophen administration which indicates high oxidative stress inside disease group.

Our biochemical assay found that, NO, which is a vasodilator as well as signaling molecules observed almost double in Group C (25.70 ± 2.70), but 1% w/w *Syzygium cumini* significantly lowered that concentration (20.96 ± 1.64). The most dangerous free radical is known as MDA, which damage cell membrane to a larger extent.

Our control group provided (46.49 ± 1.82) nmol/ml MDA whereas administration with acetaminophen group served huge MDA level and

found almost twice as group A (81.20 ± 3.44). On the hand treatment with *Syzygium cumini* attenuated (58.07 ± 4.12 nmol/ml) that level.

Our control plasma contained (180.26 ± 9.59) nmol/mL AOPP; on the other hand, acetaminophen group showed almost three times (430.75 ± 29.58) nmol/mL higher AOPP than control kidney meanwhile treatment group (386.43 ± 24.02) significantly reduced AOPP level in the plasma. Group B did not interact with any oxidative stress parameters.

All of the levels of Group B evaluation found around the control group (Figure 4).

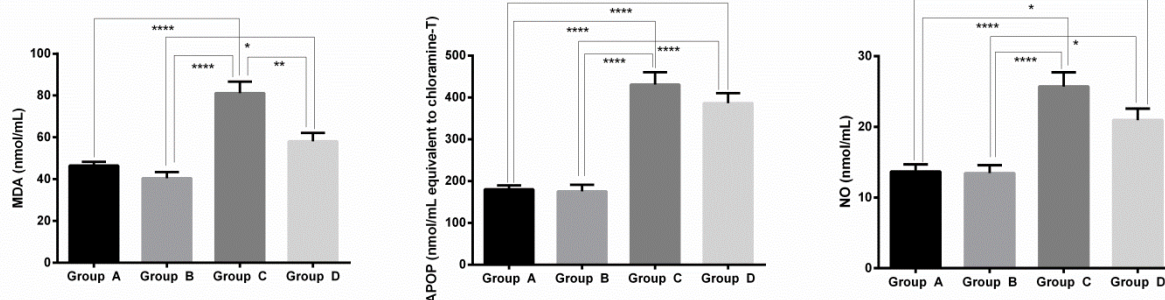


Figure 4: Effect of *Syzygium cumini* on oxidative stress parameters in kidney of acetaminophen treated rats. Values are presented as mean \pm SEM. N=7-8 in each group or otherwise specified. One-way ANOVA with Bonferroni tests were done as post hoc test. Values are considered significance at $p < 0.05$. APOP-Advanced protein oxidation product, expressed as nmol/ml equivalent to Chloramine-T.

Evaluation of Fibrosis, Inflammation and Iron Overload

In each and every case of acetaminophen administrated liver and kidney (Figures 5C-11C) showed huge fibrosis, collagen deposition, inflammatory cell accumulation and iron overload around the blood vessels as well as glomerulus which were not found in the control group (Figures 5A-11A).

Although treatment with 1% w/w *Syzygium cumini* (Figures 5D-11D) almost normalized fibrosis, collagen deposition, immune cell

migration and iron accumulation when it is compared with the control group.

Followed by, the 1% w/w *Syzygium cumini* treatment with control group did not show any wrong impression (Figures 5B-11B) on the histology pictures.

Discussion

In this study, we have evaluated liver markers like AST, ALP and ALT which clearly indicates liver damage.

When a harmful chemical invades inside liver, liver gets damaged by the destructive stimuli. Once the damage is done, necrotized and injured tissue release high amount of AST, ALT and ALP in the circulation [12].

In the present study, acetaminophen toxicity induced these liver markers observed remarkably high. Hence, it was also noticed that in chronic kidney diseases the level of AST, ALP and ALT were found high too [41]. Our disease group released massive amount of plasma markers on the other hand 1% *Syzygium cumini* seed supplement significantly lowered the concentration (Figure 12).

Similar kind of findings were observed when rat models were treated with *C. papaya* L. induced by acetaminophen [42]. It is highly observed that antioxidants have tissue repairing capacity [43] and fight against foreign invaders, thus protecting tissue [44]. We assume due to having strong antioxidant property of the *Syzygium cumini* seed, the supplement considerably reduced tissue necrosis and damage which is clearly observed by our histology pictures (Figures 5D-11D).

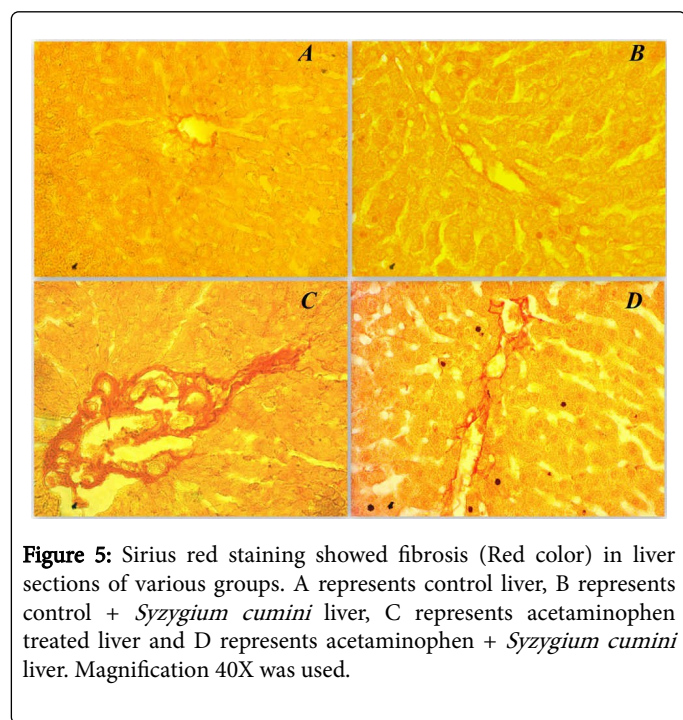


Figure 5: Sirius red staining showed fibrosis (Red color) in liver sections of various groups. A represents control liver, B represents control + *Syzygium cumini* liver, C represents acetaminophen treated liver and D represents acetaminophen + *Syzygium cumini* liver. Magnification 40X was used.

Kidney marker, Creatinine, a waste product of muscles which help in progression of several life threatening diseases like nephritis, renal hypertrophy, fibrosis and apoptosis [45]. We have found a high creatinine level in the plasma from disease group, which confirms with kidney damage. Another kidney marker, uric acid has also been found higher when compared to the control group. Production of uric acid signifies renal damage which is increased in response to xanthine oxidase and abnormal Ca^{++} level [24], uric acid further participates in immune cell infiltration. Our study investigated that supplementation of 1% *Syzygium cumini* seed with food almost normalized both creatinine and uric acid level which furthermore reduced kidney inflammation (Figure 2).

In addition, antioxidant components such as catalase, Superoxide Dismutase (SOD) and glutathione were also investigated in this present experiment. The targeted component of acetaminophen induced toxicity is Glutathione (GSH) that plays an central role to

detoxify in both liver and kidney [46]. Glutathione also ensures for protection of cellular protein and biogenesis of mitochondria [47].

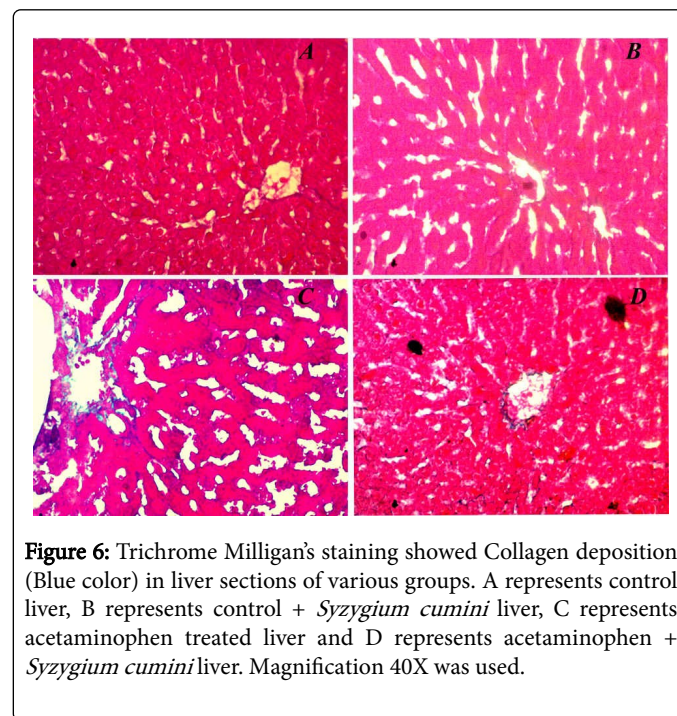


Figure 6: Trichrome Milligan's staining showed Collagen deposition (Blue color) in liver sections of various groups. A represents control liver, B represents control + *Syzygium cumini* liver, C represents acetaminophen treated liver and D represents acetaminophen + *Syzygium cumini* liver. Magnification 40X was used.

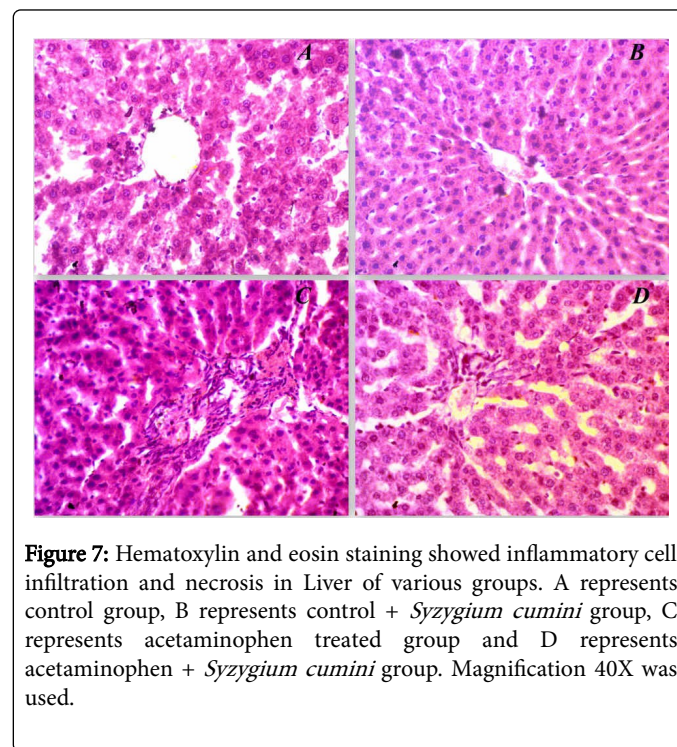


Figure 7: Hematoxylin and eosin staining showed inflammatory cell infiltration and necrosis in Liver of various groups. A represents control group, B represents control + *Syzygium cumini* group, C represents acetaminophen treated group and D represents acetaminophen + *Syzygium cumini* group. Magnification 40X was used.

The consequence of the raised antioxidant enzymes might be responsible for the hindrance of tissue damage seen by the appearance of normal architecture in the liver of acetaminophen induced rats. On the other hand, acetaminophen induced liver and kidney injury often are mediated through free radical generation. One of the culprits, superoxide anion, damages cellular materials and prevent

mitochondrial proliferation found in acetaminophen induced dysfunctions [48,49].

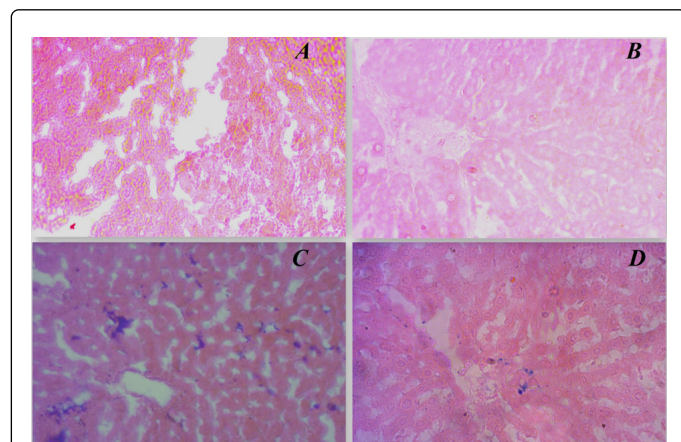


Figure 8: Prussian blue staining showed iron deposition in liver sections of various groups. A represents control group, B represents control + *Syzygium cumini* group, C represents acetaminophen treated group and D represents acetaminophen + *Syzygium cumini* group. Magnification 40X was used.

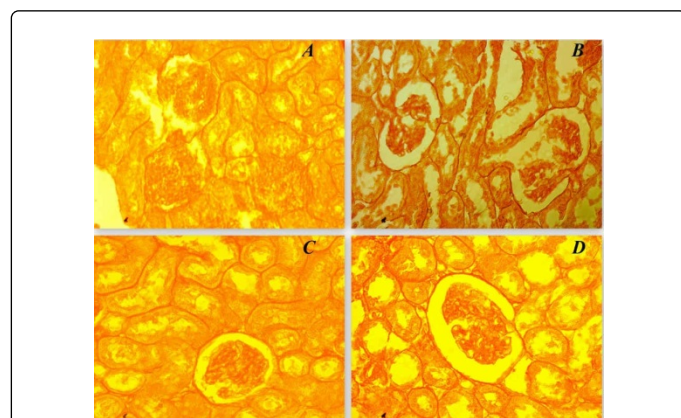


Figure 9: Sirius red staining showed fibrosis (Red color) in a kidney section of various groups. A represents control kidney, B represents control + *Syzygium cumini* kidney, C represents acetaminophen treated kidney and D represents acetaminophen + *Syzygium cumini* kidney. Magnification 40X was used.

Our study evaluated that supplementation of 1% *Syzygium cumini* seed increased SOD concentration even more than the control group. Another biological protecting enzyme, catalase [50] which generally breaks down H_2O_2 into water and neutralize the harmful activity of hydrogen peroxide [51] found lower once acetaminophen toxic group was treated with 1% *Syzygium cumini* seed (Figure 3).

In this present study, we have also measured some oxidative stress markers like MDA, NO and AOPP which generally are produced due to harmful free radical generation. Nitric oxide is a vasodilator which

also has a role for stimulation of several cellular growths. Free radicals often react with NOS and convert it to harmful reactive like iNOS or peroxynitrite which further damage cells membrane as well as genetic materials [11]. Overdose of acetaminophen often induces hepatic iNOS which explains hepatic damage [52].

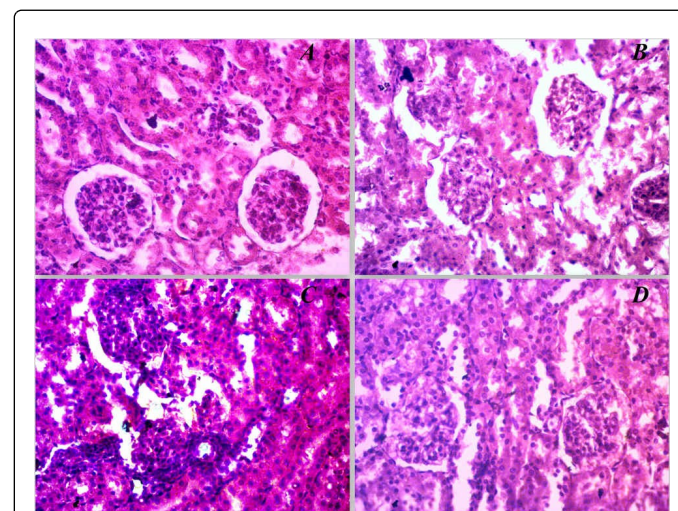


Figure 10: Hematoxylin and eosin staining showed inflammatory cell infiltration and necrosis in kidney of various groups. A represents control group, B represents control+ *Syzygium cumini* group, C represents acetaminophen treated group and D represents acetaminophen + *Syzygium cumini* group. Magnification 40X was used.

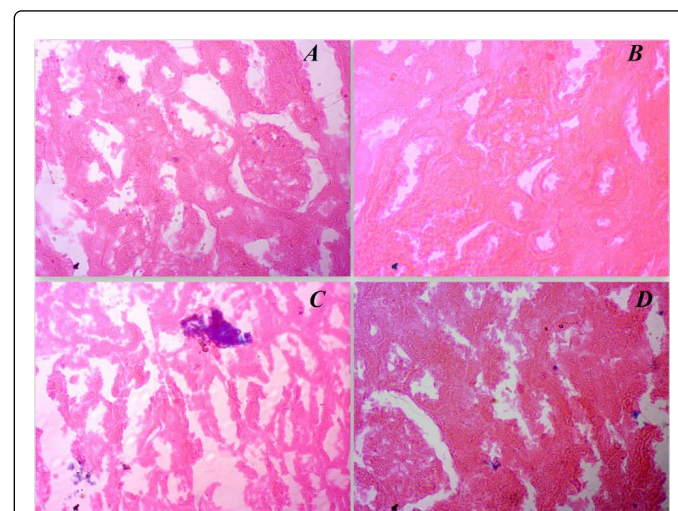


Figure 11: Prussian blue staining showed iron deposition in kidney sections of various groups. A represents control group, B represents control + *Syzygium cumini* group, C represents acetaminophen treated group and D represents acetaminophen+ *Syzygium cumini* group. Magnification 40X was used.

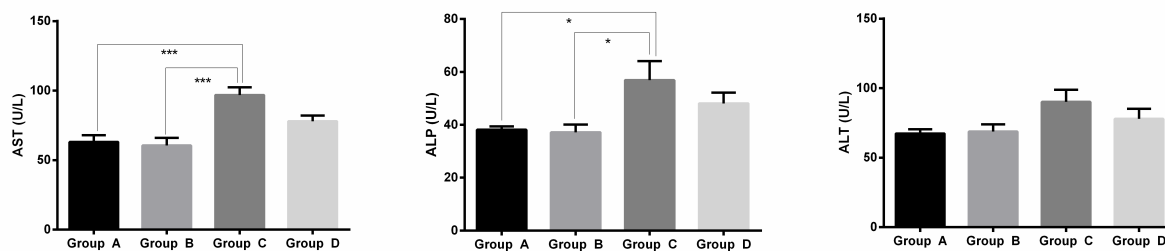


Figure 12: Effect of *Syzygium cumini* seed on various liver markers. Values are presented as mean \pm SEM. N=7-8 in each group or otherwise specified. One-way ANOVA with Bonferroni tests were done as post hoc test. Values are considered significance at $p < 0.05$.

We have observed that 1% seed supplement significantly reduced NO level when compared to diseased groups. Another oxidative stress parameter, MDA, which is the outcome from lipid peroxidation of poly unsaturated fatty acids that further damage cell membrane [41]. It was also noticed that MDA is often observed in acetaminophen toxicity [53,54]. Another oxidative stress marker advanced oxidation protein product, which is generally observed in acetaminophen induced injury. It was also observed that blockade of AOPP attenuates acetaminophen induced organ damages [55]. MDA and AOPP level have been found lowered when the rats were treated with 1% seed supplement (Figure 4).

Nevertheless, inflammatory cell infiltration also confirms tissue damage [12,56]. Our histology showed that acetaminophen overdose attracts inflammatory cell around the blood vessels and glomerulus of the disease group's tissue, on the other hand supplementation of the *Syzygium cumini* seed reduced inflammatory cell infiltration in both liver and kidney (Figures 6D and 9D). Similar kinds of findings have been also found from Awodele et al. and Sharma et al. [42,57]. Literatures also explored that once there is any necrosis or injury observed inside the organ, local fibroblast tissues are activated and secrete collagen as well as extracellular matrix [13], our study revealed that antioxidant property of *Syzygium cumini* seed significantly reduced fibrosis and collagen deposition (Figures 5D and 6D). Similar kind of attenuation was observed by Shoeib et al. and Leite et al. [58,59]. On the other hand, tissue iron is highly monitored and maintained by heme oxygenase (HO) which is often degraded by foreign harmful stimuli and initiate several types of dysfunctions like iron overload, hypertrophy and apoptosis (Figures 7A-7D) [10,60]. Our histology showed that massive amount of iron has been observed in both liver and kidney (Figures 8D and 11D) which were normalized by 1% *Syzygium cumini* seed supplement. This study also explored that 1% *Syzygium cumini* seed supplement neither interfered with plasma markers nor induced oxidative stress parameter, but improve antioxidant enzyme level when compared to control group.

Conclusion

In this study, we have investigated the role of *Syzygium cumini* seed on acetaminophen induced rat model. We assumed that the strong antioxidant property of *Syzygium cumini* seed might be able to protect liver and kidney function by reducing oxidative mediated dysfunctions. Our findings revealed that the content of GSH found improved in group D, notably GSH content observed higher than group A. Oxidative stress markers also notices to be reduced with

treatment. Similarly, plasma markers for both liver and kidney also observed lower. Finally, histology of our investigation showed lowering immune cell infiltration, fibrosis, and iron overload which is a clear scenario that our treatment protects both liver and kidney. This study also found out that antioxidant property of *Syzygium cumini* seed significantly reduced collagen secretion which might correlate with a molecular mechanism. Further study would be needed to elucidate the exact molecular mechanisms.

Author's Contributions

Md Ashraf Alam conceived the idea, designed the study and monitored all protocols for the study. Md Abu Taher Sagor and Nabila Tabassum carried out the animal study and performed biochemical assay. Md Mohabbulla Mohib and Ishfaq Ahmed analyzed all statistical analysis. Md Abu Taher Sagor and Md Ashraf Alam evaluated the histology. Md Abu Taher Sagor, Md Ashraf Alam, Hasan Mahmud Reza wrote the manuscript finalized the copy. All the authors have checked and approved the final manuscript.

Conflict of Interest

The authors declare no conflict of interest about this manuscript.

Acknowledgement

The authors are also thankful to the authority of Department of Pharmaceutical Sciences, North South University, Bangladesh for the providing us with excellent facilities for the present study.

References

1. Chalasani N (2012) The diagnosis and management of non-alcoholic fatty liver disease: Practice Guideline by the American Association for the Study of Liver Diseases, American College of Gastroenterology, and the American Gastroenterological Association. *Hepatology* 55: 2005-2023.
2. LaBrecque DR (2014) World Gastroenterology Organisation global guidelines: Nonalcoholic fatty liver disease and nonalcoholic steatohepatitis. *J Clin Gastroenterol* 48: 467-473.
3. Renzulli M, Golfieri R (2016) Proposal of a new diagnostic algorithm for hepatocellular carcinoma based on the Japanese guidelines but adapted to the Western world for patients under surveillance for chronic liver disease. *J Gastroenterol Hepatol* 31: 69-80.
4. Heron M (2012) Deaths: leading causes for 2009. *Natl Vital Stat Rep* 61: 1-94.

5. Renelus B, Foster T (2016) Noninvasive evaluation of nonalcoholic fatty liver disease. *Clinical Liver Disease* 7: 45-47.
6. Michaut A (2016) A cellular model to study druginduced liver injury in nonalcoholic fatty liver disease: Application to Acetaminophen. *Toxicology and Applied Pharmacology* 292: 40-55.
7. Ghabril M (2016) Amoxicillin–ClavulanateInduced Liver Injury. *Digestive Diseases and Sciences* pp: 1-11.
8. Nicoletti P (2016) HLADRB1* 16: 01DQB1* 05: 02 is a novel genetic risk factor for flupirtineinduced liver injury. *Pharmacogenet Genomics* 26: 218-224.
9. Lee WM (2003) Druginduced hepatotoxicity. *New England Journal of Medicine* 349: 474-485.
10. Reza HM, Sagor MAT, Alam MA (2015) Iron deposition causes oxidative stress, inflammation and fibrosis in carbon tetrachlorideinduced liver dysfunction in rats. *Bangladesh Journal of Pharmacology* 10: 152-159.
11. Chowdhury MRH (2015) Supplementation of Citrus maxima peel powder prevented oxidative stress, fibrosis and hepatic damage in carbon tetrachloride (CCl₄) treated rats. *EvidenceBased Complementary and Alternative Medicine* pp: 1-10.
12. Reza HM (2016) Angiotensinconverting enzyme inhibitor prevents oxidative stress, inflammation, and fibrosis in carbon tetrachloridetreated rat liver. *Toxicol Mech Methods* pp: 1-8.
13. Sagor AT (2015) Supplementation of fresh ucche (*Momordica charantia* L. var. *muricata* Willd) prevented oxidative stress, fibrosis and hepatic damage in CCl₄ treated rats. *BMC Complement Altern Med* 15: 115.
14. Sagor MAT (2015) *World Journal of Pharmaceutical Research*.
15. Savides MC, Oehme FW (1983) Acetaminophen and its toxicity. *J Appl Toxicol* 3: 96-111.
16. Zhao X (2012) Dioscin, a natural steroid saponin, shows remarkable protective effect against acetaminopheninduced liver damage in vitro and in vivo. *Toxicol Lett* 214: 69-80.
17. Nourjah P, Willey M (2002) Epidemiology of acetaminophenrelated overdose. Department of Health and Human Services. Center for Drug Evaluation and Research, Food and Drug Administration.
18. Mitchell J (1973) Acetaminopheninduced hepatic necrosis. I. Role of drug metabolism. *J Pharmacol Exp Ther* 187: 185-194.
19. Beger RD (2015) Translational biomarkers of acetaminopheninduced acute liver injury. *Arch Toxicol* 89: 1497-1522.
20. Slitt AML (2005) Effect of ribose cysteine pretreatment on hepatic and renal acetaminophen metabolite formation and glutathione depletion. *Basic Clin Pharmacol Toxicol* 96: 487-494.
21. Ni HM (2012) Activation of autophagy protects against acetaminophen-induced hepatotoxicity. *Hepatology* 55: 222-232.
22. Meyers LL (1988) Acetaminopheninduced inhibition of hepatic mitochondrial respiration in mice. *Toxicol Appl Pharmacol* 93: 378-387.
23. Domitrović R, Potočnjak I (2016) A comprehensive overview of hepatoprotective natural compounds: mechanism of action and clinical perspectives. *Arch Toxicol* 90: 39-79.
24. Sagor MAT (2015) Xanthine oxidase inhibitor, Allopurinol, prevented oxidative stress, fibrosis and myocardial damage in isoproterenol induced aged rats. *Oxid Med Cell Longev* pp: 1-9.
25. Bessems JG, Vermeulen NP (2001) Paracetamol (acetaminophen)induced toxicity: molecular and biochemical mechanisms, analogues and protective approaches. *Crit Rev Toxicol* 31: 55-138.
26. Ghosh J (2010) Acetaminophen induced renal injury via oxidative stress and TNF α production: Therapeutic potential of arjunolic acid. *Toxicology* 268: 8-18.
27. Ayyanar M, SubashBabu P, Ignacimuthu S (2013) *Syzygium cumini* (L.) Skeels., a novel therapeutic agent for diabetes: folk medicinal and pharmacological evidences. *Complement Ther Med* 21: 232-243.
28. Prabhakaran S, Gothandam K, Sivashanmugam K (2011) Phytochemical and antimicrobial properties of *Syzygium cumini* an ethnomedicinal plant of Javadhu hills. *Res Pharm* 1: 22-32.
29. Mohamed AA, Ali SI, ElBaz FK (2013) Antioxidant and antibacterial activities of crude extracts and essential oils of *Syzygium cumini* leaves. *Plos One* 8: e60269.
30. Baliga MS (2011) Phytochemistry, traditional uses and pharmacology of *Eugenia jambolana* Lam.(black plum): A review. *Food Res Int* 44: 1776-1789.
31. İçer M (2016) Is montelukast as effective as Nacetylcysteine in hepatic injury due to acetaminophen intoxication in rats? *Experimental and Toxicologic Pathology* 68: 55-59.
32. Yin H (2010) Lactoferrin protects against acetaminophen-induced liver injury in mice. *Hepatology* 51: 1007-1016.
33. Niehaus W, Samuelsson B (1968) Formation of malonaldehyde from phospholipid arachidonate during microsomal lipid peroxidation. *European Journal of Biochemistry* 6: 126-130.
34. Tracey WR, Tse J, Carter G (1995) Lipopolysaccharideinduced changes in plasma nitrite and nitrate concentrations in rats and mice: pharmacological evaluation of nitric oxide synthase inhibitors. *J Pharmacol Exp Ther* 272: 1011-1015.
35. WitkoSarsat V (1996) Advanced oxidation protein products as a novel marker of oxidative stress in uremia. *Kidney Int* 49: 1304-1313.
36. Tiwari BK (2014) Efficacy of Composite Extract from Leaves and Fruits of Medicinal Plants Used in Traditional Diabetic Therapy against Oxidative Stress in AlloxanInduced Diabetic Rats. *ISRN Pharmacol* 7.
37. Chance B, Maehly A (1955) Assay of catalases and peroxidases. *Methods Enzymol* 2: 764-775.
38. Khan RA (2012) Protective effects of *Sonchus asper* (L.) Hill, (Asteraceae) against CCl₄induced oxidative stress in the thyroid tissue of rats. *BMC Complement Altern Med* 12: 181.
39. Jollow DJ (1974) Bromobenzeneinduced liver necrosis. Protective role of glutathione and evidence for 3,4bromobenzene oxide as the hepatotoxic metabolite. *Pharmacology* 11: 151-169.
40. Ma L (2010) Oxidative stress in the brain of mice caused by translocated nanoparticulate TiO₂ delivered to the abdominal cavity. *Biomaterials* 31: 99-105.
41. Alam MA (2015) DPP4 inhibitor sitagliptin prevents inflammation and oxidative stress of heart and kidney in two kidney and one clip (2K1C) rats. *Diabetol Metab Syndr* 7: 1-10.
42. Awodele O (2016) Modulatory potentials of aqueous leaf and unripe fruit extracts of *Carica papaya* Linn.(Caricaceae) against carbon tetrachloride and acetaminopheninduced hepatotoxicity in rats. *J Intercult Ethnopharmacol* 5: 27.
43. Ogonovszky H (2005) The effects of moderate, strenuous, and overtraining on oxidative stress markers and DNA repair in rat liver. *Can J Appl Physiol* 30: 186-195.
44. Davidson KT, Zhu Z, Fang Y (2016) Phytochemicals in the Fight Against Cancer. *Pathology & Oncology Research* pp: 1-6.
45. Rule AD (2013) Estimating the glomerular filtration rate from serum creatinine is better than from cystatin C for evaluating risk factors associated with chronic kidney disease. *Kidney international* 83: 1169-1176.
46. Newton JF (1986) Metabolism and excretion of a glutathione conjugate of acetaminophen in the isolated perfused rat kidney. *Journal of Pharmacology and Experimental Therapeutics* 237: 519-524.
47. Sies H, Wendel A (2012) Functions of glutathione in liver and kidney: Springer Science & Business Media.
48. Halliwell B, Gutteridge JM (2015) Free radicals in biology and medicine: Oxford University Press, USA.
49. Sabina EP (2013) Hepatoprotective and antioxidant potential of *Withania somnifera* against paracetamolinduced liver damage in rats. *Int J Pharm Pharm Sci* 5: 648-651.
50. Gutierrez J, BarryRyan C, Bourke P (2008) The antimicrobial efficacy of plant essential oil combinations and interactions with food ingredients. *Int J Food Microbiol* 124: 91-97.

51. Rahim SM (2014) Hepatoprotective Effect Of Cymbopogon Citratus Aqueous Extract Against Hydrogen Peroxide Induced Liver Injury In Male Rats. *Afr J Tradit Complement Altern Med* 11: 447-451.
52. James LP, Mayeux PR, Hinson JA (2003) Acetaminophen induced hepatotoxicity. *Drug Metab Dispos* 31: 1499-1506.
53. Ahmed MB, Khater MR (2001) Evaluation of the protective potential of *Ambrosia maritima* extract on acetaminophen induced liver damage. *J Ethnopharmacol* 75: 169-174.
54. Sabbani PK (2016) Evaluation of Hepatoprotective Activity with different Fractions of *Gardenia gummifera* Linn. on Paracetamol Induced Liver Damage in Rats. *J Drug Metab Toxicol* 7: 1-7.
55. Ekong U (2006) Blockade of the receptor for advanced glycation end products attenuates acetaminophen-induced hepatotoxicity in mice. *J Gastroenterol Hepatol* 21: 682-688.
56. Mohib M Md, Hasan I, Chowdhury WH (2016) Role of Angiotensin II in Hepatic Inflammation through MAPK Pathway: A Review. *J Hep* 2: 2.
57. Sharma B (2013) Liver protective effects of aqueous extract of *Syzygium cumini* in Swiss albino mice on alloxan induced diabetes mellitus. *Journal of pharmacy research* 6: 853-858.
58. Shoeb AM, Said E, Ammar EM (2015) Cytoprotective potential of tiron and methyl palmitate against acetaminophen induced acute liver injury. *Can J Physiol Pharmacol* 94: 1-8.
59. Leite SB (2016) Novel human hepatic organoid model enables testing of drug induced liver fibrosis in vitro. *Biomaterials* 78: 1-10.
60. Darwish SF (2015) Antifibrotic mechanism of deferoxamine in concanavalin A induced liver fibrosis: Impact on interferon therapy. *Biochem Pharmacol* 98: 231-242.