

## Folding Back of Central Venous Catheter in the Internal Jugular Vein: Methods to Diagnose it at the Time of Insertion?

Amitabh Kumar\*

Department of Anaesthesia, VMMC and Safdarjung Hospital, New Delhi, India

The central venous pressure (CVP) monitoring is a useful tool for assessment of the status of intravascular volume. Of the tip of the central venous catheter often leads to erroneous measurement, leading to an incorrect volume replacement and other serious complications, like cardiac tamponade or dysrhythmias, caused by the interaction with the wall of the vessel or the endocardium [1-3].

We report a case of folding of central venous catheter (CVC) in the right internal jugular vein, which resulted in false measurement of CVP. A 50 yr, old 46kg male with diagnosis of perforation peritonitis was scheduled for emergency laparotomy. Under all aseptic precautions a 7Fr triple lumen (VenX™, B L Lifesciences Pvt Ltd, India), CVC was inserted in the right internal jugular vein (IJV) and fixed at 10 cm mark and free flow of blood was obtained from the proximal, medial and distal ports and the distal port was connected to the transducer. The central venous pressure tracing was normal, but the measurements remained low that is CVP=4. Resuscitation with 1 liter of normal saline was done. The measurement still did not increase, but the heart rate and blood pressure were stable. Intraoperative the patient remained haemodynamically stable. He was shifted to the ICU on ventilator for further management.

On chest roentgenogram, CVC was found to be folded up inside the right IJV (Figure 1). Under all aseptic precautions, it was removed

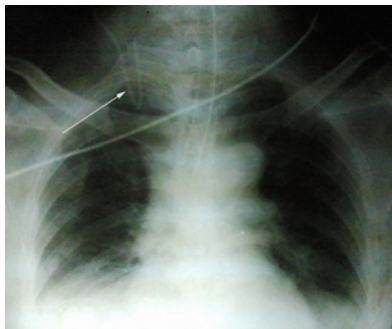


Figure 1:

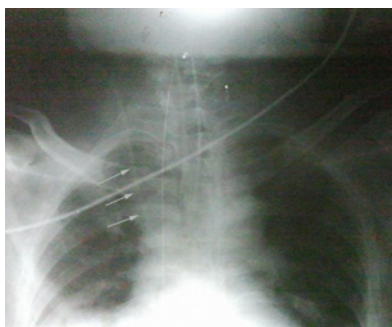

Figure 2:

and another catheter was inserted in the same vein (Figure 2). Patient was in sepsis and developed multiple-organ dysfunction. We were planning to do a Magnetic Resonance Angiography to delineate the anatomy of internal jugular vein but patient's unstable condition did not allow the same. He did not respond to the standard treatment and could not survive.

The monitoring of CVP is useful for monitoring, fluid resuscitation and inotropic drugs administration. Numerous complications associated with CVC insertion are arterial puncture, pneumothorax, haematoma formation, laceration of the thyrocervical trunk and carotid-jugular fistula. The correct position of the tip of CVC should be in the superior vena cava, above the level of pericardial reflection to obtain true CVP measurements [4]. It is recommended that catheter tip should be at the carina and in the long axis of the superior vena cava; without acute abutment to the vein wall [1,4]. An angle greater than 40 degrees can cause perforation of wall of the blood vessel [4].

Different landmarks, Peres formula [height (cm)/10] [2], right atrial ECG [3] and Transesophageal Echocardiography [5] have been used to ensure the correct placement of CVC. In intra-atrial ECG technique, the intra-atrial positioning of the tip of the CVC is detected by configuration of P wave on ECG, which initially increases in amplitude on advancement and becomes bifid when inside the right atrium and then withdrawn back to get a normal configuration P wave which indicates optimal position of the tip of the CVC [3]. Malpositioning of the CVC tip can occur during removal of the guide wire, shifting of the patient or even spontaneous migration of the catheter to the left or right mammary vein during mechanical ventilation [6], due to pressure changes in the thorax [7]. A similar case of folding back of the catheter in the superior vena cava has been reported [8].

To conclude, we should ensure the correct placement of the CVC tip during insertion. Since, it is not possible to get chest x-rays with fluoroscopy done immediately or after insertion; we should use intra-atrial ECG technique to ensure that tip is correctly placed.

### References

1. Sivasubramanian S, Hiremath M (2008) Central venous catheters: Do we need to review practice on positioning? J Intensive Care Society 9: 228-231.
2. Peres PW (1990) Positioning central venous catheters-a prospective survey. Anaesth Intensive Care 18: 536-539.

\*Corresponding author: Dr. Amitabh Kumar, Senior Resident, Department of Anaesthesia, VMMC and Safdarjung Hospital, New Delhi, India, E-mail: [dramitabhkumar1980@gmail.com](mailto:dramitabhkumar1980@gmail.com)

Received July 05, 2012; Accepted July 25, 2012; Published July 29, 2012

Citation: Kumar A (2012) Folding Back of Central Venous Catheter in the Internal Jugular Vein: Methods to Diagnose it at the Time of Insertion? J Anesth Clin Res 3:226. doi:10.4172/2155-6148.1000226

Copyright: © 2012 Kumar A. This is an open-access article distributed under the terms of the Creative Commons Attribution License, which permits unrestricted use, distribution, and reproduction in any medium, provided the original author and source are credited.

3. Joshi AM, Bhosale GP, Parikh GP, Shah VR (2008) Optimal positioning of right sided internal jugular venous catheters: comparison of intra-atrial electrocardiography versus Peres' formula. Indian J Crit Care Med 12: 10-14.
4. Stonelake PA, Bodenham AR (2006) The carina as a radiological landmark for central venous catheter tip position. Br J Anaesth 96: 335-340.
5. Jeon Y, Ryu HG, Yoon SZ, Kim JH, Bahk JH (2006) Transesophageal echocardiographic evaluation of ECG-guided central venous catheter placement. Can J Anaesth 53: 978-983.
6. Ghafoor H, FatimiSh, Ali M (2011) Unusual malposition of dialysis catheter in the left internal mammary vein--a case report. Middle East J Anesthesiol 21: 139-141.
7. Rasuli P, Hammond DI, Peterkin IR (1992) Spontaneous intrajugular migration of long term central venous access catheters. Radiology 182: 822-824.
8. Agrawal P, Gupta B, D'Souza N (2010) Coiled central venous catheter in superior vena cava. Indian J Anaesth 54: 351-352.