

Floppy Infant with Respiratory Failure: A Case of Infantile Polymyositis

Premlatha R¹, Divya S^{1*} and Gayathri N²

¹Department of Pediatrics, Bangalore Medical College and Research Institute, India

²Department of Neuropathology, National Institute of Mental Health and Neurosciences, India

*Corresponding author: Divya Subburaj, Department of Paediatrics, Bangalore Medical College and Research Institute, G-101 Mantri Terrace, Behind Rankacolony, Bannerghatta Road, Bilkehalli Post, Bangalore 560076, India, Tel: 9986207866; E-mail: divyanls@yahoo.co.in

Received date: Mar 01, 2017; Accepted date: Mar 20, 2017; Published date: Mar 22, 2017

Copyright: © 2017 Premlatha R, et al. This is an open-access article distributed under the terms of the Creative Commons Attribution License, which permits unrestricted use, distribution and reproduction in any medium, provided the original author and source are credited.

Abstract

An eleven month old infant presented with progressive proximal muscle weakness, hypotonia and elevated creatinekinase. Muscle biopsy showed inflammatory changes suggestive of polymyositis. Infantile polymyositis, an inflammatory myopathy affecting children under 1 year of age is a rare disorder but potentially treatable. Early diagnosis is crucial for better outcome.

Keywords: Infantile polymyositis; Respiratory failure; Steroids; Treatable

Introduction

Inflammatory myopathies are heterogenous group of skeletal muscle diseases with onset ranging from infancy to adulthood. Three distinct groups: dermatomyositis, polymyositis and sporadic inclusion body myositis are defined [1,2]. Polymyositis affects predominantly adults but rarely children and infants. A few case reports on infantile polymyositis [3-5], clinically presenting with moderate to severe muscle weakness, generalised hypotonia, with elevated serum creatine kinase (CK) activity, myopathic electromyography changes and inflammatory cell infiltrates on muscle biopsy have been reported. In this report we describe a floppy child with respiratory failure, elevated CK and muscle biopsy showing features of polymyositis.

Infantile polymyositis needs to be distinguished from inherited myopathies like infantile spinal muscular atrophy, myotonia congenita and congenital myopathies as there is some benefit from corticosteroid treatment.

Case Presentation

An eleven month old male infant born at term with uneventful antenatal period and birth weight of 2.5 kg presented to us at 11 months age with loss of developmental milestones. He was second born to non-consanguineously married healthy parents. There was no family history suggestive of similar illness. He had achieved developmental milestones appropriate for his age. At 7 months of age he was sitting without support, reaching for his toys and uttering monosyllables. At 8 months of age his parents found him to be floppy with poor head control and by 11 months there was complete loss of head control. It was associated with progressive weakness of proximal muscles. By 11 months child was not able to sit with support or roll over. He had lost the ability to vocalise and had a weak cry.

On examination, child was alert and tracking objects visually. His weight, height and head circumference was 11 kg (85th-97th centile), 79 cm (85th-97th centile) and 43 cm (15th-50th centile) respectively. He had tachypnea with paradoxical breathing pattern. As his

respiratory efforts were getting weaker and he had hypoxemia on arterial blood gas analysis, he was intubated and supported with mechanical ventilation. Child had generalised hypotonia with no significant muscle atrophy. There was predominant proximal muscle weakness in upper and lower extremities, neck and abdominal muscle groups. Deep tendon reflexes were diminished. However, facial muscle involvement was not observed and skin was normal. Biochemical investigations showed elevated serum creatine kinase 948 U/L (25-200 U/L). Magnetic resonance (MR) imaging of the brain was normal.

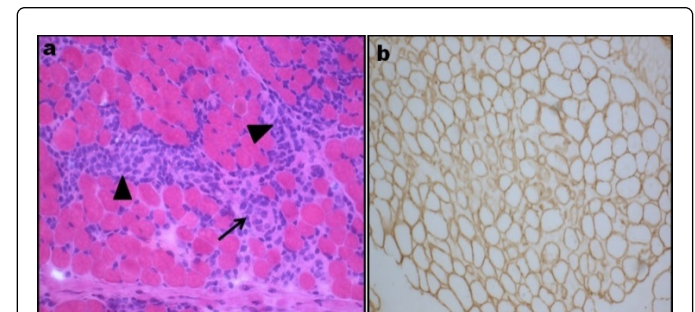


Figure 1: Transversely cut skeletal muscle tissue showing; **a.** Rounding of fibers, variation in diameter myophagocytosis (arrow) and dense interstitial inflammation (arrow head) HE X250; **b.** Immunostaining to monoclonal antibodies against merosin shows labeling along the membrane in all the fibers Merosin X250.

Electromyography of tibialis anterior and biceps muscle was normal. A muscle biopsy obtained from left biceps brachii was subjected to routine battery of stains. A fragment of the muscle flash frozen in isopentane precooled in liquid nitrogen was used for cryosections stained for Succinic dehydrogenase, Nicotinamide adenine dinucleotide tetrazolium reductase, Adenosine triphosphatase pH 9.4, 4,6, Haematoxylin eosin and Modified Gomori's Trichrome. Immunostaining on cryosections to monoclonal antibodies against dystrophin, alpha-sarcoglycan and merosin as primary and HRP tagged secondary antibody was carried. Histologically, muscle biopsy revealed occasional myophagocytosis, dense interstitial, endo and perimyseal lympho mononuclear cells involving small and medium

sized vessels with transmural infiltrates (Figure 1) suggestive of polymyositis. Immunostaining against dystrophin, alpha-sarcoglycan and merosin showed positive labelling in all the myofibers, thus ruling out the diagnosis of Duchenne muscular dystrophy, alpha-sarcoglycanopathy and merosinopathy.

Diagnosis of polymyositis was arrived on the basis of the above findings. He was treated with intravenous pulse methyl prednisolone for 5 days, followed by oral prednisolone of 1 mg/kg/day. Child couldn't be weaned off the ventilator as there was no significant improvement in respiratory efforts. He also needed inotropic support due to deteriorating cardiac function. A week later he died of progressive cardio-respiratory failure.

Discussion

Infantile polymyositis is a rare and a poorly defined entity. Sripathi et al. proposed the following major diagnostic criteria for acquired infantile inflammatory myopathy [1].

1. Lack of family history.
2. Normal early post natal development.
3. Muscle weakness predominantly involving neck and proximal limb muscles.
4. No involvement of CNS.
5. Elevated serum creatine kinase activity.
6. Lymphocytic inflammation on muscle biopsy.
7. Abnormal myonuclei.
8. Normal dystrophin and merosin profile.

These major criteria distinguish this entity from other infantile neuromuscular diseases including spinal muscular atrophy, congenital muscular dystrophy [3].

Clinical findings of infantile spinal muscular atrophy include generalised hypotonia, delayed motor development with proximal muscle weakness but biopsy do not show inflammatory changes [6]. While, early onset dystrophy like merosinopathies manifest with hypotonia, multiple contractures and associated white matter changes on cranial MR. Biopsy reveals inflammatory cells with absence of merosin. Inflammatory cells may be present in other type of dystrophies particularly infantile fascio-scapulo-humeral dystrophy, where facial diplegia is seen predominantly with other proximal

muscle weakness [7,8]. However these clinical features were not noted in the present case.

Thompson et al. put forth the following criteria for pure polymyositis progressive proximal muscle weakness or diffuse weakness at birth, specific biopsy changes, serum enzyme elevation and most importantly a therapeutic response to steroids [4]. Usually respiratory failure occurs in 2% of cases of polymyositis and patients in terminal stages with a more generalised disease are unresponsive to steroids [6]. In our case, probably the subacute nature of progression and initiation of steroids in the terminal stage, after onset of respiratory failure resulted in therapeutic unresponsiveness.

The diagnosis of infantile polymyositis should be considered in a floppy infant with proximal muscle weakness predominantly involving neck flexors, with elevated serum CK and inflammatory cell infiltrates on muscle biopsy. These children should receive a trial of steroids early.

Conclusion

Infantile polymyositis is a potentially treatable condition is rarely diagnosed. An early diagnosis is crucial for a better outcome.

References

1. Karpati G, Hilton-Jones D, Griggs RC (2001) Disorders of voluntary muscle (7th edn). Cambridge University Press, UK.
2. Vajsar J, Jay V, Babyn P (1996) Infantile myositis presenting in neonatal period. *Brain Dev* 18: 415-419.
3. Sripathi N, Karpati G, Carpenter S (1996) A distinctive type of infantile inflammatory myopathy with abnormal myonuclei. *J Neurol Sci* 136: 47-53.
4. Thompson CE (1982) Infantile myositis. *Develop Med Child Neurol* 24: 307-313.
5. Tutuncuoglu S, Tekgul H, Demirtas E, Uysal S (1997) Infantile polymyositis with normal serum creatine kinase level. *Brain Dev* 19: 63-65.
6. Blumberg PC, Byrne E, Kakulas BO (1984) Polymyositis presenting with respiratory failure. *J Neurol Sci* 65: 221-229.
7. Nagai T, Hasegawa T, Saito M, Hayashi S, Nonaka I (1992) Infantile polymyositis: A case report. *Brain Dev* 14: 167-169.
8. Matsubara S, Hirai S, Sawa Y (1997) Pulsed intravenous methyl prednisolone therapy for inflammatory myopathies: Evaluation of the effect by comparing two consecutive biopsies from the same muscle. *J Neuroimmunol* 76: 75-80.