

Fistula after a Left Colectomy- a Simple Suture and Drainage Can Be an Option?

Sorin Cimpean, Arianna Grilli Mattia Bez, Marechal Marie Therese, Benjamin Cadiere, Luca Pau, Guy Bernard Cadiere

Department of Surgery, Saint Pierre University Hospital, Brussels

Corresponding author: Sorin Cimpean, Department of Surgery, Saint Pierre University Hospital, Yvoir, Brussels; Tel: +3281422111; E-mail: sorin.campean_md@yahoo.com

Received date: December 18, 2019; **Accepted date:** December 24, 2019; **Published date:** December 31, 2019

Copyright: © 2019 Cimpean S. This is an open-access article distributed under the terms of the Creative Commons Attribution License, which permits unrestricted use, distribution, and reproduction in any medium, provided the original author and source are credited.

Abstract

Anastomotic leak is a frequent complication in general surgery which is related to significant morbidity and mortality. Nowadays, several approaches are utilized, frequently invasive for the patient. Nevertheless, a common strategy for anastomotic leak management has not been identified. We report here an alternative surgical procedure, associated to reduced interventional time and less invasively for the patient.

Keywords Colorectal; Fistula; Hartmann's procedure; Hemicolectomy

Introduction

Despite advances in modern colorectal surgery, anastomotic leak of colorectal or coloanal anastomosis, cause significant morbidity and mortality. However, there is no consensus on the management of colorectal anastomotic leak. Currently operative procedures in case of fistula can vary from simple suture with drainage to resection of the anastomosis and closure of the rectal stump with end colostomy (Hartmann's procedure).

We report a simple suture and pelvic drainage of an anastomotic fistula after a left laparoscopic colectomy for diverticular colic disease with a uneventful postoperative course.

Case Presentation

A 40-years old patient, who had a laparoscopic left hemicolectomy for sigmoidal diverticulosis 14 days before, presented at the emergency room for diffuse abdominal pain more important on the pelvis area, nausea and vomit. Clinical abdominal examination revealed signs of parietal defense, positive Blumberg sign and no peristalsis. The vital parameters were normal. The laboratory count revealed: CRP 18 mg/L (normal < 5 mg/L). An abdominal CT scan showed moderate inflammation of the peri-anastomotic area with some extra digestive air bubbles without collection at this level.

We decided then to perform an explorative laparoscopy under general anesthesia. Four trocars were placed: one of 12 mm in umbilical position and three of 5 mm in right iliac fossa, right and left flank. During explorative procedure, we noticed a posterior small abscess and a posterior anastomotic dehiscence of the anastomosis on the posterior side evaluated at < 5 mm. (Figure 1 and 2). We closed the dehiscence with an X point with a silk suture. Peritoneal cavity was washed and two drainages were positioned: next to the fistula suture and one in Douglas space. The patient was discharged after a rapid recovery of the intestinal function and did not presented any further complication.

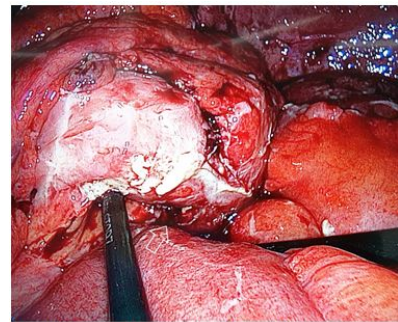


Figure 1: Intraoperative image- minimal contamination of the peritoneal cavity.

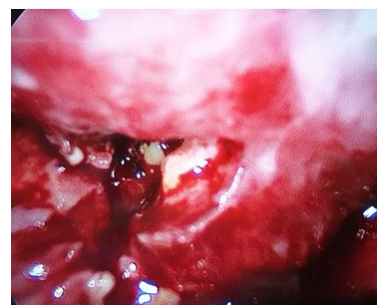

Figure 2: Intraoperative image- direct visualization of the fistula.

Discussion

The risk of colonic anastomotic leak ranges between 1.5% and 23%, increasing for low colorectal and coloanal anastomoses. The presentation can be widely variable, as is its definition. Some patients present with sepsis and peritonitis while others have a more insidious course with fever, leukocytosis and abdominal pain [1-5].

Murray et al evaluated the association between laparoscopic and open approaches on leak rate. The overall leak rate was 3.4%; 2.8% in the laparoscopic group and 4.5% in the open group. Two randomized trials, however, did not show a difference in leak rates between laparoscopic and open procedures, although surgeons were likely earlier in their laparoscopic learning curve in those series.

Multitudes of risk factors for anastomotic leak have been described in the literature. The location of the anastomosis, defined as intraperitoneal versus under-peritoneal, has been shown to be directly related to the risk of leak: more distal anastomoses had higher leak rates and particularly ultralow or coloanal anastomoses had the highest leak rate (8%) [6]. A retrospective review of 382 patients undergoing colorectal resection evaluated the impact of the number of staple fires required for rectal division on leak rates and particularly three or more stapler loads were associated to an increased risk [7].

Individuals' factors have been also identified as risk factors for anastomotic leak. Several large, retrospective studies have described modifiable and non-modifiable patients factors possibly related to increased risk of anastomotic leak including diabetes, young age, smoking, anemia, neoadjuvant radiation, increased operative time and emergency surgery [8,9].

The management has changed over the past several decades and many new techniques are now available, with the goal of preservation of the anastomosis and restoration of gastrointestinal continuity with good functional recovery. Traditionally, the treatment of choice for a leaking colorectal or coloanal anastomosis is the Hartmann's procedure, consisting in the resection of the anastomosis with exteriorization of the proximal limb as an end colostomy [10].

Techniques like complete mobilization of the left colon (takedown of the splenic flexure) and performing appropriate vascular ligation (high ligation of the inferior mesenteric artery and vein) for a tension-free anastomosis are recommended [11,12].

In our case we decided to apply a stitch considering the small dimensions of the anastomotic leak, the localized peritonitis and the young age of the patient. We think that if there is a chance of minimal invasive treatment for selected patients, this might be an option, and can give the possibility of avoiding a colostomy.

Conclusion

Anastomotic leak is a classic complication in colo-rectal surgery, causing significant morbidity and mortality. We report a surgical

option that can be an option for selected patients and which is an alternative to classical technique. The feasibility of this technique must be confirmed in larger series of patients.

References

1. Soeters PB, de Zoete JP, Dejong CH, Williams NS, Baeten CG (2002) Colorectal surgery and anastomotic leakage. *Dig Surg* 19: 150-155.
2. Blumetti J, Chaudhry V, Cintron JR, Park JJ, Marecik S et al. (2014) Management of anastomotic leak: Lessons learned from a large colon and rectal surgery training program. *World J Surg* 38: 985-991.
3. Chopra SS, Mrak K, Hünerbein M (2009) The effect of endoscopic treatment on healing of anastomotic leaks after anterior resection of rectal cancer. *Surgery* 145: 182-188.
4. Mees ST, Palmes D, Mennigen R, Senninger N, Haier J et al. (2008) Endo-vacuum assisted closure treatment for rectal anastomotic insufficiency. *Dis Colon Rectum* 51: 404-410.
5. Vermeer TA, Orsini RG, Daams F, Nieuwenhuijzen GA, Rutten HJ (2014) Anastomotic leakage and presacral abscess formation after locally advanced rectal cancer surgery: Incidence, risk factors and treatment. *Eur J Surg Oncol* 40: 1502-1509.
6. Platell C, Barwood N, Dorfmann G, Makin G. (2007) The incidence of anastomotic leaks in patients undergoing colorectal surgery. *Colorectal Dis* 9:71 - 79.
7. Braunschmid T, Hartig N, Baumann L, Dauser B, Herbst F (2017) Influence of multiple stapler firings used for rectal division on colorectal anastomotic leak rate. *Surg Endosc* 31:5318 - 5326.
8. Parthasarathy M, Greensmith M, Bowers D, Groot-Wassink T (2017) Risk factors for anastomotic leakage after colorectal resection: A retrospective analysis of 17 518 patients. *Colorectal Dis* 19:288 - 298.
9. Van Rooijen SJ, Huisman D, Stuijvenberg M (2016) Intraoperative modifiable risk factors of colorectal anastomotic leakage: Why surgeons and anesthesiologists should act together. *Int J Surg* 36:183 - 200.
10. Weidenhagen R, Gruetzner KU, Wiecken T, Spelsberg F, Jauch KW (2008) Endoscopic vacuum-assisted closure of anastomotic leakage following anterior resection of the rectum: a new method. *Surg Endosc* 22: 1818-1825.
11. Murray AC, Chiuzan C, Kiran RP (2016) Risk of anastomotic leak after laparoscopic versus open colectomy. *Surg Endosc* 30:5275 - 5282.
12. Blumetti J, Abcarian H (2015) Management of low colorectal anastomotic leak: Preserving the anastomosis. *World J Gastrointest Surg* 7: 378-383.