

# Excellent Outcome of Concomitant Intensive Immunosuppression and Eculizumab in Aplastic Anemia/Paroxysmal Nocturnal Hemoglobinuria Syndrome

Serena Marotta, Giovanna Giagnuolo, Santina Basile, Simona Pagliuca, Francesco Grimaldi, Fabrizio Pane and Antonio Maria Risitano\*

Department of Clinical Medicine and Surgery, Federico II University of Naples, Via Pansini 5, 80131 Naples, Italy

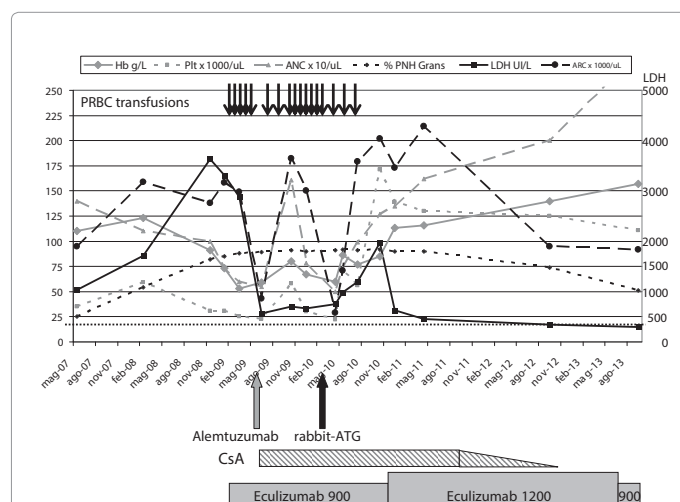
Dear Editor:

Paroxysmal Nocturnal Hemoglobinuria (PNH) is characterized by complement-mediated intravascular hemolysis, thrombophilia and Aplastic Anemia (AA) [1,2]. The treatment of PNH has been rebuilt by the anti-C5 eculizumab, which results in transfusion independence in half of the patients [3,4], while the others remain severely anemic due C3-mediated extravascular hemolysis [5] and/or concomitant AA.

A 21 year men was referred to our Institution in 2007 for mild cytopenia and laboratory signs of hemolysis (Figure 1); based on flow cytometry, the diagnosis of PNH in the context of moderate AA was made. The patient did not receive any etiologic treatment until March

2009, when he started eculizumab because of severe anemia due to overt symptomatic hemolysis. The patient had no benefit from anti-complement treatment, with increasing transfusional need; after 3 months, the diagnosis of severe AA was documented. In absence of a suitable donor, Immunosuppressive Treatment (IST) was chosen as etiologic treatment [6]; the patients was enrolled in the trial NCT00895739 [7], which investigated the anti-CD52 alemtuzumab and cyclosporine A (CyA) as an alternative IST for AA. Given the persistent major PNH population, we decided to not discontinue eculizumab to minimize the risk of massive intravascular hemolysis and possible thrombotic complications. Alemtuzumab was administered subcutaneously (3-10-30-30 mg in 4 consecutive days), without relevant side effect. Irrespective of eculizumab, immediate and profound lymphocytopenia (absolute lymphocyte count <50/μL) was observed, as in patients not receiving alemtuzumab [7]. The IST resulted in a substantial increase of neutrophil, reticulocyte and platelet counts, with the best hematological response achieved at 4 months from treatment. Unfortunately, in the following months, irrespective of chronic CyA maintenance, blood counts felt down, thus the relapse of SAA prompted us to consider a second-line treatment. Given that the best unrelated donor was 5/6 HLA matched, we opted for a second course of IST using the rabbit Anti-Thymocyte Globuline (r-ATG) associated with CyA. The treatment was completed as scheduled (3.75 mg/kg for 5 days) without any side effect, and again lymphocyte depletion was observed irrespective of continuous eculizumab treatment. After this second IST the patient experienced progressive improvement of his blood counts, finally resulting in complete response (Figure 1). Notably, reappearance of intravascular hemolysis required transient increase of eculizumab dosage; with the progressive reduction of the PNH population, eculizumab was tapered to the standard dosage. The patient now shows normal blood counts, in absence of maintenance CyA treatment and without any sign or symptom of hemolysis.

The occurrence of severe AA is a possible event during the course of PNH [2] and eventually hampers the hematological benefit from eculizumab. Treatment options include IST or Bone Marrow Transplantation (BMT) [6]. Here we provide evidence that intensive IST based on either polyclonal or monoclonal anti-lymphocyte antibodies can be delivered even concomitantly to eculizumab treatment, without



**Figure 1: Clinical and laboratory course of the patient affected by AA/PNH syndrome**

The figure summarizes blood counts and other clinical parameter over a disease course of more than 6 years. At disease presentation the patient had moderate hemolysis (LDH ≈1,000 IU/L) with moderate cytopenia (mostly neutropenia and thrombocytopenia). Two years later Hb level dropped down due to overt hemolysis (LDH >3,000 IU/L), with persistent moderate neutropenia and thrombocytopenia. Eculizumab treatment resulted in prompt LDH reduction, without improvement on anemia (the patient rather became transfusion dependent). At the same time all blood counts worsened (platelets, neutrophils and reticulocytes) and the diagnosis of severe AA was made (with a persistent large PNH population). First IST course by alemtuzumab resulted in a transient improvement of blood counts, with persistent transfusion dependence; after the second IST course by ATG all blood counts slowly improved, eventually becoming normal, without any need of additional transfusion and progressive resolution of anemia. At this time, also PNH population was decreasing in its percentage, allowing the reduction of eculizumab at the standard dosage (a transient increase to 1,200 mg every other week was needed due to breakthrough intravascular hemolysis). Hemoglobin (Hb, g/L, continuous gray line); absolute neutrophil count (ANC x 10/μL, small dashed gray line); platelet count (Plt x 1,000/μL, large dashed gray line); lactate dehydrogenase (LDH, IU/L, continuous black line); the fine dashed line represents the upper normal limit, 450 IU/L; PNH granulocyte population (% of PNH Grans, small dashed black line); absolute reticulocyte count (ARC x 1,000/μL, large dashed black line); transfusional requirement (each gray arrow on the top represent 2 units of packer red blood cell unit, PRBC); immunosuppressive treatment (big grey and black arrows represent alemtuzumab and rabbit-ATG, respectively; cyclosporine A is depicted as gray-striped box); anti-complement treatment (gray box, height represent the dosage).

**\*Corresponding author:** Antonio Maria Risitano, Hematology, Department of Clinical Medicine and Surgery, Federico II University of Naples, Via Pansini 5, 80131 Naples, Italy, Tel: +39 081 746 2111-2037; Fax +39 081 746 4728 ; E-mail: [amrisita@unina.it](mailto:amrisita@unina.it)

**Received** January 05, 2014; **Accepted** January 20, 2014; **Published** January 22, 2014

**Citation:** Marotta S, Giagnuolo G, Basile S, Pagliuca S, Grimaldi F, et al. (2014) Excellent Outcome of Concomitant Intensive Immunosuppression and Eculizumab in Aplastic Anemia/Paroxysmal Nocturnal Hemoglobinuria Syndrome. J Hematol Thromb Dis 2: 128. doi: [10.4172/2329-8790.1000128](https://doi.org/10.4172/2329-8790.1000128)

**Copyright:** © 2014 Marotta S, et al. This is an open-access article distributed under the terms of the Creative Commons Attribution License, which permits unrestricted use, distribution, and reproduction in any medium, provided the original author and source are credited.

any side effect or pharmacological interference. Our observation is the first proof, in vivo, that the terminal effector complement, namely the membrane attack complex, is not needed for the lympholytic effect of both thymoglobuline and alemtuzumab, suggesting a major role for antibody-dependent cellular cytotoxicity or even programmed cell death, rather than complement-dependent cytotoxicity [8]. On the other hand, our patient demonstrates that intensive IST, even combined with eculizumab, is a worth treatment option for AA/PNH syndrome, possibly resulting in excellent clinical outcome.

## References

1. Risitano AM (2012) Paroxysmal Nocturnal Hemoglobinuria. *Anemia*: InTech.
2. de Latour RP, Mary JY, Salanoubat C, Terriou L, Etienne G, et al. (2008) Paroxysmal nocturnal hemoglobinuria: natural history of disease subcategories. *Blood* 112: 3099-3106.
3. Brodsky RA, Young NS, Antonioli E, Risitano AM, Schrezenmeier H, et al. (2008) Multicenter phase 3 study of the complement inhibitor eculizumab for the treatment of patients with paroxysmal nocturnal hemoglobinuria. *Blood* 111: 1840-1847.
4. Hillmen P, Young NS, Schubert J, Brodsky RA, Socié G, et al. (2006) The complement inhibitor eculizumab in paroxysmal nocturnal hemoglobinuria. *N Engl J Med* 355: 1233-1243.
5. Risitano AM, Notaro R, Marando L, Serio B, Ranaldi D, et al. (2009) Complement fraction 3 binding on erythrocytes as additional mechanism of disease in paroxysmal nocturnal hemoglobinuria patients treated by eculizumab. *Blood* 113: 4094-4100.
6. Marsh JC, Ball SE, Cavenagh J, Darbyshire P, Dokal I, et al. (2009) Guidelines for the diagnosis and management of aplastic anaemia. *Br J Haematol* 147: 43-70.
7. Risitano AM, Salleri C, Serio B, Torelli GF, Kulagin A, et al. (2010) Alemtuzumab is safe and effective as immunosuppressive treatment for aplastic anaemia and single-lineage marrow failure: a pilot study and a survey from the EBMT WPSAA. *Br J Haematol* 148: 791-796.
8. Golay J, Introna M (2012) Mechanism of action of therapeutic monoclonal antibodies: promises and pitfalls of in vitro and in vivo assays. *Arch Biochem Biophys* 526: 146-153.