

## Evaluations of Biochemical, Hematological and Histopathological Parameters of Subchronic Administration of Ethanol Extract of Albizia Gummifera Seed in Albino Wistar Rat

Mokennon Debebe<sup>1</sup>, Mekbeb Afework<sup>2</sup>, Eyasu Makonnen<sup>3</sup>, AsfawDebella<sup>4</sup>, Bekesho Geleta<sup>4</sup> and Negero Gameda<sup>4\*</sup>

<sup>1</sup>College of Health Science, Arsi University, Oromia, Ethiopia

<sup>2</sup>Department of Anatomy, College of Health Science, Addis Ababa University, Addis Ababa, Ethiopia

<sup>3</sup>Department of Pharmacology, College of Health Science, Addis Ababa University, Addis Ababa, Ethiopia

<sup>4</sup>Traditional and Modern Medicine Research, Ethiopian Public Health Institute, Addis Ababa, Ethiopia

\*Corresponding author: Negero Gameda, Traditional and Modern Medicine Research, Ethiopian Public Health Institute Addis Ababa, Ethiopia, Tel: +251911339449; E-mail: negerof@yahoo.com

Received date: January 16, 2017; Accepted date: January 23, 2017; Published date: January 26, 2017

Copyright: © 2016 Debebe M, et al. This is an open-access article distributed under the terms of the Creative Commons Attribution License, which permits unrestricted use, distribution, and reproduction in any medium, provided the original author and source are credited.

### Abstract

Albizia gummifera are plants found in Ethiopia that have different medicinal values. The objective of the present study was to evaluate the toxicological effects of sub-chronic administered hydro-ethanolic (70%) seeds extract of Albizia gummifera in albino Wistar rats. The seeds of these plants were collected from different areas of Ethiopia. They were dried and crushed to powder and macerated with hydro-alcohol and placed in orbital shaker. The extract was then filtered through Whatman filter paper No.1 and the filtrate was evaporated to dryness by Rota vapor and further concentrated by water bath at 40°C. The extract was packed in air tight brown glass bottles and kept in a refrigerator at 4°C. The extract was then administered to rats at different doses to determine the LD 50 of the extract and at doses of 125 mg/kg/day and 250 mg/kg/day for the sub-chronic toxicity study. The LD 50 of Albizia gummifera were found as 4000 mg/kg and 3500 mg/kg, respectively. Statistically significant difference in body weight was observed in female rats in the 10<sup>th</sup> week at 250 mg/kg body weight of seeds extract of Albizia gummifera administered group and in the male rats at lowest dose during the 9<sup>th</sup> and 10<sup>th</sup> weeks of administration period for seeds extract of *Milletia ferruginea*. The seeds extract of Albizia gummifera statistically decreased ( $p \leq 0.05$ ) MCH in the male rats at both doses; MCHC at both 125 mg/kg and 250 mg/kg in the female rats; and MCH in the female rats at higher dose and increased RDW-CV in the male rats at both doses. It increased NEUT at the highest dose in both females and males. The seeds extract of *Milletia ferruginea* decreased ( $p \leq 0.05$ ) in the MCHC and MONO of female rats at the highest doses. ALP, ALT and urea were found significant in the female rats administered with 250 mg/kg of seeds extract. While, seeds extract of Albizia gummifera increased only urea in male rats at 250 mg/kg. Some histopathological changes in liver and kidney were also observed for both plants extracts. There were inflammations, congestions and focal hepatocellular necrosis of the liver tissue. The extracts also produced atrophy of the glomeruli of the kidney. The observed changes in both of the plant seeds extract might have resulted because of the presence of some bioactive ingredients in the extract. Therefore, the active ingredients which might be responsible for toxic insult should be researched with their mechanisms of actions.

**Keywords:** Albizia gummifera; Seeds; Hydroethanolic extract; Toxicity; Wistar Albino Rats

### Introduction

Traditional use of medicinal plants alone or in combination with Western drugs to treat a wide variety of diseases including diarrheal diseases, malaria and leishmaniasis is widely practiced in the Ethiopian communities as elsewhere in developing countries [1]. The growing popularity of traditional medicine, particularly herbal medicine is based on their observed effectiveness in the treatment and prevention of diseases. This belief is that, one, traditional medicines are 'natural' and therefore safe; in the other hand, lack of success in treating different ailments by modern medicine due to drug resistance and unfavorable side effects. However, these beliefs have led to indiscriminate use over a long period of time without appropriate dosage monitoring and undermining danger associated with the potential toxicity of medicinal plant therapy. There is a documented incidence of renal and hepatic toxicity resulting from the long-time

administration of medicinal plants [2,3]. Therefore, this thought has necessitated us to document scientific information on the safety/toxic risk potentials of Albizia gummifera.

*A. gummifera* is a member of Leguminosae family and Mimosoideae sub family. This plant is a large deciduous tree with flattened canopy, growing up to 35 m high and trunk up to 75 cm in diameter. It is found in east Africa, the Democratic Republic of Congo, Madagascar, and West Africa, ranging from dry or wet lowlands to up land forest edges, and in riverine forest, at an altitude of 2400 m above sea level. It is indigenous in few countries namely; Angola, Cameroon, Democratic Republic of Congo, Ethiopia, Kenya, Madagascar, Nigeria, Tanzania, Uganda, and Zambia. Traditionally stem bark decoction of *A. gummifera* is used to treat malaria and an extract from fresh crushed pods is used to treat stomach pains. The seeds and stem bark of the plants have shown antibacterial activities against both gram positive and gram negative bacteria [4], molluscicidal activities against *Biomphalaria pfeifferi*, *Bulinus* sp. and *Physa acuta* [5], larvicidal activity against *Aedes aegypti*, *Aedes africanus*, and *Culex*

quinquefasciatus [6]. Its roots are used to cure skin diseases such as acne, itching and eczema. Moreover, crude hydro-alcoholic (20-80%) extracts of *A. gummifera* was effective against reference strain of *N. gonorrhoeae* [7].

Although *Albizia gummifera* has many useful health benefits, to our knowledge no literature exists on its toxicity profile. This study was therefore undertaken to evaluate the acute and sub-chronic toxicities of the ethanolic extract of *A. gummifera* seeds on biochemical, hematological and histopathological indices of albino Wistar rats.

## Materials and Methods

### Plant collection and processing

The seeds of *A. gummifera* were collected from Mettu, Illu Aba-Bora, Ethiopia which is 400 km west of Addis Ababa in the wild at altitudinal range of 900-3900 meter above sealevel. The plants identity was authenticated by taxonomist using standard Flora, and voucher specimens of *A. gummifera* (Voucher Number AG-2006), which were pre-deposited in the Herbarium of the Traditional and Modern Medicine Research, Ethiopian Public Health Institute, Addis Ababa, Ethiopia.

### Plant material extraction

The dried seeds of the plant were crushed to powder using wooden-made pestle and mortar. About 1250 gm of the powdered seeds of *A. gummifera* was macerated with hydroalcohol (70% ethanolic) in 1:4 solutes to solvent ratio and placed in orbital shaker at room temperature for 72 h. The procedure was repeated three times to extract exhaustively until the extract gave faint or no coloration. The extract was then filtered through Whatman filter paper No.1 to remove any residue, and then, it was evaporated by a vacuum rotary evaporator and further concentrated by water bath at 40°C to obtain the crude extract. Then, the gummy residue extract was and kept in air tight brown glass bottles with proper label and kept in a refrigerator at 4°C until used.

### Experimental animals

Swiss albino rats, 4 to 5 weeks of age, weighing between 100 to 120 g, that were bred at Animal Breeding Unit, Ethiopian Public Health Institute (EPHI) was used in this study. The animals were housed in sanitary cages and had access to tap water and food. The room temperature was controlled at 24 to 26°C in a 12 h light/dark cycle. All procedures involving the animals were conducted with strict adherence to standard guidelines and procedures. The male and female rats were kept in separate cages. They were all acclimatized for one week to the laboratory environment prior to drug administration. The leftover food and water were changed daily and the cages were cleaned with the husk changed every three days. All the animals seemed healthy.

### Acute oral toxicity test

The rats were randomly grouped in to twelve experimental groups (Group I to XII) and one control groups of female rats with four rats in each group. The rats were fasted overnight but allowed free access to drinking water prior to experimentation. The animals in the group I-XII received *A. gummifera* seed extract at single oral doses of 50, 100, 150, 250, 500, 1000, 1500, 2000, 2500, 3000, 3500, and 4000 mg/kg body weight, respectively, in attempt to see sign of toxicity and to

determine the LD<sub>50</sub> of the extracts of the plants. The control group received only distilled water. The animals were kept under observation after post-treatment in order to observe any death or any behavioural and/or clinical manifestations such as CNS effect (excitement, ataxia, and sleep), altered feeding, vomiting and diarrhoea. At the end of two weeks, one animal from each group was randomly sacrificed humanely after anaesthesia (diethyl ether) by cervical dislocation and post-mortem gross observations were carried out on the internal organs.

### Sub-chronic toxicity test

Fifteen male and 15 female Wistar rats were randomly allocated to the treatment and control groups to investigate the effect of sub chronic treatment with *A. gummifera* seed extracts on general body weight and weight of the organs (liver and kidneys); and on blood parameters as well as histopathology of liver and kidney tissues. The rats were randomly assigned to three groups of ten animals, five males and five females. One group was assigned as control group; animals in one group from the treatment group received single daily dose of 125 mg/kg body weight and the second group was administered with a single daily dose of 250 mg/kg body weight of *A. gummifera* seed extract for 90 days. Throughout the experimental period, the female and male rats were housed in separate cages. The control group received only distilled water, daily throughout the period of study. The body weight of each rat in each group was measured before the beginning of drug administration and once a week thereafter throughout the study period. Throughout the study period, animals in all the study group were carefully monitored/ followed/ for any clinical signs of toxicity, body weight changes and mortality and were later sacrificed for haematological and biochemical investigations and organs histological changes.

### Biological specimen collection

At the end of dose administration, blood samples were collected through cardiac puncture using a gauge needle mounted on a 5 ml syringe. Before specimen collection all animals were anesthetized with diethyl ether. Blood from each animal were collected into non-anti-coagulated and Ethylene Diamine Tetra-Acetic Acid (EDTA) anti-coagulated tubes and allowed to clot for 3 h. The collected blood was centrifuged within 30 min of collection at 3,000 rpm for 10 min and the serum was collected for blood chemistry (biochemical assay). After blood collection, each rat in the treated and control groups were quickly humanely sacrificed by cervical dislocation. The animals were placed in the supine position on dissection board. The limbs were stretched and fixed to make the autopsy of the organs of interest easy. At autopsy, liver and kidneys were visually examined for any signs of gross lesions. The organs removed from each rat were blotted on the filter paper. Then each of these organs was weighed on a semi-microbalance. After rinsing in normal saline, sections were taken from each of these organs. These specimens were placed in a pre-labeled sample bottles containing fixative (10% neutral buffered formalin) and used for histopathological studies.

### Hematological and biochemical analyses

Hematological and serum biochemical parameters were analyzed at Core Laboratories, Ethiopian Public Health Institute, Addis Ababa, Ethiopia. Hematological parameters including RBC count, WBC count, HCT, HGB, RDW, PLT count, and differential count of each of the WBCs were measured in an automatic hematology analyzer, cell-DYN-3700 (Abbott Diagnostic Division, USA). In addition, red cell

indices such as MCV, MCH and MCHC were also analyzed with the automatic analyzer. Similarly, serum biochemical parameters including ALP, ALT, AST, and urea were determined in clinical chemistry analyzer, Human star 80 (Human GmbH, Germany).

## Histopathological Studies

### Tissue processing

For histopathological studies under light microscopy, tissue samples taken at autopsy were processed in Histology laboratory, Department of Anatomy, College of Health Sciences, Addis Ababa University. Each of the tissue samples harvested from liver and kidneys of all extract treated and non-treated animals were fixed separately in 10% neutral buffered formalin. Following fixation, the tissues were rinsed in running water overnight to remove excess fixative. The wet fixed tissues were dehydrated with progressively increasing concentrations of ethanol. After dehydration, the tissues were passed through xylene solution to clear the ethanol and facilitate molten paraffin wax infiltration (55°C). The tissues were transferred to liquid paraffin wax. The wax impregnated tissues were then embedded in paraffin blocks. All tissue blocks were labelled and allowed to dry at room temperature. These tissue blocks were sectioned with a Leica Rotary Microtome (Leica Rm2125RT, Model Rm2125, China) at 5-6 µm thickness. The ribbons of these sections were collected and gently floated on a tissue flotation water bath at a temperature of 20°C to stretch the paraffin wax impregnated tissue. The stretched floated ribbons were picked up on glass microscopic slides. The slides were placed in a warm oven overnight to help the slice adhere to the slides. The slides were allowed to cool at room temperature and kept ready for routine staining steps.

### Tissue staining

Before carrying out the staining of tissues, the sections were deparaffinised by xylene. Then the tissues were hydrated successively by running through decreasing concentration of alcohols. The slides were then rinsed in distilled water followed by Harris' haematoxylin stain. These slides were washed in tap water and dipped into 1% acid alcohol for differentiation and remove excess stain. The sections were rinsed briefly in running tap water to remove excess acid. The slides were then dipped in bluing solution followed by counter stain in eosin. The H and E stained sections were dehydrated by running through increased grade of ethyl alcohols. Lastly, these slides were mounted using DPX mountant and glass cover slips.

## Microscopy and Photomicrography

Microscopic slides of organs under study were examined carefully under compound light microscope at Histology Laboratory of Anatomy Department, College of Health Sciences, AAU. Slides from the extract treated groups were evaluated for any toxic insult to the organs compared to slides from their respective control groups. Finally, photomicrographs of selected slides were taken using (LEICA ICC50 HD, Germany) automated built-in digital photo camera.

## Statistical Analysis

The numerical data obtained from the experiment were analysed statistically on SPSS version 20, computer software package. The values of body weight changes were analysed and the results were expressed as M ± SEM. Differences between the treated and control groups were

compared by using one-way analysis of variance (ANOVA), followed by Dunnett's t-test to determine their level of significance. Differences at  $p < 0.05$  were considered statistically significant.

## Results

### Acute toxicity study

The acute toxicity study was a single dose toxicity test conducted to estimate lethal dose of the 70% ethanolic seeds extract of *A. gummifera* in rats' model. The administration of the extract orally at 50, 100, 150, 250, 500, 1000, 1500, 2000 and 2500 mg/kg body weight did not produce mortality of the administered group for seeds extract of *A. gummifera*. While two rats died among the 4000 mg/kg *A. gummifera* seed extract treated group. The LD 50 of *A. gummifera* was therefore found as 4000 mg/kg. These animals have shown some behavioral changes such as altered feeding, low locomotion and pilo-erection before death. Also acute manifestation like diarrhea and loss of appetite were observed. No abnormal gross necropsy of liver and kidneys were observed.

### Sub-chronic toxicity study

**Effect of the extract of both plants on general health and body weight:** During the 90 days of sub-chronic toxicity evaluation, all the male and female rats that were orally administered with the repeated doses of both 125 mg/kg and 250 mg/kg body weight showed no extract related noticeable changes in their general behaviour as compared to the control group for both of the plant extracts. The effect of the seed extracts of *A. gummifera* on the body weight of male and female rats during the 13 weeks of sub-chronic treatment are summarized in (Table1).

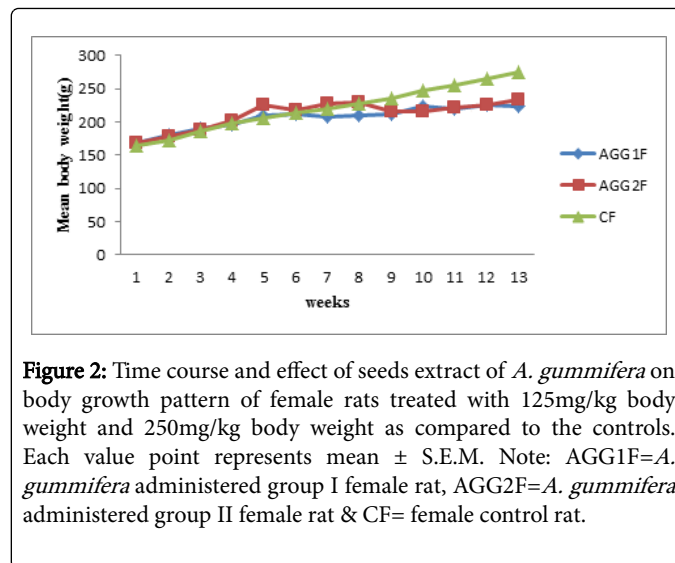
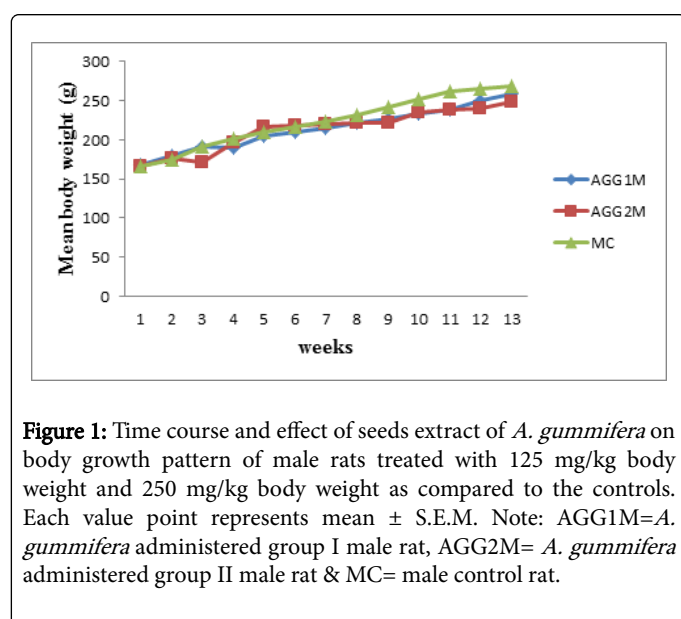
Body weight of both the treated and control groups increased with increasing duration. As it can be seen from (Figure 1 and 2), the body weight increase patterns of the male and female rats during the sub-chronic treatment with both of the plants extracts seem to be normal. In the seeds extract of *A. gummifera* administered groups, no significant difference ( $p > 0.05$ ) was observed in the mean values of the body weights of male and female rats treated with 125 mg/kg body weight and males treated with 250 mg/kg body weight as compared with their respective controls. However, significant difference was observed in the mean body weight of female rats treated with 250mg/kg body weight as it decreased at the 9<sup>th</sup> week by 8.7% and further decreased by 12.8% at the 10th week as compared with the control group.

Period	Sex	Control	Treatment groups (mg/kg body weight/day)	
			125	250
WK1	Male	166.4 ± 1.75	168.2 ± 3.35 (0.24)	166.8 ± 2.49 (0.51)
	Female	164.8 ± 2.13	167.6 ± 3.36 (0.40)	167.8 ± 3.67 (0.32)
WK2	Male	175.2 ± 2.15	179.6 ± 4.13 (0.24)	176 ± 5.09 (0.12)
	Female	172.2 ± 3.65	179.2 ± 5.12 (0.53)	178.6 ± 3.44 (0.91)
WK3	Male	191.8 ± 2.18	191.2 ± 4.08 (0.25)	171.6 ± 5.29 (0.11)
	Female	186.6 ± 2.98	189.6 ± 3.97 (0.59)	187.2 ± 4.25 (0.51)
WK4	Male	201.6 ± 2.80	189.8 ± 3.48 (0.68)	196.2 ± 5.90 (0.18)

	Female	197.6 ± 3.28	196.2 ± 4.12 (0.67)	202 ± 4.15 (0.66)
WK5	Male	209.8 ± 2.85	205.2 ± 2.08 (0.56)	216.8 ± 4.91 (0.32)
	Female	205.2 ± 3.06	209.4 ± 5.42 (0.29)	225.2 ± 3.47 (0.81)
WK6	Male	216.8 ± 2.75	209.4 ± 1.29 (0.17)	218.8 ± 3.65 (0.59)
	Female	213 ± 2.76	211.6 ± 4.27 (0.42)	217.2 ± 2.94 (0.90)
WK7	Male	223.6 ± 2.50	214.4 ± 1.89 (0.59)	219.8 ± 4.83 (0.23)
	Female	220.4 ± 3.76	207.2 ± 4.62 (0.70)	226.8 ± 2.08 (0.28)
WK8	Male	231 ± 2.51	221.4 ± 1.80 (0.54)	220.8 ± 3.80 (0.44)
	Female	227 ± 4.89	210.6 ± 4.61 (0.91)	229.8 ± 2.39 (0.19)
WK9	Male	242.2 ± 2.35	226.6 ± 1.99 (0.75)	222.2 ± 4.59 (0.22)
	Female	235.6 ± 4.53	212.2 ± 7.77 (0.32)	215.2 ± 1.39 (0.23)
WK10	Male	252.6 ± 2.42	233.8 ± 2.15 (0.83)	234.8 ± 4.53 (0.25)
	Female	247.8 ± 3.65	223 ± 6.40 (0.32)	216 ± 7.07* (0.04)
WK11	Male	261.6 ± 6.77	238.8 ± 2.35 (0.06)	237.6 ± 3.47 (0.22)
	Female	255.2 ± 3.76	219.4 ± 6.52 (0.31)	220.6 ± 2.06 (0.27)
WK12	Male	265 ± 4.82	249.6 ± 3.43 (0.53)	240.2 ± 5.11 (0.43)
	Female	265.4 ± 4.53	225.6 ± 5.81 (0.64)	226.4 ± 3.47 (0.62)
WK13	Male	269.2 ± 4.22	258.8 ± 3.53 (0.74)	248.4 ± 3.33 (0.20)
	Female	274.4 ± 4.00	223.8 ± 5.99 (0.45)	232.6 ± 2.60 (0.42)

Values are given as Mean ± S.E.M. for each male and female subgroup. The figures under the brackets indicate the calculated p values of the treatment groups as compared to the controls.  
\* = significant (p<0.05). The mean difference is considered significant at p<0.05. (n=10 (5 male and 5 females in each group)).

**Table 1:** Effect of the sub-chronic administration of *A. gummifera* seeds extract on the body weight of male and female rats.



**Effect of *A. gummifera* hydro alcohol seeds extract on hematological parameters:** The effect of sub-chronic treatment of the seed extract of *A. gummifera* on hematological parameters of male rats as compared to the controls is illustrated in (Table 2).

Hematological Parameters	Control (G3)	125 mg/kg body weight (G1)	250 mg/kg body weight (G2)
WBC (× 103/μL)	7.99 ± 1.08	12.24 ± 2.18 (.19)	10.94 ± 1.49 (.39)
RBC (× 106/μL)	9.94 ± 0.17	10.14 ± .14 (.54)	10.00 ± .11 (.93)
HGB (g/dL)	18.50 ± 0.25	18.26 ± .38 (.80)	17.53 ± .23 (.10)
HCT (%)	54.36 ± 1.12	54.30 ± 1.06 (.99)	52.73 ± .49 (.41)
MCV (fL)	54.66 ± .44	53.50 ± .36 (.25)	52.73 ± .66 (.06)
MCH (pg)	18.63 ± .06	18.00 ± .20 (.04)*	17.53 ± .14 (.004)*
MCHC (g/dL)	34.03 ± .33	33.63 ± .18 (.49)	33.23 ± .23 (.12)
PLT (× 103/μL)	901.66 ± 67.49	1101.00 ± 81.22 (.11)	1079.33 ± 23.53 (.15)
RDW-CV (%)	20.16 ± .06	21.63 ± .21 (.00)*	21.90 ± .15 (.00)*
NEUT (%)	15.36 ± 2.01	28.30 ± 4.93 (.05)	32.70 ± 2.20 (.01)*
LYMPH (%)	77.56 ± 1.73	66.50 ± 6.24 (.14)	64.66 ± 1.46 (.09)
MONO (%)	5.30 ± 1.44	4.70 ± 1.20 (.90)	5.60 ± .70 (.97)
EO (%)	1.40 ± .95	0.26 ± .08 (.32)	0.16 ± .06 (.27)
BASO (%)	.36 ± .17	0.23 ± .13 (.73)	0.20 ± .10 (.63)

**Table 2:** Hematological parameters of male rats administered with 125 and 250mg/kg body weight of seed extract of *A. gummifera*.

The sub-chronic treatment with both 125 mg/kg and 250 mg/kg body weight seed extract did not significantly affect haematological parameters except a few of the parameters seen to be significant (p<0.05). Sub-chronic treatment of male rats with 125 mg/kg and 250 mg/kg of seed extracts produced significant change (p<0.05) in the MCH as it decreased by 3.4% in the 125 mg/kg administered group



and further decreased by 5.9% in the 250 mg/kg administered group, and RDW-CV as it increased by 7.3% in the 125 mg/kg administered group and further increased by 8.6% in the 250 mg/kg administered group. Besides, the seed extract induced significant change in the NEUT at 250 mg/kg body weight as it increased from  $15.36 \pm 2.01$  to  $32.70 \pm 2.20$ .

Hematological parameters such as RBC, WBC and PLT increased in the male rats at both doses compared to the control although not significant. But, parameters such as HGB, HCT, MCV, MCH, LYMPH, EO and BASO were all found decreased in the male rats even though they were statistically not significant.

Hematological Parameters	Control (G3)	125 mg/kg body weight (G1)	250 mg/kg body weight (G2)
WBC ( $\times 103/\mu\text{L}$ )	$5.27 \pm 2.32$	$9.55 \pm 1.71$ (.42)	$10.48 \pm 3.17$ (.30)
RBC ( $\times 106/\mu\text{L}$ )	$8.66 \pm .31$	$8.99 \pm .18$ (.51)	$9.32 \pm .14$ (.14)
HGB (g/dL)	$16.86 \pm .67$	$17.16 \pm .55$ (.88)	$17.13 \pm .06$ (.90)
HCT (%)	$49.13 \pm 1.74$	$51.36 \pm 1.40$ (.42)	$50.93 \pm .34$ (.55)
MCV (fL)	$56.76 \pm .66$	$57.10 \pm .40$ (.88)	$54.63 \pm .61$ (.06)
MCH (pg)	$19.46 \pm .23$	$19.06 \pm .23$ (.42)	$18.36 \pm .23$ (.02)*
MCHC (g/dL)	$34.33 \pm .14$	$33.63 \pm .12$ (.03)*	$33.40 \pm .20$ (.01) *
PLT ( $\times 103/\mu\text{L}$ )	$665.00 \pm 218.70$	$1029.00 \pm 12.34$ (.18)	$1222.33 \pm 92.09$ (.05)
RDW-CV (%)	$17.23 \pm .98$	$18.60 \pm .20$ (.26)	$19.43 \pm .27$ (.07)
NEUT (%)	$12.06 \pm 2.14$	$20.90 \pm 6.96$ (.32)	$35.00 \pm 1.80$ (.02)*
LYMPH (%)	$79.83 \pm 3.89$	$73.36 \pm 8.51$ (.67)	$58.13 \pm 4.16$ (.07)
MONO (%)	$4.40 \pm .55$	$5.13 \pm 1.88$ (.94)	$6.53 \pm 2.51$ (.64)
EO (%)	$3.66 \pm 3.12$	$.50 \pm .05$ (.40)	$.26 \pm .12$ (.36)
BASO (%)	$.03 \pm .03$	$.10 \pm .05$ (.48)	$.06 \pm .03$ (.81)

Values are expressed as Mean  $\pm$  SEM. The figures in brackets indicate the calculated p values of the treatment groups as compared to the control. \* =significant ( $p < 0.05$ ). The mean difference is considered significant at  $p < 0.05$ .

**Table 3:** Hematological parameters of female rats administered with 125 and 250 mg/kg body weight of seed extract of *A. gummiifera*.

The effect of 13 weeks of sub-chronic treatment of the seed extract of this plant on hematological parameters of female rats is illustrated in (Table 3). The seed extract induced significant change ( $p < 0.05$ ) at 250 mg/kg body weight in the MCH as it decreased by 5.6% and in the MCHC as it decreased by 2.0% at the lowest dose and further by 2.7% at the highest dose. In addition, the seed extract affected the NEUT at 250 mg/kg body weight as it increased from  $12.06 \pm 2.14$  to  $35.00 \pm 1.80$ . The parameters like WBC, RBC and PLT increased in the female rats compared to their controls but this increment was not significant. On the other hand, hematological parameters such as EO and MCV decreased at both doses but still the values were not significant.

Biochemical Parameters	Control (G3)	125 mg/kg dose (G1)	250 mg/kg dose (G2)
Albumin (g/dl)	$4.70 \pm 0.22$	$4.79 \pm 0.26$ (0.94)	$4.45 \pm 0.19$ (0.65)

ALP (U/L)	$135.75 \pm 11.69$	$168 \pm 12.79$ (0.44)	$160.75 \pm 29.26$ (0.59)
ALT (U/L)	$79.75 \pm 2.59$	$94.25 \pm 5.15$ (0.11)	$79.75 \pm 6.21$ (1.00)
AST (U/L)	$179.75 \pm 5.20$	$251.5 \pm 43.65$ (0.34)	$253.75 \pm 47.42$ (0.32)
Urea (mg/dL)	$28.50 \pm 0.96$	$33 \pm 0.41$ (0.09)	$36.75 \pm 2.21$ (0.005) *

Values are expressed as Mean  $\pm$  SEM. The figures in brackets indicate the calculated p values of the treatment groups as compared to the control. \* =significant ( $p < 0.05$ ). The mean difference is considered significant at  $p < 0.05$ .

**Table 4:** Serum biochemical parameters of male rats administered with 125 and 250 mg/kg body weight of seed extract of *A. gummiifera*.

**Effect of *A. gummiifera* hydro alcohol seeds extract on serum biochemical parameters:** Effects of sub-chronic treatment with hydro-alcoholic seed extract of *A. gummiifera* on serum biochemical parameters of male and female rats are shown in (Tables 4 and 5), respectively. Except urea with male administered at 250 mg/kg body weight as it increased by 28.94%, all the parameters measured were not significantly different between the control and extract administered groups at both doses.

Biochemical Parameters	Control (G3)	125 mg/kg dose (G1)	250 mg/kg dose (G2)
Albumin (g/dl)	$5.16 \pm 0.19$	$5.01 \pm 0.16$ (0.79)	$4.87 \pm 0.16$ (0.42)
ALP (U/L)	$75.75 \pm 12.49$	$88.75 \pm 8.41$ (0.79)	$134.75 \pm 22.87$ (0.05)
ALT (U/L)	$63.75 \pm 5.66$	$74.75 \pm 4.00$ (0.26)	$61.50 \pm 5.33$ (0.93)
AST (U/L)	$194 \pm 16.92$	$237.25 \pm 62.26$ (0.65)	$192.25 \pm 13.88$ (0.99)
Urea (mg/dL)	$34.50 \pm 2.33$	$38.75 \pm 2.49$ (0.29)	$37.00 \pm 1.08$ (0.62)

Values are expressed as Mean  $\pm$  SEM. The figures in brackets indicate the calculated p values of the treatment groups as compared to the control. The mean difference was not significant ( $p \geq 0.05$ ).

**Table 5:** Serum biochemical parameters of female rats administered with 125 and 250 mg/kg body weight of seed extract of *A. gummiifera*

### Macroscopic observations and organ weights

After the period of 90 days of sub chronic-toxicity study, rats that were orally administered with the repeated doses of the extracts at both 125 and 250 mg/kg body weight of both plants showed no abnormal gross findings in the liver and kidneys in the post-mortem macroscopic examination. The mean organ weight of liver and kidney of the seed extract of *A. gummiifera* administered groups and control group are shown in Tables 6 and 7, for the male and female rats, respectively. No significant difference ( $p > 0.05$ ) was seen in the organ weights between extract treated and control rats of both sex.

Group	Dose (mg/kg)	Liver (g)	Kidney (g)
I	125	$9.32 \pm .18$ (.29)	$1.05 \pm .02$ (.95)
II	250	$9.18 \pm 0.13$ (.09)	$0.99 \pm 0.05$ (.60)

III	Control	9.60 ± .07	1.04 ± .04
-----	---------	------------	------------

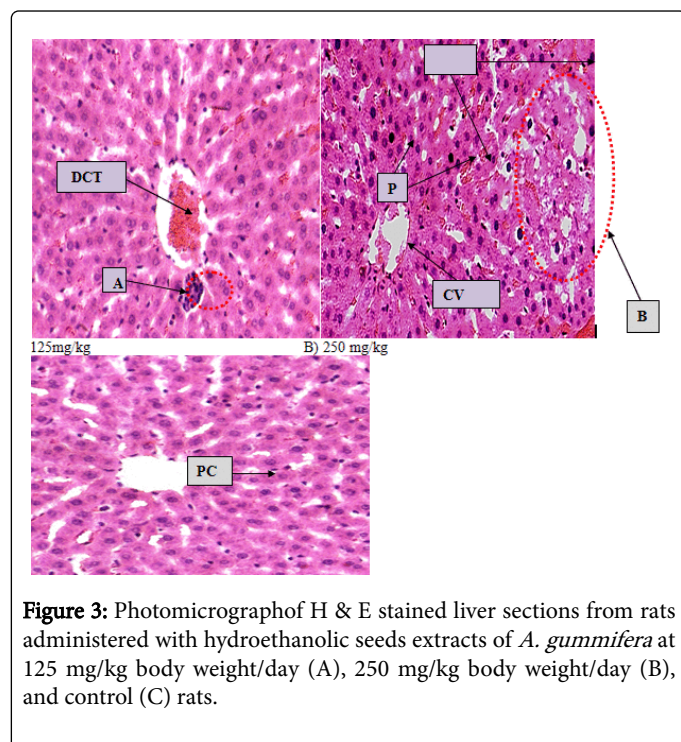
**Table 6:** Organ weights of male rats administered with 125 & 250 mg/kg body weight doses of the seed extracts of *A. gummiifera*.

Group	Dose (mg/kg)	Liver (g)	Kidney (g)
I	125	9.40 ± 0.19 (.32)	0.91 ± 0.05 (.91)
II	250	9.42 ± .09 (.27)	1.01 ± .03 (.52)
III	Control	9.16 ± .12	0.85 ± 0.19

**Table 7:** Organ weights of female rats administered with 125 and 250 mg/kg body weight doses of the seed extracts of *A. gummiifera*.

### Microscopic observations

**Effect of hydroalcoholic seed extract of *A. gummiifera* on histopathology of the liver:** Routine hematoxylin and eosin stained sections of liver were examined to assess the effect of the 90 days sub-chronic oral administration with 70% ethanolic seed extract of *A. gummiifera* on this tissue. Light microscopic examination of the liver sections of 125 mg/kg of both male and female rats for seed extract of *A. gummiifera* administered group showed inflammation and congestions of blood in the central vein (Figure 3). The 250mg/kg administered group also showed congestions of blood in the central vein and in the sinusoids, focal cellular necrosis and pyknosis (Figure 3).

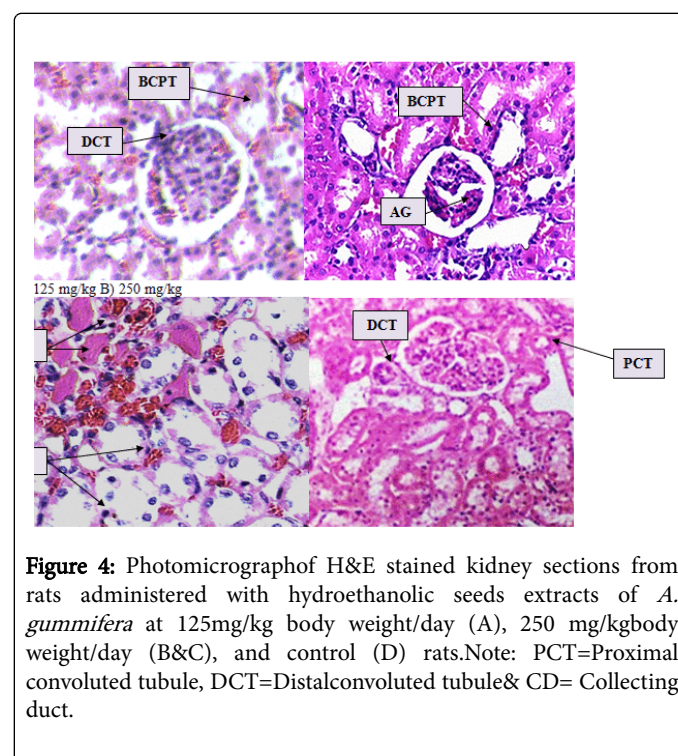


**Figure 3:** Photomicrograph of H & E stained liver sections from rats administered with hydroethanolic seeds extracts of *A. gummiifera* at 125 mg/kg body weight/day (A), 250 mg/kg body weight/day (B), and control (C) rats.

Different changes were observed in the sections from the hydroethanolic extract administered rat including: inflammations around central vein (I) and congestion of blood in the central vein (BCCV) in rat administered at 125 mg/kg body weight/day (A); focal cellular necrosis (N), congestion of blood in the central vein (BCCV),

congestion of blood in the sinusoids (BCS) and pyknosis (P) in rats administered 250 mg/kg body weight/day (B); While there was no histopathological changes visible in the sections of the control (C) rats. (Magnifications, all X2000).

**Effect of hydroalcoholic seed extract of *A. gummiifera* on histopathology of the kidneys:** Histological examinations of sections of the kidney from rats administered with the seeds extract of *A. gummiifera* at 125 mg/kg in both male and female rats have shown peritubular blood congestions (Figure 4). Kidney histology of both sex administered with 250 mg/kg body weight have also shown congestions, atrophy of glomeruli and formation of focal protein cast in the renal interstitium (Figure 4).



**Figure 4:** Photomicrograph of H&E stained kidney sections from rats administered with hydroethanolic seeds extracts of *A. gummiifera* at 125mg/kg body weight/day (A), 250 mg/kg body weight/day (B&C), and control (D) rats. Note: PCT=Proximal convoluted tubule, DCT=Distal convoluted tubule & CD= Collecting duct.

Various changes were observed in the sections from the hydroethanolic extract administered rats: congestion of blood in the peritubular areas (BCPT) in rat administered at 125 mg/kg body weight/day (A); congestion of blood in the peritubular areas (BCPT), atrophy of the glomeruli (AG) and protein cast in the kidney interstitium (PC) in rats administered 250 mg/kg body weight/day (B and C); While there were no histopathological changes visible in the sections of the control rat (D). All the changes were observed under 2000 magnifications.

### Discussion

Acute toxicity test is carried out on laboratory animals, in this particular case on albino rats receiving different doses of the substances in question. The oral administration of the aqueous extracts of *A. gummiifera* seeds did not show any signs of toxicity nor did they produce lethality in rats up to 3000 mg/Kg. As this dose is minimal it is very unlikely to associate the death of the animal with the extract. 50% of the animals died with 4000 mg/kg for *A. gummiifera* seeds extract treated groups. This has, therefore, indicated that the LD50 of these plants were found to be 4000 mg/kg body weight, respectively. The LD

50 of *A. gummifera* is in agreement with an earlier work on the aqueous leaf extract of *A. chevalieri* by Saidu and associates [8], that the extract has an LD 50 of greater than 3000 mg/kg body weight. In line with this finding, a previous study [6], has indicated that in the mice the LD 50 of *A. gummifera* whose effective dose are 125 mg/kg, through the oral administration, were 2300 body weight. As the effective doses for the plants have been found as 125 mg/kg body weight [9,10], it could be suggested that the lethal dose is more than twenty times greater than the effective dose.

The seeds extract of both plants had no harmful effect on body growth patterns of test groups. Body weight of both the treated and untreated animals of both sexes increased as the duration increased. However, during the 9<sup>th</sup> week, although statistically not significant, there was a slight decrease in the body weight of female rats treated with *A. gummifera* seeds extract in a dose dependent manner as compared with the controls. But statistically significant difference in body weight was observed in female rats during 10<sup>th</sup> week at 250 mg/kg body weight. Such changes in the body weight is in line with the results of toxicity studies following administration of aqueous extract of *Vernonia amygdalina* [11] and administration of aqueous extract of *Clerodendrum myricoides* [12] which results in suppression of weight gain of the extract treated animals.

As was described by Amacher [13] biological markers are used to recognize, characterize and monitor treatment-related responses following exposure to xenobiotic agents. Biomarkers serve three primary applications in toxicology: to confirm exposure to a deleterious agent, to provide a system for monitoring individual's susceptibility to a toxicant, and to quantitatively assess deleterious effects of a toxicant to an organism or individual. One of such biomarkers is blood profile as manifestation of abnormal changes in metabolism due to underlying disease conditions. In toxicological studies, changes in hematological as well as biochemical parameters are used as indices of toxicities [14].

Measurement of RBC count, HCT also sometimes referred to as a PCV, and HGB can be used to determine anemia which could be due to a decrease in the total number of erythrocytes, MCV, MCH or MCHC [15-17]. More recently RDW-CV, automated parameter providing information on the degree of variation of individual red cell size, has been used in conjunction with the traditional red cell indices in order to narrow down the possible causes of anaemia in an individual patient [17]. The mitotic capacity of different hematopoietic cell lineages predominates in marrow at different times. On direct marrow examination, the great majority of mitoses (74% to 90%) were of erythroid lineage; only a few (0% to 10%) were granulocytic [18]. The alteration in number of RBC count and HGB content may be due to defective haematopoiesis, inhibited erythropoiesis or an increase in destruction of red blood cells [19,20].

In the present study of 125 and 250 mg/kg body weight/ day of *A. gummifera* seeds extract treated group, did not decrease total RBC count, PLT, WBC, LYMPH, MONO, EO, BASO, HCT and HGB in the male rats as compared with the male control group. This observation is in agreement with other findings in which the values of the various RBC and WBC parameters of oral administration of saponins isolated from *A. lebeck* bark extract which were found to be comparable with those of the control group [21-27]. The seeds extract of *A. gummifera*, however, significantly increased the NEUT at 250 mg/kg as compared to the control. The seeds extract of this plant did not decrease the levels of two red blood cell indices (MCV and MCHC) but, significantly decreased the level of MCH and increased the RDW-CV at both doses

as compared to the male control. This indicates the seeds extract of *A. gummifera* may slightly induce anemia in male rats.

The seeds extract of this plant did not decrease total RBC count, PLT, WBC, LYMPH, MONO, EO, BASO, HCT, HGB and RDW-CV in the female rats. But have significantly increased the NEUT at 250 mg/kg as compared to the control. The plant seeds extract did not decrease the level of MCH but, decreased MCV at 250 mg/kg administered group and MCHC at both doses (125 and 250 mg/kg body weight) in the female rats as compared to the female control. This also indicates the plant seeds extract may induce anemia. This may happen in both of male and female rats because of the seeds extract of *A. gummifera* may have effect on iron metabolism or/and erythropoiesis.

Another biomarker to toxic effect is serum biochemical profile. This effect can be detected or quantified by measuring the various serum biochemical parameters. ALT is primarily localized in liver tissue, and trace amount is found in skeletal muscle and heart tissue. Its cellular localizations are cytoplasm and mitochondria. This biochemical parameter could leak out from damaged tissues because of histopathological lesion particularly during hepatocellular necrosis [13,21,22]. AST is localized in liver, heart, muscle, brain and kidney tissues. Similarly, its cellular localizations are cytoplasm and mitochondria. This may also leak out from damaged tissues mainly because of hepatocellular necrosis [21-23]. ALP is localized in liver, bile duct, bone, placenta, kidney and intestine. Its cellular localization is the cell membrane. There could be over production and release in blood because of hepatobiliary injury and cholestasis [24,25]. Albumin is produced and localized in liver tissue, and is released into blood plasma. Because of hepatic dysfunction it is decreased in synthesis [26].

In the seeds extract of *A. gummifera* administered group, the serum biochemical parameters analyzed for male rats are not found to be significant. Similarly, all the biochemical parameters analyzed for female rats as compared to the control were found insignificant. This result is in agreement with the previous studies by Saidu and associates [8] on aqueous leaf extract of *Albizia chevalieri* and oral administration of saponins isolated from *Albizia lebeck* bark by Gupta and associates [27] which showed no significant effect on serum liver and kidney function and biochemical parameters. Serum urea was increased at 250 mg/kg body weight as compared to the male control. This indicates the seeds extract of *A. gummifera* may induce renal toxicity in male rats at higher doses. This result is supported by other findings in that drug-induced nephrotoxicity may be gender related [28]. The serum levels of creatinine and urea in different drug-induced nephrotoxicity were higher in males than females [28-31]. Usually urea is increased in acute and chronic intrinsic renal diseases, which is characterized by decrement in effective circulating blood volume within the kidney [32]. This explains why urea level increase in blood is one of the good indicators for kidney damage.

Analysis of the organ weight is usually employed to determine whether the size of the organ has changed, as indicator of the adverse effect of the toxicants on that organ. According to [33], the mean kidney weight of the male rats was higher than those of females in both African giant rats and wistar rats, although the difference was not significant. In addition to these, the mean weight of the right kidney was heavier than that of the left kidney in both African giant rats and wistar rats. In this study, both of plant seeds extracts did not produce any detectable and meaningful change in the organ weight of liver and kidneys in both male and female rats at all doses.



Analysis of the toxic potential of a therapeutic agent on target organs is incomplete without gross and histopathological assessments. It is more rationale that all functional studies in toxicology should be coupled with appropriate morphologic pathology studies. Liver and kidney microscopic pathology serve as important tools for identifying and characterizing liver and kidney injuries respectively, whether or not biochemical and macroscopic changes are also identified. Some of the main patterns of liver injury during hepatotoxicity include zonal necrosis and vascular lesions [34]. Similarly, general pathology of renal structures include glomeruli hyper cellularity which may result from increased intrinsic cells or from accumulation of leukocytes in capillary lumina, tubular necrosis is elicited as manifestations of either local metabolic abnormalities or systemic processes (characterized by loss of brush border staining for proximal cells, diffuse flattening of cells with resulting dilatation of lumina, loss of individual lining cells, and sloughing off of cells into lumina [35]. It is worthwhile to note that the kidneys of African giant rats and wistar rats are reddish brown with the African giant rat having a darker red colour *in vivo* [33].

The present study, rats that were orally administered with repeated doses of the extracts at both 125 mg/kg and 250 mg/kg body weight for both of the plants showed no abnormalities of the liver and kidneys in the post mortem macroscopic evaluation. The present study noted the presence of histopathological changes in the liver and kidney tissue of the seeds extract of *A. gummifera* administered rats. Histopathological changes in the liver at the lowest dose were not detected for *A. gummifera* except for sign of congestion and haemorrhage. But, histopathological changes in the liver at 250 mg/kg body weight showed few pyknotic cells and minor focal necrosis. This result is in agreement with herbal plants like *Atractylis gummifera* and *Callilepis laureola* reported by Larrey [35]. In contrast to the investigation of Larrey [35], rat liver, kidney and heart tissues analysed histopathologically were normal after acute and sub-chronic administration of the aqueous leaf extract of *A. chevalieri* [8]. Such disagreement between the results may be due to absence of compound responsible for toxic insult in the aqueous leaf extract of *A. chevalieri* or duration for administration periods as the aqueous leaf extract of *Albizia chevalieri* has been administered to rats for only about 28 days at a dose between 0-1500 mg/kg body weight. The seeds extract of *A. gummifera* may possess a class of compound that has caused interluminal eosinophilic protein cast, congestion and minor necrosis in the kidney tissue. This is in agreement with previous study on aqueous leaf extract of *A. chevalieri* that elicited congestion and eosinophilic tubular protein cast [8].

## Conclusion

From the present investigation, the hydro-alcoholic seeds extract of *Albizia gummifera* has increased NEUT at 250 mg/kg body weight in both male and female rats. The seeds extract of this plant decreased MCH and increased RDW-CV at both doses in the male rats. Similarly, the extract decreased MCHC at both doses and MCV at higher dose in the female rats. Hence, the hydro alcoholic seeds extract of *A. gummifera* may induce anemia in both male and female rats. All serum chemistry analysed in this study for the seeds extract of the plant were found normal in both male and female rats, except for the elevated serum urea in the male rats at 250 mg/kg body weight. The hydro-alcoholic seeds extract of *A. gummifera* has brought some histopathological alterations in liver such as inflammation at 125 mg/kg body weight and congestions, pyknosis and focal cellular necrosis at the 250 mg/kg body weight. The extract has resulted in

some histopathological alterations in the kidney too, such as protein cast and atrophy of glomeruli at 250 mg/kg body weight.

The present study demonstrated sub-chronic toxicity of hydro-ethanolic seeds extract of *A. gummifera* extract in albino wistar rats. However, further studies are needed to identify active ingredients responsible for toxic insult and mechanism of action of the extract for the toxic effects, to examine the toxic effects of these plants on other organs using similar animal model, to assess the toxic effects of these plants on blood parameters and histopathology of internal organs on other animal models and to investigate if changes observed may also be same in humans.

## References

1. WHO, Traditional medicine strategy 2002-2005. Geneva.
2. Tédong L, Dzeufiet PD, Dimo T, Asongalem EA, Sokeng SN, et al. (2007) Acute and Subchronic toxicity of *Anacardium occidentale* Linn (Anacardiaceae) leaves hexane extract in mice. *Afr J Tradit Altern Med* 4: 140-147.
3. Ogbonnia S, Adekunle AA, Bosa MK, Enwuru VN (2008) Evaluation of acute and subacute toxicity of *Alstonia congensis* Engler (Apocynaceae) bark and *Xylopia aethiopica* (Dunal) A. Rich (Annonaceae) fruits mixtures used in the treatment of diabetes. *Afr J Biotechnol* 7: 701-705.
4. Geyid A, Abebe D, Debella A, Makonnen Z, Aberra F, et al. (2005) Screening of some medicinal plants of Ethiopia for their anti-microbial properties and chemical profiles. *J Ethnopharmacol* 97: 421-427.
5. Woldemicheal T (2003) Screening of some medicinal plants of Ethiopia for their molluscidal activities and phytochemical constituents. *PhOL* 3: 245- 258.
6. Debella A (2007) Screening of some Ethiopian medicinal plants for mosquito larvicidal effects and phytochemical constituents. *Pharmacologyonline* 3: 231-243.
7. Tefera MA, Geyid A, Debella A (2012) In vitro anti-*Neisseria gonorrhoeae* activity of *Albizia gummifera* and *Croton macrostachyus*. *Revista CENIC, Ciencias Biológicas* 41: 1-11.
8. Saidu Y (2007) Acute and sub-chronic toxicity studies of crude aqueous extract of *Albizia chevalieri* Harms (Leguminosae). *Asian J Biochem* 2: 224-336.
9. Karunamoorthi K, Bishaw D, Mulat T (2009) Toxic effects of traditional Ethiopian fish poisoning plant *Milletia ferruginea* (Hochst) seed extract on aquatic macroinvertebrates. *Eur Rev Med Pharmacol Sci* 13: 179-185.
10. Taye B, Giday M, Animut A, Seid J (2011) Antibacterial activities of selected medicinal plants in traditional treatment of human wounds in Ethiopia. *Asian Pac J Trop Biomed* 1: 370-375.
11. Amole O (2006) Toxicity studies of the aqueous extract of *Vernonia amygdalina*. *Biomed Res* 17: 39-40.
12. Kebede H (2011) The Effect of *Clerodendrum Myricoides* Aqueous Extract on Blood, Liver and Kidney Tissues of Mice. *MEJS* : 3.
13. Amacher DE (2002) A toxicologist's guide to biomarkers of hepatic response. *Hum Exp Toxicol* 21: 253-262.
14. Bin-Jaliah I (2014) Derangement of hemopoiesis and hematological indices in Khat (*Cathaedulis*)-treated rats. *Afr J Biotechnol* : 13.
15. Hume R, Dagg JH, Goldberg A (1973) Refractory anemia with dysproteinemia: long-term therapy with low-dose corticosteroids. *Blood* 41: 27-35.
16. Sagone AL Jr, Lawrence T, Balcerzak SP (1973) Effect of smoking on tissue oxygen supply. *Blood* 41: 845-851.
17. Ris MM, Deitrich RA, Von Wartburg JP (1975) Inhibition of aldehyde reductase isoenzymes in human and rat brain. *Biochem Pharmacol* 24: 1865-1869.
18. Sysmex H (2016) Educational enhancement and development. Seed Hematology.



19. Keinänen M, Knuutila S, Bloomfield CD, Elonen E, de la Chapelle A (1986) The proportion of mitoses in different cell lineages changes during short-term culture of normal human bone marrow. *Blood* 67: 1240-1243.
20. Selmanoglu G, Barlas N, Songür S, Koçkaya EA (2001) Carbendazim-induced haematological, biochemical and histopathological changes to the liver and kidney of male rats. *Hum Exp Toxicol* 20: 625-630.
21. Choudhari C, Deshmukh P (2007) Acute and subchronic toxicity study of *Semecarpus anacardium* on Hb% and RBC count of male albino rats. *J Herbal Med and Toxicol* 1: 43-45.
22. Dufour DR, Lott JA, Nolte FS, Gretch DR, Koff RS, et al. (2000) Diagnosis and monitoring of hepatic injury. I. Performance characteristics of laboratory tests. *Clin Chem* 46: 2027-2049.
23. Dufour DR, Lott JA, Nolte FS, Gretch DR, Koff RS, et al. (2000) Diagnosis and monitoring of hepatic injury. II. Recommendations for use of laboratory tests in screening, diagnosis, and monitoring. *Clin Chem* 46: 2050-2068.
24. Ozer J, Ratner M, Shaw M, Bailey W, Schomaker S (2008) The current state of serum biomarkers of hepatotoxicity. *Toxicology* 245: 194-205.
25. Belansky ES, Cutforth N, Chavez R, Crane LA, Waters E, et al. (2013) Adapted intervention mapping: a strategic planning process for increasing physical activity and healthy eating opportunities in schools via environment and policy change. *J Sch Health* 83: 194-205.
26. Saukkonen JJ, Cohn DL, Jasmer RM, Schenker S, Jereb JA, et al. (2006) An official ATS statement: hepatotoxicity of antituberculosis therapy. *Am J Respir Crit Care Med* 174: 935-952.
27. Ramaiah SK (2007) A toxicologist guide to the diagnostic interpretation of hepatic biochemical parameters. *Food Chem Toxicol* 45: 1551-1557.
28. Thapa BR, Walia A (2007) Liver function tests and their interpretation. *Indian J Pediatr* 74: 663-671.
29. Gupta RS, Chaudhary R, Yadav RK, Verma SK, Dobhal MP (2005) Effect of Saponins of *Albizia lebbek* (L.) Benth bark on the reproductive system of male albino rats. *J Ethnopharmacol* 96: 31-36.
30. Bennett WM, Parker RA, Elliott WC, Gilbert DN, Houghton DC (1982) Sex-related differences in the susceptibility of rats to gentamicin nephrotoxicity. *J Infect Dis* 145: 370-373.
31. Goodrich JA, Hottendorf GH (1995) Tobramycin gender-related nephrotoxicity in Fischer but not Sprague-Dawley rats. *Toxicol Lett* 75: 127-131.
32. Halaris AE, Belendiuk KT, Freedman DX (1975) Antidepressant drugs affect dopamine uptake. *Biochem Pharmacol* 24: 1896-1897.
33. Laniado-Laborín R, Cabrales-Vargas MN (2009) Amphotericin B: side effects and toxicity. *Rev Iberoam Micol* 26: 223-227.