

Evaluation of Type 3 Neovascularization Following Anti-Vascular Endothelial Growth Factor Therapy Using Optical Coherence Tomography Angiography

Matthew T Nguyen¹, Jeffrey C Liu², Peter L Nesper² and Manjot K Gill^{2*}

¹Northwestern University Feinberg School of Medicine, Chicago, Illinois, USA

²Department of Ophthalmology, Northwestern University Feinberg School of Medicine, Chicago, Illinois, USA

*Corresponding author: Manjot K Gill, Department of Ophthalmology, Northwestern University Feinberg School of Medicine, Chicago, Illinois, USA, E-mail: mgill@nm.org

Received date: April 11, 2018; Accepted date: April 16, 2018; Published date: April 25, 2018

Copyright: ©2018 Nguyen MT, et al. This is an open-access article distributed under the terms of the Creative Commons Attribution License, which permits unrestricted use, distribution, and reproduction in any medium, provided the original author and source are credited.

Abstract

Objective: To analyze optical coherence tomography angiography (OCTA) imaging of type 3 neovascularization in age-related macular degeneration (AMD) at baseline and following serial anti-vascular endothelial growth factor (anti-VEGF) treatments.

Methods: This retrospective case series describes three treatment-naïve patients diagnosed with type 3 neovascularization secondary to AMD based on clinical examination, fluorescein angiography (FA), and spectral-domain optical coherence tomography (SD-OCT). Written informed consent was obtained from all participants and approved by the Institutional Review Board of Northwestern University. Visual acuity and OCTA imaging with quantitative analysis of the type 3 neovascular complex was obtained at baseline and following monthly intravitreal anti-VEGF injections.

Results: OCTA demonstrated resolution of cystoid macular edema in all three cases following anti-VEGF treatment. In one patient, resolution of the edema allowed enhanced visualization of the type 3 neovascular lesion due to intraretinal fluid obscuration at baseline. One case demonstrated persistence of larger vessels even after multiple anti-VEGF treatments. All cases showed improvement in visual acuity and reduction of type 3 neovascularization area on quantitative OCTA analysis.

Conclusion: OCTA analysis of type 3 neovascularization demonstrated regression of small caliber vessels following longitudinal anti-VEGF treatment. Cystoid macular edema resolved and visual acuity improved in all cases. OCTA supplements fluorescein angiography and spectral domain OCT by providing improved microvascular identification of type 3 lesions and treatment response which may help guide clinician management and patient expectations.

Keywords: Age-related macular degeneration; Anti-VEGF; OCTA; Imaging; Macula; Neovascularization; Retinal angiomatous proliferation; Retina

Introduction

Neovascular age-related macular degeneration (AMD) can be classified into three subtypes corresponding to the anatomical location of vessel proliferation with respect to the retinal pigment epithelium (RPE). Type 3 neovascularization, also referred to as retinal angiomatous proliferation [1] and deep retinal vascular anomalous complex [2], predominantly manifests itself within the neurosensory retina, originating from the retinal deep capillary plexus (DCP) [3-5].

Traditional diagnostic tools for neovascular AMD include spectral-domain optical coherence tomography (SD-OCT) and dye tracing methods such as fluorescein angiography (FA) and indocyanine green angiography (ICGA). However, in cases where the neovascular component of the type 3 lesion is very small, FA and ICGA provide poor definition and delineation [6]. Also, regardless of lesion size, FA

and ICG are fundamentally unable to localize the lesion to the deep networks due to the two-dimensional nature of the image.

Optical coherence tomography angiography (OCTA) is an advanced imaging modality that provides three-dimensional visualization of the retinal and choroidal vasculature *in vivo* by detecting the movement of blood with dense volumetric scanning using amplitude or phase decorrelation technology [7]. Our study aims to utilize OCTA to qualitatively and quantitatively analyze the micromorphology of type 3 neovascular lesions in a cohort of patients before and after intravitreal anti-vascular endothelial growth factor (anti-VEGF) therapy.

Materials and Methods

Patients with type 3 neovascularization were seen and evaluated in the Department of Ophthalmology at Northwestern University in Chicago, Illinois between March 2016 and March 2017. This retrospective case series was approved by the Institutional Review Board (IRB) of Northwestern University (STU00090987), followed the tenets of the Declaration of Helsinki, and was performed in accordance with the Health Insurance Portability and Accountability Act (HIPAA)

regulations. Requirement for informed consent was waived by the IRB due to this study's retrospective nature. The inclusion criteria included treatment naïve patients diagnosed with type 3 neovascularization secondary to AMD by a single retinal specialist (MG).

The diagnosis was based on clinical examination, color fundus photography, fluorescein angiography (FA), and SD-OCT. Snellen visual acuity (VA) was documented at baseline and at all follow-up visits during the study. Anti-VEGF medications were administered at the initial diagnosis and subsequently at each monthly follow-up visit until there was resolution of intraretinal fluid (IRF) and sub-retinal fluid (SRF) per OCT. OCTA scans were obtained using RTVue-XR Avanti system (Optovue Inc., Fremont, California, USA) with split-spectrum amplitude-decorrelation angiography (SSADA) software [8]. All cases had $3 \times 3 \text{ mm}^2$ scans centered on the fovea and were semi-automatically segmented and adjusted to identify the location of the type 3 neovascular lesion. The lesions appeared as an area of hyper-reflective focus on SD-OCT and co-localized with high flow on cross-sectional and en face OCTA images. En face OCTA scans at baseline and after monthly intravitreal anti-VEGF injections were qualitatively and quantitatively compared using identical segmentation parameters to most accurately capture changes in type 3 lesions between treatments.

For quantitative analysis, the built-in AngioVue Analytics software (version 2016.2.0.35) was utilized. The boundaries of the neovascular component of each lesion were manually delineated using the Flow Tool in the manual outer retina segmentation. To reduce measurement bias in flow quantification, the radius in mm^2 on the Flow Tool used at the time of diagnosis for each case was kept similar throughout the study. This allowed for accurate quantification of the area of flow within the lesion, which was compared between visits. Two masked OCTA retina experts (J.L. and P.N.) qualitatively and quantitatively analyzed the OCTA images at baseline and follow-up; cases of disagreement were evaluated by a third independent grader (M.N.).

Results

Case 1

A 69-year-old female with a history of non-neovascular AMD in her left eye presented for retinal evaluation. Baseline Snellen visual acuity (VA) was 20/40 in the left eye. On examination (Figure 1) the macula showed drusen, a blunted foveal reflex, and punctate intraretinal hemorrhages (Figure 1A). FA demonstrated an area of leakage superotemporal to the fovea (Figures 1B and 1C). SD-OCT showed a hyper-reflective lesion extending from the inner nuclear layer (INL) through the outer plexiform (OPL) with surrounding intraretinal fluid (IRF) (Figure 1D).

En face OCTA revealed high flow signal in the corresponding area (Figure 1F), which correlated with the location of the type 3 lesion on FA. Cross-sectional OCTA confirmed abnormal flow signal from the INL to the OPL consistent with the DCP (Figure 1G). The patient received intravitreal aflibercept and was followed monthly. After receiving a total of three monthly intravitreal aflibercept injections, VA improved to 20/20-3 in the affected eye. SD-OCT showed decreased size of the hyper-reflective focus and resolution of the IRF (Figure 1E). The follow-up en face and cross-sectional OCTA scan showed persistent though reduced flow of the type 3 lesion (Figures 1H and 1I). As shown in Figure 2, quantitative analysis demonstrated a slight

decrease in the neovascular lesion area from 0.038 mm^2 to 0.035 mm^2 (Figures 2A and 2B) (Table 1).

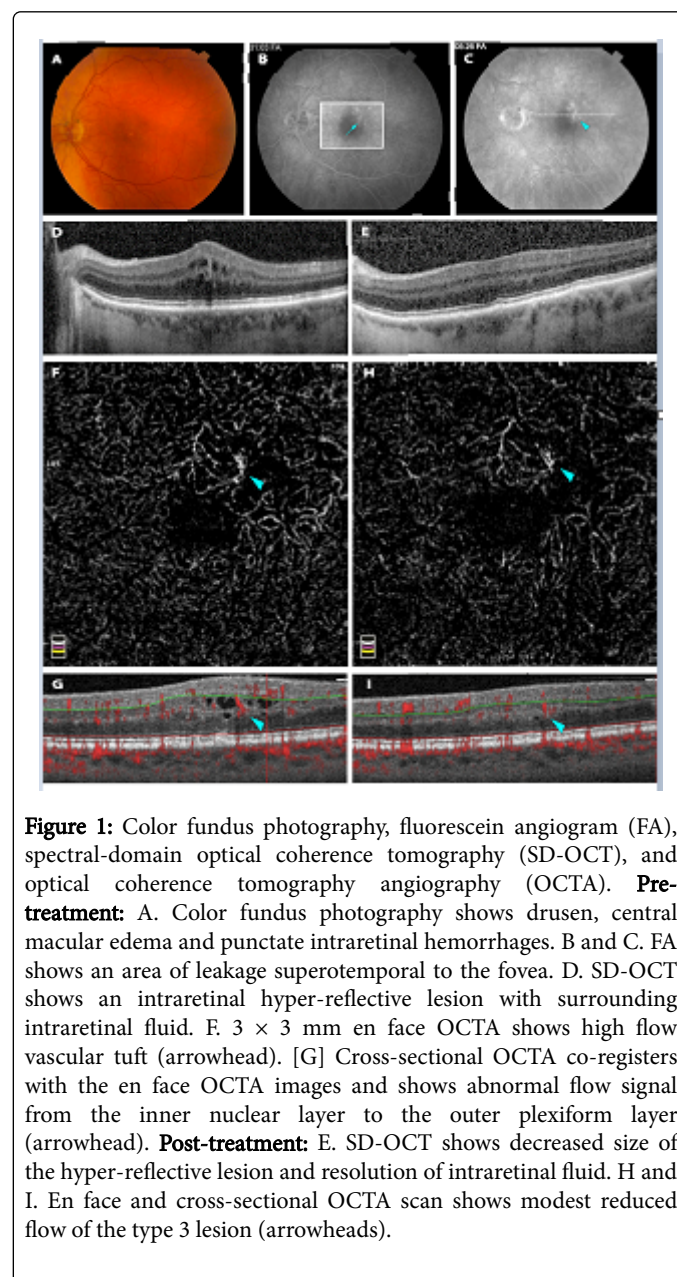


Figure 1: Color fundus photography, fluorescein angiogram (FA), spectral-domain optical coherence tomography (SD-OCT), and optical coherence tomography angiography (OCTA). **Pre-treatment:** A. Color fundus photography shows drusen, central macular edema and punctate intraretinal hemorrhages. B and C. FA shows an area of leakage superotemporal to the fovea. D. SD-OCT shows an intraretinal hyper-reflective lesion with surrounding intraretinal fluid. F. $3 \times 3 \text{ mm}$ en face OCTA shows high flow vascular tuft (arrowhead). [G] Cross-sectional OCTA co-registers with the en face OCTA images and shows abnormal flow signal from the inner nuclear layer to the outer plexiform layer (arrowhead). **Post-treatment:** E. SD-OCT shows decreased size of the hyper-reflective lesion and resolution of intraretinal fluid. H and I. En face and cross-sectional OCTA scan shows modest reduced flow of the type 3 lesion (arrowheads).

Case 2

A 69-y-old female presented for evaluation of a macular hemorrhage in her left eye. VA was 20/400 in the affected eye. Past medical history was positive for Type 2 diabetes mellitus. On examination of her left eye (Figure 3) demonstrated macular intraretinal hemorrhage with evidence of focal leakage on FA (Figures 3A-3C). SD-OCT demonstrated the presence of significant IRF and a small pocket of subretinal fluid (SRF) (Figure 3D). En face OCTA revealed the presence of a vascular lesion within the neurosensory retina consistent with type 3 neovascularization (Figure 3F). Cross-sectional OCTA scans localized the hyper-reflective lesion to the level of the OPL and ONL with confirmed flow signal (Figure 3G).

Intravitreal ranibizumab was initiated with monthly-follow up visits. After receiving a total of five ranibizumab injections VA improved to 20/50-2 and SD-OCT demonstrated complete resolution of SRF, with a significant reduction in IRF (Figure 3E). En face OCTA demonstrated significantly decreased lesion size (Figure 3H).

Case	Pre-treatment		Post-treatment		Reduction in lesion area size %
	Visual acuity	Lesion size (mm ²)	Visual acuity	Lesion size (mm ²)	
1	20/40	0.038	20/20-3	0.035	8
2	20/400	0.099	20/50-2	0.042	57
3	20/150	0.021	20/60-2	Undetectable	100

Table 1: Visual acuity and quantitative analysis of type 3 neovascular lesion area at baseline and following anti-vascular endothelial growth factor treatment.

Cross-sectional OCTA showed a deep hyper-reflective lesion in contact with the RPE, with flow signal that appeared to continue through the RPE and into the sub-RPE space (Figure 3I). Decreased IRF and normalization of the foveal architecture reduced segmentation errors allowing improved visualization of the type 3 neovascular lesion (Figure 3I). Quantitative analysis demonstrated marked decrease in the lesion area from 0.099 mm² to 0.042 mm² (Figures 2C and 2D) (Table 1). Note the location of the scan was moved slightly inferiorly on the follow-up visit.

Case 3

An 80-year-old female with a history of type 3 neovascularization and end-stage disciform scarring of the left eye and non-neovascular AMD of the right eye, presented with acute onset decreased vision in her right eye with VA 20/150. On examination of the right eye (Figure 4) revealed macular hemorrhage nasal to the fovea with edema and extensive reticular pseudodrusen (Figure 4A). Early-phase FA demonstrated blocked fluorescence at the site of intraretinal hemorrhage (Figure 4B) with late-phase FA showing leakage around the intraretinal hemorrhage (Figure 4C). SD-OCT showed small hyper-reflective foci with IRF overlying hyper-reflective material representing the intraretinal hemorrhage (Figure 4D). While the type 3 neovascular lesion was not very pronounced on en face OCTA (Figure 4F), the cross-sectional OCTA (Figure 4G) demonstrated a small focal area of flow corresponding to the lesion at the level of the deep/outer retina and overlying the hyper-reflective intraretinal hemorrhage. The patient received an injection of bevacizumab and returned approximately six weeks later. On follow-up, VA improved to 20/60-2 in the affected eye. Clinical examination revealed resolution of the intraretinal hemorrhage and SD-OCT showed resolved IRF (Figure 4E). Cross-sectional OCTA scans also demonstrated no identifiable flow signal at the corresponding level of the retina that was observed pre-treatment (Figure 4I). En face and quantitative OCTA analysis showed a pre-treatment type 3 neovascular lesion area of 0.021 mm² that was undetectable after a single anti-VEGF injection (Figure 4H and Figures 2E and 2F) (Table 1).

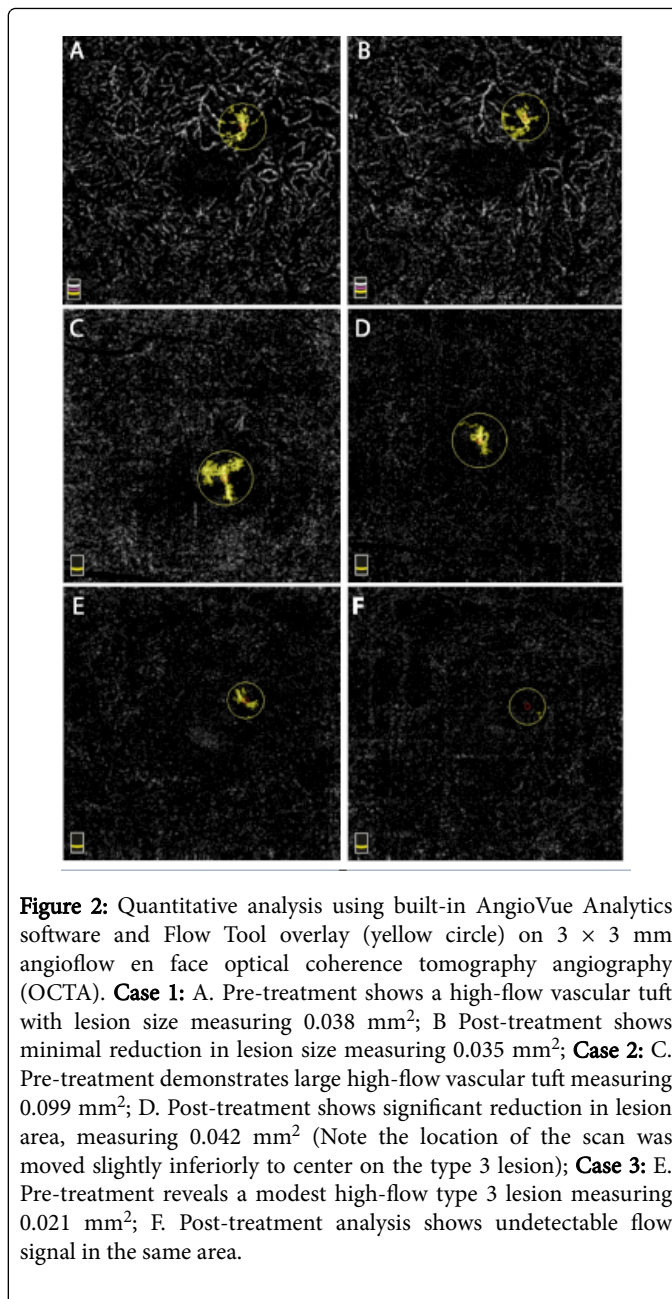


Figure 2: Quantitative analysis using built-in AngioVue Analytics software and Flow Tool overlay (yellow circle) on 3 × 3 mm angioflow en face optical coherence tomography angiography (OCTA). **Case 1:** A. Pre-treatment shows a high-flow vascular tuft with lesion size measuring 0.038 mm²; B Post-treatment shows minimal reduction in lesion size measuring 0.035 mm²; **Case 2:** C. Pre-treatment demonstrates large high-flow vascular tuft measuring 0.099 mm²; D. Post-treatment shows significant reduction in lesion area, measuring 0.042 mm² (Note the location of the scan was moved slightly inferiorly to center on the type 3 lesion); **Case 3:** E. Pre-treatment reveals a modest high-flow type 3 lesion measuring 0.021 mm²; F. Post-treatment analysis shows undetectable flow signal in the same area.

Discussion

This retrospective case series demonstrates the utility of OCTA to qualitatively and quantitatively follow type 3 neovascular lesions and assess their response to anti-VEGF injections.

Case 1 demonstrated a type 3 lesion that was weakly detected on FA and SD-OCT by a hyper-reflective focus, however, en face OCTA clearly detected the vascular lesion with abnormal flow signal localized to the DCP on cross-sectional OCTA. While qualitative observation showed a reduction in hyper-reflectivity of the type 3 lesion following three aflibercept injections over 4.5 months, quantitative analysis showed mild reduction in lesion area.

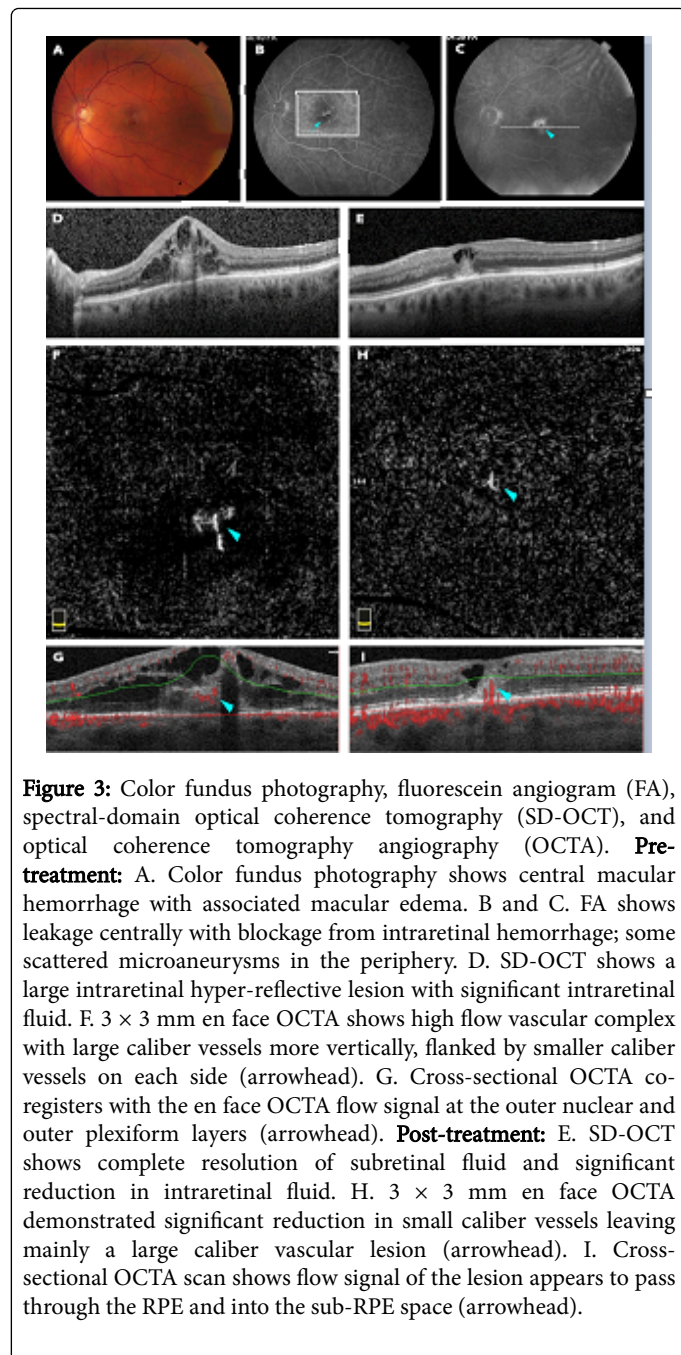


Figure 3: Color fundus photography, fluorescein angiogram (FA), spectral-domain optical coherence tomography (SD-OCT), and optical coherence tomography angiography (OCTA). **Pre-treatment:** A. Color fundus photography shows central macular hemorrhage with associated macular edema. B and C. FA shows leakage centrally with blockage from intraretinal hemorrhage; some scattered microaneurysms in the periphery. D. SD-OCT shows a large intraretinal hyper-reflective lesion with significant intraretinal fluid. F. 3 × 3 mm en face OCTA shows high flow vascular complex with large caliber vessels more vertically, flanked by smaller caliber vessels on each side (arrowhead). G. Cross-sectional OCTA co-registers with the en face OCTA flow signal at the outer nuclear and outer plexiform layers (arrowhead). **Post-treatment:** E. SD-OCT shows complete resolution of subretinal fluid and significant reduction in intraretinal fluid. H. 3 × 3 mm en face OCTA demonstrated significant reduction in small caliber vessels leaving mainly a large caliber vascular lesion (arrowhead). I. Cross-sectional OCTA scan shows flow signal of the lesion appears to pass through the RPE and into the sub-RPE space (arrowhead).

Phasukkijwatana et al. [9] identified large feeder vessels on OCTA that persist even after anti-VEGF therapy. These vessels have been shown to anastomose with the type 3 lesions, perfusing the entire complex. As feeder vessels and type 3 lesion complexes mature and become more established, it is postulated that the lesion may become more resistant to treatment [10]. In our case, the type 3 neovascular lesion responded well to aflibercept with reduced exudation and resolution of IRE, however, the presence of feeder vessels may explain the mild reduction in the overall size of the lesion that was observed. Case 2 demonstrated marked improvement in response to five anti-VEGF injections with normalization of the retinal architecture at 5 months follow-up. This case corroborates the usefulness of OCTA in following and managing type 3 lesions longitudinally: while FA and

SD-OCT noted retinal architectural stabilization, OCTA clearly detected the persistence of the type 3 neovascular lesion in the DCP. Interestingly, the follow-up cross-sectional OCTA demonstrated flow signal from the outer retina through the RPE into the sub-RPE space.

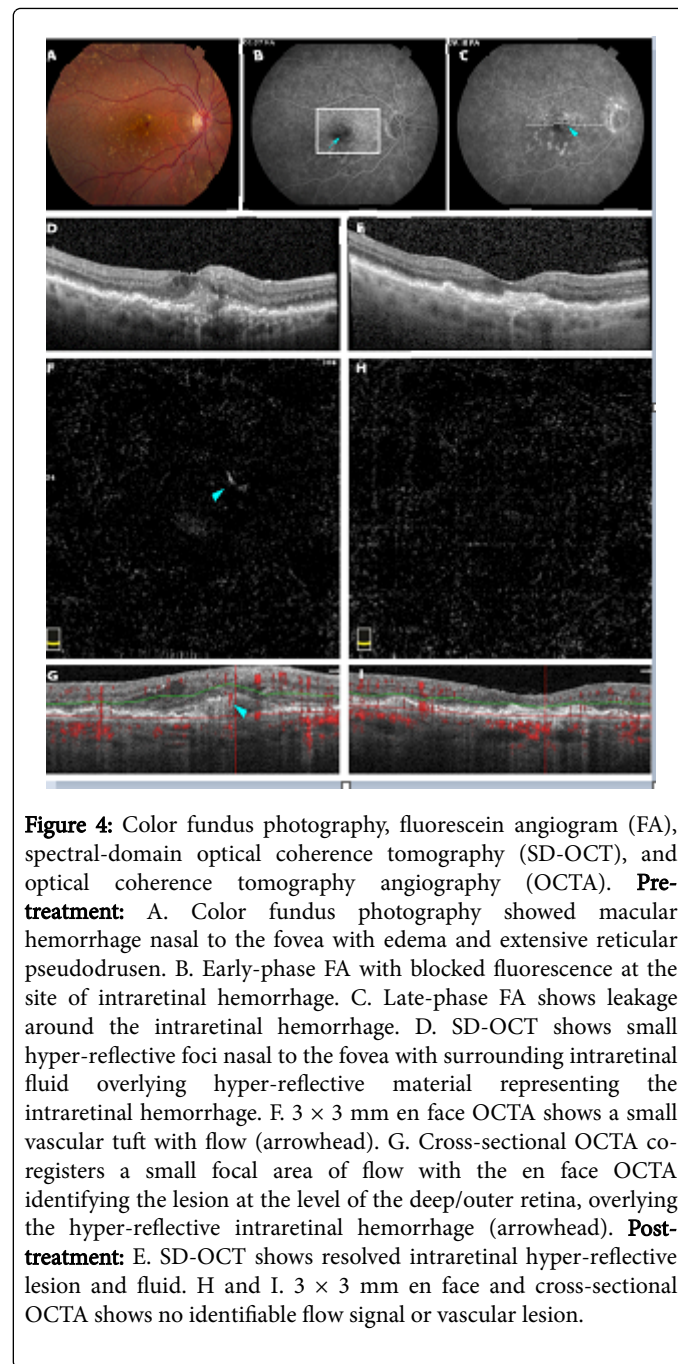


Figure 4: Color fundus photography, fluorescein angiogram (FA), spectral-domain optical coherence tomography (SD-OCT), and optical coherence tomography angiography (OCTA). **Pre-treatment:** A. Color fundus photograph showed macular hemorrhage nasal to the fovea with edema and extensive reticular pseudodrusen. B. Early-phase FA with blocked fluorescence at the site of intraretinal hemorrhage. C. Late-phase FA shows leakage around the intraretinal hemorrhage. D. SD-OCT shows small hyper-reflective foci nasal to the fovea with surrounding intraretinal fluid overlying hyper-reflective material representing the intraretinal hemorrhage. F. 3 × 3 mm en face OCTA shows a small vascular tuft with flow (arrowhead). G. Cross-sectional OCTA co-registers a small focal area of flow with the en face OCTA identifying the lesion at the level of the deep/outer retina, overlying the hyper-reflective intraretinal hemorrhage (arrowhead). **Post-treatment:** E. SD-OCT shows resolved intraretinal hyper-reflective lesion and fluid. H and I. 3 × 3 mm en face and cross-sectional OCTA shows no identifiable flow signal or vascular lesion.

While we acknowledge that the posterior flow extensions may represent projection artifacts, these observations may represent type 3 lesion originating from the DCP in the neurosensory retina can later develop retinal-choroidal anastomoses [11,12]. Quantitative analysis with OCTA demonstrated a pronounced reduction in lesion area with regression of smaller caliber vessels leaving behind more resistant large caliber neovascularization with possible feeders from retinal-choroidal anastomoses. This is in contrast to the intraretinal feeder vessels noted in Case 1. These findings add further support to the utility of OCTA in

analyzing the morphologic changes of type 3 neovascular lesions and response to anti-VEGF treatment.

Case 3 showed the most dramatic recovery, with disappearance of the type 3 neovascular lesion following a single bevacizumab injection. This case corroborated the findings of previous studies [9,13] that describe the highly responsive nature of type 3 neovascular lesions to anti-VEGF treatment, verifying the importance of VEGF in the angiogenesis and persistence of Type 3 neovascularization complexes. The type 3 neovascular lesion in our case revealed a subtle focal hyper-reflective flow on en face OCTA with corresponding flow signal on cross-sectional images. This may represent an earlier stage and activity of the lesion. Early type 3 lesions appear especially sensitive to anti-VEGF treatment, with the potential for complete regression [8], in comparison to the lesions described in Cases 1 and 2. Miere et al. [14] demonstrated in 7/15 of their patients with early type 3 neovascularization a complete disappearance of the initial tuft-shaped flow signals at 12 months follow-up. Our study observed disappearance of the type 3 lesion at 6 weeks follow-up, demonstrating the potentially more rapid response of an early type 3 neovascular complex to anti-VEGF therapy.

By identification of the micromorphology, these cases support the supplemental benefit of OCTA imaging in the evaluation and management of type 3 neovascularization. Furthermore, the non-invasive nature and ease of acquisition make OCTA a viable option for following patients with this disease. The potential for quantitative analysis and measurement of the lesion size is also promising. However, the utility of OCTA in a busy clinical setting is not without its challenges. Segmentation errors due to retinal pathology can be misleading and require meticulous attention when assessing OCTA images. Motion artifacts that result in distorted images can also be problematic and may be more prevalent in the elderly population who may have trouble with fixation. Furthermore, large superficial retinal vessels, hemorrhage and the presence of IRF can lead to projection artifacts upon the deeper retinal layers [15], making interpretation difficult.

In conclusion, this retrospective case series establishes the added utility of OCTA in not only surveying the microvascular morphology of type 3 lesions, but also quantifying the lesion area in response to anti-VEGF injections longitudinally. In all cases there was improvement in VA, resolution of cystoid macular edema and type 3 lesion size reduction compared to baseline. Early type 3 neovascular lesion complexes seem to exhibit the greatest sensitivity to anti-VEGF therapy, with the potential for complete vascular regression whereas more mature lesions demonstrate greater resistance to therapy highlighting the benefit of OCTA to allow for earlier detection of type 3 lesions. Our study exemplifies the promise of OCTA as a supplementary modality to FA and SD-OCT to both qualitatively and quantitatively evaluate type 3 neovascularization in AMD patients and their response to treatment.

Conflict of Interest

The authors have no financial or conflicts of interest to disclose.

Acknowledgements and Disclosures

Funding: Supported in part by an unrestricted grant from Research to Prevent Blindness.

Research instrument support for this work was provided by Optovue, Inc. The funders had no role in study design, data collection and analysis, decision to publish, or preparation of the manuscript.

Authorship: All authors attest that they meet the current ICMJE criteria for Authorship.

References

1. Yannuzzi L, Negro S, Iida T, Carvalho C, Rodriguez-Coleman H, et al. (2012) Retinal angiomatous proliferation in age-related macular degeneration. *Retina* 21: 416-434.
2. Hartnett ME, Weiter JJ, Staurengi G, Elsner AE (1996) Deep retinal vascular anomalous complexes in advanced age-related macular degeneration. *Ophthalmology* 103: 2042-2053.
3. Freund K, Ho IV, Barbazetto I, Koizumi H, Laud K, et al. (2008) Type 3 neovascularization: the expanded spectrum of retinal angiomatous proliferation. *Retina* 28: 201-211.
4. Querques G, Souied E, Freund K (2015) How has high-resolution multimodal imaging redefined our understanding of the vasogenic process in type 3 neovascularization? *Retina* 35: 603-613.
5. Nagiel A, Sarraf D, Sadda S, Spaide R, Jung J, et al. (2015) Type 3 neovascularization: evolution, associated with pigment epithelial detachment, and treatment response as revealed by spectral domain optical coherence tomography. *Retina* 35: 638-647.
6. Spaide R, Klancnik Jr J, Cooney M (2015) Retinal vascular layers imaged by fluorescein angiography and optical coherence tomography angiography. *JAMA Ophthalmology* 133: 45-50.
7. Makita S, Hong Y, Yamanari M, Yatagai T, Yasuno Y (2006) Optical coherence angiography. *Opt Express* 14: 7821-7840.
8. Jia Y, Tan O, Tokayer J, Potsaid B, Wang Y, et al. (2012) Split-spectrum amplitude-decorrelation angiography with optical coherence tomography. *Opt Express* 20: 4710-4725.
9. Phasukkijwatana N, Tan A, Chen X, Freund K, Sarraf D (2017) Optical coherence tomography angiography of type 3 neovascularization in age-related macular degeneration after antiangiogenic therapy. *Br J Ophthalmol* 101: 597-602.
10. Freund K, Zweifel S, Engelbert M (2010) Do we need a new classification for choroidal neovascularization in age-related macular degeneration? *Retina* 30: 1333-1349.
11. Miere A, Querques G, Semoun O, El Ameen A, Capuano V, et al. (2015) Optical Coherence Tomography Angiography in early type 3 Neovascularization *Retina* 35: 2236-2241.
12. Tan A, Dansingani K, Yannuzzi L, Sarraf D, Freund K (2017) Type 3 Neovascularization imaged with cross-sectional and en face optical coherence tomography angiography. *Retina* 37: 234-246.
13. Kuehlewein L, Dansingani KK, de Carlo TE, Bonini Filho M, Iafe N, et al. (2015) Optical coherence tomography angiography of type 3 neovascularization secondary to age-related macular degeneration. *Retina* 35: 2229-2235.
14. Miere A, Querques G, Semoun O, Amoroso F, Zambrowski O, et al. (2017) Optical coherence tomography angiography changes in early type 3 neovascularization after anti-vascular endothelial growth factor treatment. *Retina* 37: 1873-1879.
15. de Carlo T, Romano A, Waheed N, Duker J (2015) A review of optical coherence tomography angiography (OCTA). *Int J Retina Vitreous* 1: 5.