

Research Article

Open Access

Effectiveness of the *Androctonus Australis* Hector Nanobody NbF12-10 Antivenom to Neutralize Significantly the Toxic Effect and Tissue Damage Provoked by Fraction of *Androctonus mauretanicus* (Morocco) Scorpion Venom

Chgoury F^{1,4*}, Benabderrazek R², Tounsi H³, Oukkache N¹, Hmila I², Boubaker S³, Ayeb ME², Saïle R⁴ Ghalim N¹ and Bouhaouala-Zahar B^{2,5*}

¹Laboratory of Venoms and Toxins, Institut Pasteur du Maroc, 1- Place Louis Pasteur, Casablanca 20360, Morocco

²Laboratory of Venoms and Therapeutic Molecules, Pasteur Institute of Tunis/University of Tunis El Manar, 13 Place Pasteur, BP74, 1002 - Tunis, Tunisia

³Laboratory of Human and Experimental Pathology, Pasteur Institute of Tunis/University of Tunis El Manar, 13 Place Pasteur, BP74, 1002 - Tunis, Tunisia

⁴Laboratory of Biology and Health, URAC 34, Hassan II University Casablanca, Faculty of Science Ben M'sik, Morocco

⁵Medical School of Tunis, 15 Rue Djebel Lakhthar, La Rabta 1007, Tunis-Tunisia-University of Tunis El Manar

Abstract

Scorpion stings are life threatening in large parts of the world. Toxins from scorpion venom are responsible for severe metabolic and tissue disruption and immunotherapy is the only specific treatment able to neutralize the toxic effects of scorpion venom. The *Androctonus mauretanicus* (Am) is the most dangerous scorpion in Morocco, whereas in Tunisia *Androctonus australis hector* (Aah) is causing most casualties. In this work, we investigated the potential of NbF12-10, a new immunotherapeutic concept based on anti-toxin Nanobodies (Nbs) to neutralize Am scorpion venom. We first explored the immune cross-reactivity between Am and Aah scorpions venoms using anti-Aahl and anti-AahlII polyclonal, NbAahl'F12 (anti-Aahl'), monospecific NbAahlII10 (anti-AahlII) monospecific and bispecific NbF12-10 (anti-Aahl'/anti-AahlII) monoclonal antibodies and subsequently we study the histological damages observed after envenomation with the F3 toxic fraction of Am scorpion venom by intra-cerebroventricular (i.c.v) injection and the capacity of NbF12-10 to reduce tissue damage induced by F3 fraction after i.c.v administration of F3:NbF12-10 mixture, in mice. Results showed significant para-specific activity of anti-Aahl polyclonal and monoclonal antibodies towards Am venom fractions. Histological investigations revealed severe tissue damage in brain, lung and liver after i.c.v. administration of F3 fraction. The NbF12-10 pre-mixed with F3 fraction showed an efficient neutralizing capacity against lethal effect of this toxic fraction. Moreover, *in vitro* pre-incubation of F3 with NbF12-10 at 8-fold molar excess led to significantly reduced tissue damage. Further, NbF12-10 displays a noteworthy potential to neutralize Am toxins and to rescue 50% of envenomed mice from dying. This study provides first evidence that NbF12-10 nano-therapeutic has promising prospective to treat scorpion envenoming in the Maghreb area.

Keywords: Scorpion venom; Damage tissue; Nanobody; Immune cross-reactivity

Abbreviations

Aah: *Androctonus australis hector*; Aahl-Aahl'-AahlII: Toxins of Aah Venom; Am: *Androctonus mauretanicus*; BSA: Bovin Serum Albumin; ELISA: Enzyme-Linked Immuno Sorbent Assay; F3: Gel Filtration Toxic Fraction of Am Venom; HCABs: Heavy-Chain Antibody; i.c.v: Intra-Cerebroventricular; MW: Molecular Weight; Nbs: Nanobody; PBS: Phosphate Buffer Saline; scFv: Single Chain Variable Fragment; SDS-PAGE: Sodium Dodecyl Sulfate Polyacrylamide Gel; VHH: variable domain of the heavy chain of a HCAB; ng: nanogram

Introduction

Envenoming by stings from dangerous scorpions constitute a frequent medical emergency and an important public health problem in many countries [1-8]. In Maghreb countries, this so-called scorpionism, is considered as a major public health problem (Direction du soin et de santé de base, DSSB, Ministère de la santé-Tunisie; Centre antipoison et de pharmacovigilance-Ministère de la santé-Morocco [9]). Various scorpion species are encountered in these regions. For the *Androctonus* genus, the *Androctonus mauretanicus mauretanicus* (Amm) renamed *Androctonus mauretanicus* (Am) is endemic exclusively in the arid region of Morocco (i.e. Marrakech-Tensit-Al Haouz) [6], whereas the natural biotope of *Androctonus australis hector* (Aah) is in south of Tunisia. The *Buthus* scorpion genus has the widest spreading throughout the Maghreb. Both Am and Aah sub-species are

responsible for the majority of stings, especially in children [4,10]. It is well established that the toxicity of scorpion venom is mainly due to the fast diffusion of toxins throughout the body [11,12]. These toxins affect ionic channels (i.e. Na⁺, K⁺ Ca²⁺ or Cl⁻ channels) and modulate the transmission of nervous impulses by increasing the discharge of mediators (catecholamines, cytokines, neuropeptide...) causing the release of metabolic serum biomarkers and tissue damages [13-17]. Sodium channel specific toxins are the most represented venom proteins that have been structurally defined and classified in different antigenic groups as identified by polyclonal antibodies. Among these toxins, Amm V is one of the most abundant (46% of the whole Amm venom) and active toxin displaying a 75% sequence identity with

***Corresponding authors:** Fatima Chgoury, Laboratory of Venoms and Toxins, Institut Pasteur du Maroc, 1- Place Louis Pasteur, Casablanca 20360, Morocco Balkiss Bouhaouala-Zahar, Medical School of Tunis, 15 Rue Djebel Lakhthar, La Rabta 1007, Tunis-Tunisia-University of Tunis El Manar Tel: +212-662-472-795, +216-983-452-65; Fax: +212-522-260-957, +212-71-791-833; E-mail: fchgoury@gmail.com, balkiss.bouhaouala@gmail.com

Received June 15, 2014; Accepted June 25, 2015; Published June 29, 2015

Citation: Chgoury F, Benabderrazek R, Tounsi H, Oukkache N, Hmila I, et al. (2015) Effectiveness of the *Androctonus Australis* Hector Nanobody NbF12-10 Antivenom to Neutralize Significantly the Toxic Effect and Tissue Damage Provoked by Fraction of *Androctonus mauretanicus* (Morocco) Scorpion Venom. *Biochem Pharmacol* (Los Angel) 4: 174. doi:10.4172/2167-0501.1000174

Copyright: © 2015 Chgoury F, et al. This is an open-access article distributed under the terms of the Creative Commons Attribution License, which permits unrestricted use, distribution, and reproduction in any medium, provided the original author and source are credited.

AahII [18,19]. However, mass spectrometry analysis of Amm and Aah scorpion venoms revealed other compounds with molecular weight of about 7 kDa. Experimental data has well established that polyclonal antibodies exhibit a cross reactivity to toxins with more than 40% amino acid sequence identity (i.e., AahII/AmmV/AmmVIII) [20]. However, the idea of the cross neutralizing capacity of polyclonal antibodies has been challenged [21].

To combat clinical symptoms of such hazardous disease, it is absolutely essential to administer the venom-specific antibody as soon as possible after an effective scorpion envenoming. In Tunisia, the use of F(ab)² polyclonal antibodies obtained from hyper-immunized horses (with Aah and Bot venoms) is currently recommended as therapy for severe cases, in hospitals. In Morocco, a similar treatment was applied till 2000. Indeed, Fab fragments were also used in some clinical studies [22]. However, the neutralizing potency as well as the specificity of F(ab)² or Fab against scorpion toxins were limited due to their polyclonal origin and bio-distribution properties [10,12], [23-25]. Hence, the treatment could fail to rescue patients that are severely envenomed because of the very fast diffusion of scorpion toxins reaching their targets and causing major complications (i.e., pulmonary edema, and respiratory disorder) [26-28] and heart failures [29,30].

In order to improve the immunotherapy against scorpion envenoming, we explored the performance of a novel small antibody fragment that diffuses more rapidly in tissues. This product is derived from the unique Heavy-chain only antibodies (HCAbs) occurring in Camelidae and comprises a single-domain, antigen-binding fragment known as VHH, also referred to as Nbs [31]. Interestingly, the Nbs share a high sequence identity with human VH of family III [32,33]. From VHH library screenings, several Nbs have been retrieved using phage display technology, from which we further selected NbAahI'F12 and NbAahII10 against AahI' and AahII toxins, respectively [34-36]. The corresponding bispecific NbF12-10 format of only 29 kDa yielded a therapeutic compound with a strong protective capacity against the whole Aah venom in mice [35].

However, the potential of NbF12-10 to neutralize venoms of other scorpions such as that from *Androctonus mauretanicus* scorpion, living in Morocco remains unexplored. Turning this challenge into practice, we first investigated the para-specificity by testing the capacity of polyclonal (anti-AahI and anti-AahII), monoclonal (NbAahI'F12 and NbAahII10) and bispecific antibodies (NbF12-10) to recognize and to bind Am venom compounds of black Morocco scorpion, using an ELISA assay. Thereafter, we assessed the potency of NbF12-10 to reduce histological lesions, observed in vital organs, after experimental pre-incubation with the most toxic fraction from Am venom. Our data demonstrate the capacity of NbF12-10 to reduce fatal disturbances provoked by a lethal dose of toxic fraction from Moroccan scorpion venom.

Materials and Methods

Animals

Male Swiss mice (20 ± 2 g) were housed under controlled temperature in the animal breeding unit at Pasteur Institute of Tunis. Animals used for toxicity assays and histological experiments were approved by the institution Research Board of the Pasteur Institute of Tunis and carried out according to the European Community Council Directive (86/609/EEC) for experimental animal care and procedures.

Scorpion venom

The venom of *Androctonus mauretanicus* individual scorpions was collected at the Pasteur institute of Morocco using electrical stimulation. The lyophilized venom was diluted in cold water (2 v/v) and centrifuged for 15 min at 4°C to remove lipid compounds and debris. The venom supernatant was stored at -20°C. The protein concentration was determined according to the Bradford method [37] using and BSA (Bovine serum albumin) as standard and the Bio-Rad reagent.

Production of polyclonal antibodies

Immune sera against AahII and AahI, the most active toxins from Aah scorpion venom, were expressed by immunizing New Zealand rabbits as described previously [38]. After collection of pre-immune sera, each animal was first injected intradermally at 10 µg of toxin (AahI or AahII) in Freund's Adjuvant complete (Sigma) and then, rabbit received two injections of 10 µg and two injections of 15 µg of toxins in Freund's Adjuvant incomplete (Sigma) through the subcutaneous route every 3 weeks.

Production of nanobodies

The production and purification of Nanobodies (i.e., NbAahI'F12, NbAahII10 and NbF12-10) was according to previously reported protocols [34,35]. Briefly, the clone harboring the gene for the AahI', the AahII or the bispecific NbF12-10 protein was cultured separately in shaker flasks with Terrific Broth supplemented with 100 µg ampicillin/ml and 0.1% glucose, until the absorbance at 600 nm reached a value between 0.6 and 0.9. At this time, the recombinant protein expression was induced with 1 mM isopropyl-thiogalactopyranoside and incubation for at least 16 h at 28°C. From the periplasmic compartment, proteins were extracted by osmotic shock [39] and loaded on a Ni-NTA super-flow Sepharose column (Qiagen). The purity of His-6 tagged NbF12-10 was checked by sodium dodecyl sulfate polyacrylamide gel electrophoresis (SDS-PAGE) and the final yield was monitored from the UV absorption at 280 nm and the theoretical extinction coefficient of the Nb, calculated from its amino acid content, as previously described [35].

Gel-filtration chromatography of venom

The supernatant of the Am venom was loaded on a Sephadex G50 column (2.6 × 100 cm) (Sigma) for size exclusion chromatography using 1.6 M acetic acid as equilibration and running solution (28 ml/h) according to Miranda et al. [40] with minor modifications [41]. Fractions (2.5 ml/tube) were collected in a fraction collector (Frac-920, GE). Absorbance was assessed at 280 nm using a spectrophotometer (Beckman DU 640-UV/Visible). Pooled fractions were stored at -20°C till used for toxicity and histological assays.

In vivo assay

The toxicity of scorpion venom Am and derived fractions was measured in mice by i.c.v injection. The LD₅₀ represents as amount of venom or toxic fraction leading to 50 % of mice surviving the injection [34,36]. Survivors were counted after 24h.

Polyacrylamide gel electrophoresis

Determination of molecular weight (MW) of Am venom and its toxic fraction F3 were performed in sodium dodecyl sulfate-containing polyacrylamide gels [42]. SDS-PAGE was performed under reducing conditions. Proteins were stained with Coomassie brilliant blue.

Immunological tests: indirect ELISA

ELISA were carried out using anti-AahI, anti-AahII specific polyclonal antibodies, NbAahI'F12 and NbAahII10 monospecific and NbF12-10 bispecific nanobodies, following standard protocols to explore their antigenic cross-reactivity against Am scorpion whole venom as well as F2 and F3 toxic fractions of Am venom. Micro titer 96 wells plates (Nunc Maxisorp Plate) were coated overnight at 4°C with 100 µl of 1 µg/ml of Am venom, F2 or F3 fractions in PBS buffer (Phosphate-Buffered-Saline). After washing with 0.1% Tween-PBS, the residual protein binding sites were blocked with 3 % milk in PBS, for 1 hr at 37°C. Subsequently, after washing steps as before, 100 µl of primary antibody (i.e. mouse anti-AahI or anti-AahII polyclonal antibodies, kind gift from Dr Christiane Devaux) or NbAahI'F12, NbAahII10 and NbF12-10 monoclonal antibodies) (at appropriate dilution or concentration as indicated below) were added. After a washing step, secondary peroxidase conjugated antibody (i.e. rabbit anti-mouse IgG (Sigma) or mouse anti-his-6 clone BMG-His-1, Roche laboratory, as appropriate) were added. After washing, ortho-phenylenediamine dihydrochloride-H₂O₂ (Sigma) was added as substrate and the reaction was stopped using 2N sulfuric acid. Absorbance was measured with a spectrophotometer (Multiskan EX, Thermo Electron Corporation) at 492 nm. All samples were applied in duplicate and ELISA procedures were repeated three times. All polyclonal antibodies concentrations have been adjusted to give similar optical density readout in the ELISA.

Pathophysiological study of F3 fraction from Am scorpion venom in mice

To highlight the tissue damage induced by F3 fraction, three groups of 4 mice were used. The first group as control received physiological saline. Second and third groups were challenged with 30 and 35 ng of F3 toxic fraction, an amount corresponding to 2 and 2.3 LD₅₀ respectively. All injections were carried out intra-cerebroventricularly. The levies of organs: brain, lungs and liver were performed in postmortem animals.

In vivo neutralizing of the F3 toxic fraction with NbF12-10

To investigate the *in vivo* neutralizing capacity of NbF12-10 against toxic effect of F3 fraction, five groups of mice were injected with two lethal doses of F3 fraction: 30 and 35 ng (corresponding to 2 and 2.3 LD₅₀) pre-incubated for 1 hour at 37°C with NbF12-10 at molar ratios in cascade from 1:1 to 1:8 molar excess of NbF12-10 dose (Table1).

Organs: brain, lungs and liver were conducted in postmortem animals or in survivors after 24 hours of experimentation.

Experimental conditions for histological analysis

To analyze the histopathological effect on tissues induced by the F3 fraction of Am scorpion venom and the effectiveness of the NbF12-10 to neutralize the F3 that we checked for possible reduced tissue damage after i.c.v. injection of F3 toxins pre-incubated with the bispecific Nb construct. Brain, lung and liver were extracted from control animals, envenomed mice or treated with F3:NbF12-10 mixture. The organs

Group of four mice	LD ₅₀ (F3 fraction)	Molar ratio F3:NbF12-10
1	2	1:1
2	2	1:2
3	2	1:4
4	2.3	1:4
5	2.3	1:8

Table 1: Different molar ratios of F3 : NbF12-10 pre-incubated mixtures. Each mixture is administered by i.c.v route in mice

were fixed in 10 % formalin solution, embedded in paraffin, sliced (2 to 4 µm) and stained with hematoxylin-eosin for microscopic analysis using a Carl Zeiss Axioskop 50 microscope (Germany).

Statistical analysis

Significance of the differences in the immune-reactivity towards Am venom and its fractions F2 and F3 of the polyclonal (anti-AahI, anti-AahII) and monoclonal antibodies (NbF12-10, NbAahI'F12 and NbAahII10) was assessed by Student's t-test (the level of significance was p < 0.05).

Results

Venom fractions

The fractionation of soluble Am venom by gel filtration on Sephadex G50 shows six distinct fractions: F1-F6 (Figure 1). Bradford protein quantification showed that F3 (15 µg/µl of protein) fraction represents 41.15% of the venom proteins (Figure 2).

In vivo toxicity assay

The toxicity of F1, F2 or F3 fractions was assessed in mice by i.c.v injection of different amounts (between 5 ng to 2 µg) into Swiss mice (weighting 18-20 g). The number of surviving mice was monitored at 24 hr after toxin injection. As negative control, mice received only

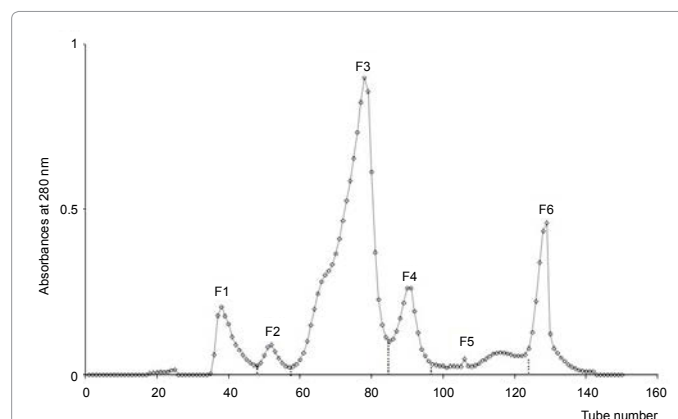


Figure 1: Size exclusion chromatography profile on Sephadex G50 of *Androctonus mauretanicus* scorpion venom. The soluble venom was fractionated using a 2.6 x 100 cm column and fractions were eluted with acetic acid 1.6 M.

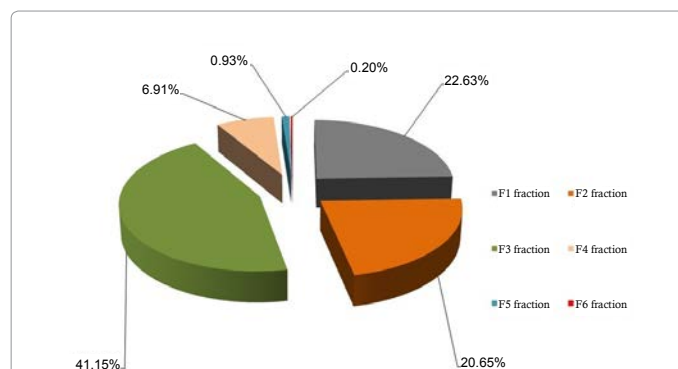
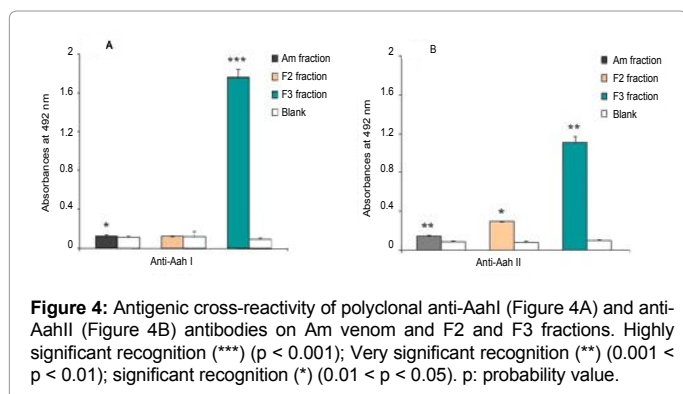
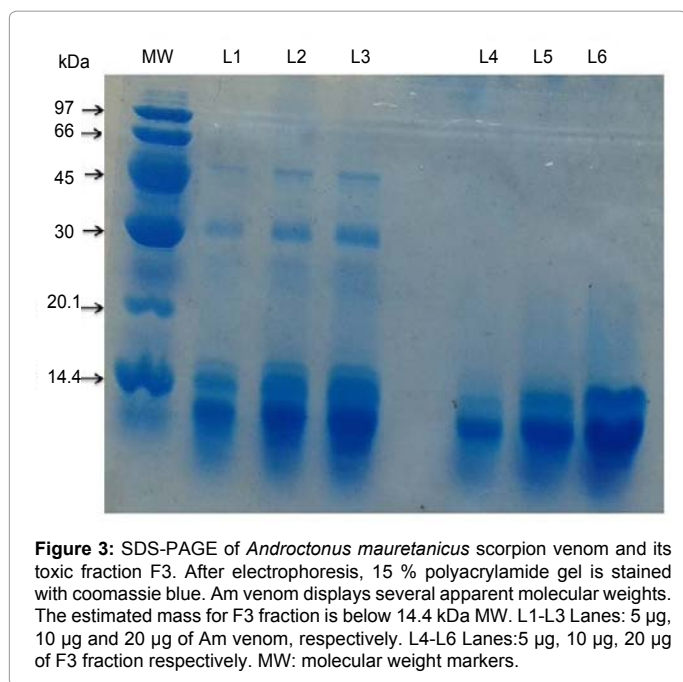


Figure 2: Representative yield of Am venom fractions acquired by gel filtration on SephadexG50 column, in percentages. F1 to F6 represent the eluted fractions from Am venom fractionation.

physiological solution (NaCl 0.9%). Results showed that F1 is not toxic below 2 µg injected per mouse while F2 causes envenoming symptoms, no mortality was recorded. In contrast, F3 is causing highly toxic symptoms and mortality. The LD₅₀ of F3 fraction was estimated (using cohorts of 4 mice) to approximately 15 ng/mouse. F4 to F6 fractions showed small low molecular weight peptides displaying low toxicity. As expected, F3 fraction contains peptides with apparent molecular weight (MW) related to toxin's MW (Figure 3).

Immune cross-reactivity between Am and Aah using AahI and AahII-specific polyclonal: Indirect ELISA

The cross-reactivity of polyclonal antibodies directed against the major toxins from Aah venom: anti-AahI, anti-AahII, towards Am venom or fractions F2 and F3, showed successful recognition of the F3 Am fraction by both anti-AahI and anti-AahII polyclonal antibodies with a very high significant p value ($p = 0.0008$ and $p = 0.001$, respectively). Also, anti-AahI and anti-AahII reacted immunologically with Am venom ($p = 0.02$; $p = 0.004$ respectively) (Figure 4A,4B) whereas F2 fraction revealed low reactivity to anti-AahII ($p = 0.035$) (Figure 4B).



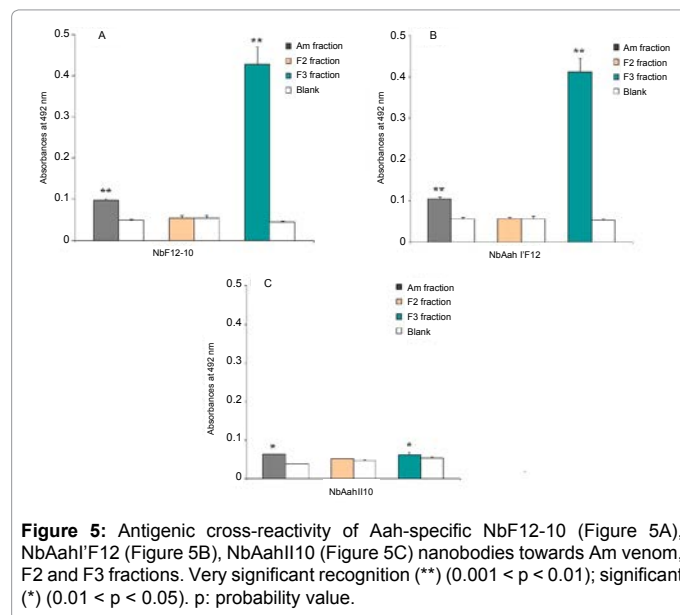
Immune cross-reactivity between Am and Aah scorpion venoms using NbF12-10, NbAahI'F12 and NbAahII10 specific monoclonal antibodies: Indirect ELISA

We evaluated immunological binding capacity of monoclonal Nbs: NbF12-10, NbAahI'F12 and NbAahII10 towards Am venom and its fractions F2 and F3. An antigenic cross-reactivity against F3 fraction is observed when NbF12-10 (Figure 5A) and NbAahI'F12 (Figure 5B) are used at concentration of 5µg/ml, and the p-values are highly significant ($p = 0.0028$ and 0.0022 , respectively). A significant reactivity of NbAahI'F12 against Am venom is noted ($p = 0.0025$) (Figure 5B). Remarkably, only poor binding of NbAahII10 to Am venom as well as to F3 fraction is noticed (Figure 5C). No affinity has been noted between Nbs (NbF12-10, NbAahI'F12 and NbAahII10) and F2 fraction.

Histology of brain, lung and liver tissues upon F3 injection with or without NbF12-10

Pathophysiological effects of F3 fraction have been investigated in mouse by i.c.v injection. Histological screening of organs sections from mice envenomed by F3 toxic fraction with two doses of 30 ng and 35 ng (corresponding to 2 LD₅₀ and 2.3 LD₅₀, respectively), showed 100% mortality of mice poisoned and structural changes in brain, lung and liver tissues. Indeed, in brain tissue, a marked congestion, vasodilatation, hemorrhage, edema and neuronal constriction were observed (Figure 6: panels B-B1 and K). In lung parenchyma, we observed many edemas in intra-alveolar and bronchiolar levels, and half of the lung tissue was invaded by edema and congestion. Moreover, several hemorrhagic foci, large fibrin deposition, infiltration of inflammatory cells and loss of alveolar walls were observed (Figure 6: panels E and M-M1). In liver tissue, F3 fraction caused congestion, sinusoidal dilatation, hepatocyte turgescence, hepatocyte with nuclear hypertrophy or bi-nucleating (Figure 6: panels H and O). Histological slices of control animals showed normal architecture structural (Figure 6: panels A, D-D1 and G).

To evaluate the capacity of NbF12-10 to neutralize the toxicity caused by 30 or 35 ng (i.e. 2 LD₅₀ and 2.3 LD₅₀) of the F3 toxins from Am scorpion venom per mice, we pre-incubated the toxins with NbF12-10 at various molar ratios before i.c.v. injection (Table 1). The



Group of four mice	Molar ratio F3:NbF12-10	Survivors mice
1	1 : 1	0/4
2	1 : 2	0/4
3	1 : 4	0/4
4	1 : 4	0/4
5	1 : 8	2/4

Table 2: Efficiency of NbF12-10 against the toxic effects of F3 fraction.

Results of mice groups challenged with molar ratios of F3: NbF12-10 by i.c.v injection.

NbF12-10 was added at an estimated 1 to 8 molar excess over the toxins in the F3 fraction, as indicated. The mice from the first, second and third group received 30 ng of F3 pre-incubated with either 120 ng, 240 ng or 480 ng of NbF12-10 (that correspond to a molar ratio of toxin: Nb of 1: 1, 1:2 and 1:4, respectively). The fourth and fifth groups of mice received 35 ng of F3 pre-incubated with 560 ng or 1120 ng of NbF12-10 (corresponding to 4 or 8-fold molar excess of Nb, respectively).

Our results revealed that NbF12-10 ensures the survival of 50 % of mice injected with 35 ng of the F3 fraction with an 8 fold molar excess of Nb (Table 2). Hence, a significant Am-neutralizing capacity of the NbF12-10 was noticed under these conditions whereas a reduced excess of NbF12-10 (i.e. equimolar to 1:4 ratio) in the mixtures failed to neutralize a 2 LD₅₀ of F3-Am fraction as all mice died from F3 poisoning and important structural changes in tissues were observed experimentally.

Interestingly, the survivals didn't exhibit any severe symptoms of envenoming (e.g. neurological signs, agitation and lumps dorsal are missing) and damages were clearly less significant in the target

tissue of envenomed mice that survived following injection. Indeed, the detailed histological study of tissue structure demonstrates a significant reduced proportion of tissue damage within the organ sections. In particular, brain parenchyma was completely devoid of edema and nerve cells display their common feature (Figure 6: panel L). Regression of lung edema was evident. The number of hemorrhagic areas was less important nearby minor congestions and no deposited fibrin was noticed (Figure 6: panel N-N1). Moreover, liver tissue revealed a similar architecture to control tissue without dilatation of sinusoids, neither cell turgescence (Figure 6: panel P). However, a lower molar excess of NbF12-10 (30 ng of F3 fraction mixed to 4-fold molar excess of NbF12-10) resulted in a severely reduced experimental neutralizing efficacy and mice from this cohort failed to survive. Hence, histological analysis of post-mortem animals showed tissue damage as well. In cerebral cortex, we noted extravasation of blood (data not shown), edema, less regression of neurons and congestion of a large vessel (Figure 6: panel C). Pulmonary tissue was invaded by edema (Figure 6: panel F). Sinusoidal dilatation and a minority of hepatocyte turgescence were observed (Figure 6: panel I).

Discussion

In the present study, we have demonstrated that F3, a toxic fraction from Am scorpion venom has led to structural abnormalities. This fraction corresponds to most abundant toxic component, obtained after analytical filtration of Am venom (Figure 1). F3 fraction showed a similar retention time as that of AahG50 (derived from Aah venom) fraction whereas the eluted fractions on either side of this F3 peak display significant divergence in retention time [34,36]. The LD₅₀ of F3 fraction, estimated as the amount of toxins whereby 50% of the mice (cohorts of 4 mice) survived the injection that corresponds to

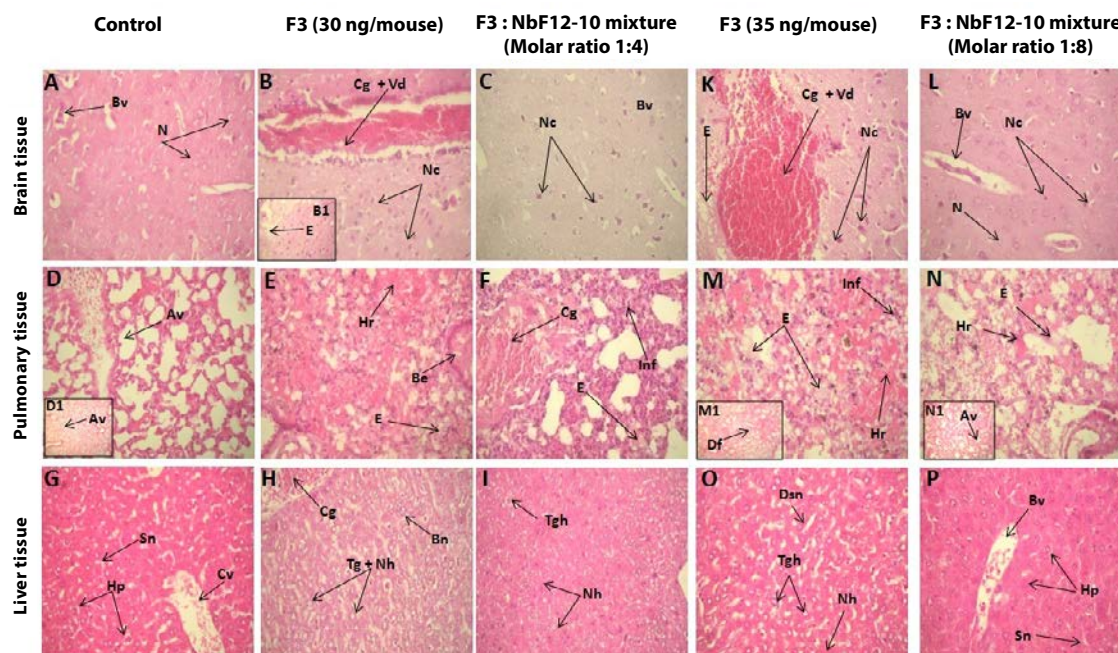


Figure 6: Histology of brain, pulmonary and liver tissues from mice envenomed with F3 fraction at 35 ng / mouse (Panels K, M-M1 and O) or receiving F3 mixed with 8 molar excess of NbF12-10 (Panels L, N-N1 and P). Histology of brain, pulmonary and liver tissues from mice envenomed with injection of F3 fraction at 30 ng / mouse (Panels B-B1, E and H) or receiving F3 mixed with 4 molar excess of NbF12-10 (Panels C, F and I) in comparison to tissues from control mice (Panels A, D-D1 and G).N: Neurons, Bv: Blood vessel, Cg + vd: congestion and vasodilatation, Nc: Neuronal constriction, Av: Alveole, Hr: hemorrhage, Be: Bronchial edema, E: Edema, Inf: Infiltration of inflammatory cells, Cg: Congestion, Hp: Hepatocyte; Sn: Sinusoids, Cv: Centrolobular vein, Tg + Nh: Turgescence + nuclear hypertrophy, Bn: Bi-nucleating, Fd: Fibrin deposit (X 40 magnifications). All injections were made via i.c.v injections.

15 ng/mouse, approximately. However, previous experiments were conducted using intra-peritoneal injection of the toxins or venoms. Here, we investigated for the first time the envenoming effect after injection of an Am toxic fraction (F3) via an i.c.v. route with 30 and 35 ng (equivalent to 2 LD₅₀ and 2.3 LD₅₀). Histological examination showed that both doses provoked considerable tissue damage leading to significant structural changes in brain, lung and liver parenchyma.

It has been demonstrated that toxins from scorpion venom target to their specific receptors in sodium, potassium channels of nerve and muscle cells which disrupt the propagation of nerve impulses (activation or inactivation of channels) and cause the release of neurotransmitters and cellular mediators. Such changes is causing disturbance of metabolic parameters (glycemia, urea, creatinine, ...) and structural disorganization leading to dysfunction of vital organs have been described (i.e. brain, lungs, heart, liver, kidneys) [15,16], [43,44].

Indeed, cerebral alterations were assumed to be the consequence of neurotransmitter releases [43-51]. More recently, similar structural damage in brain tissue (i.e., edema, hemorrhage, neuronal darkness) were evoked by a small scorpion toxin called Kaliotoxin isolated from Aah [52].

Many studies showed similar results in pulmonary tissues [14-16], [53,54]. It was highlighted that scorpion envenomation is followed by an imbalance of pro- and anti-inflammatory response [55] and scorpion venom is able to affect parameters for pulmonary mechanisms [56]. The fibrin deposit was associated with disruption of blood coagulation process generated after scorpion envenomation [57]. The genesis of pulmonary edema can be attributed to a cardiogenic dysfunction [58]. Moreover, it may be non-cardiogenic origin [17,59] and consequently, pulmonary edema is in that case multifactorial.

In liver tissue, similar observations (i.e., hepatocytes with cytoplasm distended to nuclear hypertrophy and large vacuoles) were noticed after envenomation by *Tityus* genus [14]. Otherwise, hepatocyte cells may exhibit Mallory bodies resulting from hepatic steatosis [60].

Hence, to remove the circulating scorpion venom toxins, immunotherapy is the specific treatment to be applied. Currently, F (ab')₂ based therapy is the only anti-venom therapy available into market for clinical envenoming treatment. This so-called fabotherapy is based on administration of scorpion anti-venom serum produced in pre-immunized horses. As polyclonal product, F (ab')₂-based antivenom has potency to prevent histopathological injuries in tissue and to return into normal, metabolic parameters and electrocardiogram changes caused in patients after scorpion envenoming [61,62]. However, the efficiency of intra-muscular route for antivenom treatment of envenomed patients was not reported systematically in all cases [63]. Hence, avian anti-*Tityus cariptensis* (Tc) venom antibodies (isolated from chicken egg yolks) was recently applied as anti-venom alternative and was effective in neutralizing only 2 LD₅₀ doses of Tc venom [64]. A mixture of antibody fragments F (ab')₂/Fab is able to significantly reduce local leukocytosis, hemorrhage and inflammatory edema induced Aah venom and its toxins [25].

In this study, we first studied the para-specificity between Aah and Am venoms using polyclonal (anti-AahI and anti-AahII) and monoclonal (NbF12-10, NbAahI'F12 and NbAahII10) antivenom against Am venom and its fractions F2 and F3. Thereby, the immunological screening using polyclonal antibodies and Nbs favors the presence of several AahI, AahI' and AahII related or cross-reacting toxins within Am venom and F3 fraction. Indeed, Am venom

molecules (F3 fraction) could be detected easily by both, monospecific NbAahI'F12 and the bispecific NbF12-10 construct, which is suggestive for the presence of AahI related toxins or epitopes within the F3 fraction of Am venom. Similar results reported that human single chain fragment (scFv) recognized toxins of *Centruroides noxius Hoffmann* and *Centruroides suffuses* scorpion venom and rescue mice from severe envenomation by whole venom of *Centruroides suffuses* and *Centruroides noxius* [65]. Also, polyclonal anti-venom against *Hadruiroides lunatus* displayed cross reactivity with venom from *Tityus serrulatus*, *Centruroides sculpturatus* and *Androctonus australis hector* scorpions [66]. Other study has explained that anti-AmmVIII (Anatoxin from Am venom) antibodies were also found to cross-react towards several of the peptides designed from the AahII structure [67]. Devaux et al. (2001) [68] reported that 9C2 (scFv), a murine monoclonal IgG, was able to neutralize AahI toxin from Aah scorpion venom.

Herein we demonstrated in the first time, the effectiveness of Aah-specific NbF12-10 nanotherapeutic to bind and neutralize Am venom related toxins and to prevent severe structural abnormalities at cerebral, pulmonary and hepatic parenchyma, provoked by i.c.v injection of Am venom F3 fraction. More interestingly, pre-incubation with NbF12-10 leads to less toxic mixture and therefore envenomed mice rescued from death. Similarly, F7Nb nanobody raised against Heminocrolysin (major known hemolytic and dermonecrotic fraction of *Hemiscorpus lepturus* scorpion) venom showed in vitro and *in vivo* neutralization of heminocrolysin activity [69]. Clearly, our data revealed that i.c.v route is very sensitive and associated with distant and significant structural lesions and confirms the importance of metabolic releases in severe and dramatic symptoms [70,71]. Further investigations are in progress to test additional nanobody candidates with sub-nanomolar affinity for the AahI' and AahII toxins, separately or in combination and to study the effect of NbF12-10 against whole Am venom. Indeed, study on large cohorts of animals and using classical pharmacokinetics/pharmacodynamics experiments is in progress.

Conclusion

In this study, we demonstrated a significant antigenic cross-reactivity ($p < 0.05$) of polyclonal antibodies and Nbs between the Tunisia Aah and Morocco Am scorpion venom components. Especially, the result with NbF12-10 is important, as this is our lead product (produced against the major toxins from Aah scorpion venom of Tunisia) with which we provided recently the proof-of-concept to neutralize the Aah envenoming. These promising data prompted us to further study its *in vivo* neutralizing capacity against experimental Am envenoming. Our results with this bispecific Nb on the Am venom highlights its effectiveness to reduce pathophysiological effects of toxicity caused by the major toxic fraction of this Moroccan Am scorpion. Evidence is provided that this Nb construct might be seriously considered as promising anti-venom therapeutic to treat severe scorpion envenoming cases in the large Maghreb area. Further preclinical studies to include larger cohorts of mice and other experimental animals should be considered in the future.

Acknowledgments

This work was partially supported by International Pasteur Institute Network (RIIP), Islamic Bank for Development (BID), Pasteur Institute of Morocco (IPM) and Pasteur Institute of Tunis (IPT) grants. We would like to thank Prof. Serge Muyldermans for support in identifying Nanobodies. Our gratitude's are addressed to Professors Naima ELMdaghri Director of Pasteur Institute of Morocco, Hechmi Louzir General Director of Pasteur Institute of Tunis for encouraging this research project. Our thanks are extended to Dr. Zakaria Benlasfar (IPT) and Lotfi Boussada (IPM) for animal facilities; we also thanked Dr. Abderrahmane Belhouari, Faculty

of Sciences, Ben M'sik, Casablanca, Morocco for assistance in statistical data analysis.

Author Contributions

Fatima Chgoury conducted biochemical and experimental studies. Rahma Ben Abderrazek and Naoual Oukkache contributed to technical and experimental work. Issam Hmila contributed in part to Nanobody production and purification; Haifa Tounsi and Samir Boubaker for design and analysis of histological sections; Rachid Saïle, Noredine Ghalim and Mohamed El Ayeb for analysis and discussing results. Fatima Chgoury and Balkiss Bouhaouala-Zahar are responsible for writing this manuscript. Balkiss Bouhaouala-Zahar was responsible for designing experiments, result interpreting and the editorial corrections.

Conflicts of Interest

The authors declare that there are no conflicts of interest.

References

- Goyffon M, Vachon M, Broglio N (1982) Epidemiological and clinical characteristics of the scorpion envenomation in Tunisia. *Toxicon* 20: 337-344.
- Dehesa Dávila M, Possani LD (1994) Scorpionism and serotherapy in Mexico. *Toxicon* 32: 1015-1018.
- Ismail M (1994) The treatment of the scorpion envenoming syndrome: the Saudi experience with serotherapy. *Toxicon* 32: 1019-1026.
- Ghalim N, El-Hafny B, Sebti F, Heikel J, Lazar N, et al. (2000) Scorpion envenomation and serotherapy in Morocco. *Am J Trop Med Hyg* 62: 277-283.
- Lira-da-Silva RM, Amorim AM, Brazil TK (2000) [Poisonous sting by *Tityus stigmurus* (Scorpiones; Buthidae) in the state of Bahia, Brazil]. *Rev Soc Bras Med Trop* 33: 239-245.
- Touloun O, Slimani T, Boumezzough A (2001) Epidemiological survey of scorpion envenomation in Southwestern Morocco. *J Venom Anim Toxins* 7: 199-218.
- Otero R, Navío E, Céspedes FA, Núñez MJ, Lozano L (2004) Scorpion envenoming in two regions of Colombia: clinical, epidemiological and therapeutic aspects. *Trans R Soc Trop Med Hyg* 98: 742-750.
- Bouaziz M, Bahloul M, Kallel H, Samet M, Ksibi H, et al. (2008) Epidemiological, clinical characteristics and outcome of severe scorpion envenomation in South Tunisia: multivariate analysis of 951 cases. *Toxicon* 52: 918-926.
- Soulaymani Bencheikh R, Faraj Z, Semlali I, Ouammi L, Badri M (2003) National strategy in the battle against scorpion stings and envenomations. Application and evaluation. *Bull Soc Pathol Exot* 96: 317-319.
- Krifi MN, Miled K, Abderrazek M, El Ayeb M (2001) Effects of antivenom on *Buthus occitanus tunetanus* (Bot) scorpion venom pharmacokinetics: towards an optimization of antivenom immunotherapy in a rabbit model. *Toxicon* 39: 1317-1326.
- El Hafny B, Chgoury F, Adil N, Cohen N, Hassar M, et al. (2002) Intraspecific variability and pharmacokinetic characteristics of *Androctonus mauretanicus mauretanicus* scorpion venom. *Toxicon* 40: 1609-1616.
- Hammoudi-Triki D, Lefort J, Rougeot C, Robbe-Vincent A, Bon C, et al. (2007) Toxicokinetic and toxicodynamic analyses of *Androctonus australis hector* venom in rats: optimization of antivenom therapy. *Toxicol Appl Pharmacol* 218: 205-214.
- Sofer S, Gueron M, White RM, Lifshitz M, Apte RN (1996) Interleukin-6 release following scorpion sting in children. *Toxicon* 34: 389-392.
- Corrêa MM, Sampaio SV, Lopes RA, Mancuso LC, Cunha OAB, et al. (1997) Biochemical and histopathological alterations induced in rats by *Tityus serrulatus* scorpion venom and its major neurotoxin tityustoxin-I. *Toxicon* 35: 1053-1067.
- Bessalem S, Hammoudi-Triki D, Laraba-Djebari F (2003) Effect of immunotherapy on metabolic and histopathological modifications after experimental scorpion envenomation. *Bull. Société. Pathol. Exot* 96: 110-114.
- Adi-Bessalem S, Hammoudi-Triki D, Laraba-Djebari F (2008) Pathophysiological effects of *Androctonus australis hector* scorpion venom: tissue damages and inflammatory response. *Exp. Toxicol. Pathol* 60: 373-380.
- Cavari Y, Lazar I, Shelef I, Sofer S (2013) Lethal brain edema, shock, and coagulopathy after scorpion envenomation. *Wilderness Environ Med* 24: 23-27.
- Rosso JP, Rochat H (1985) Characterization of ten proteins from the venom of the Moroccan scorpion *Androctonus mauretanicus mauretanicus*, six of which are toxic to the mouse. *Toxicon* 23: 113-125.
- Zerrouk H, Bougis PE, Céard B, Benslimane A, Martin-Eauclaire MF (1991) Analysis by high-performance liquid chromatography of *Androctonus mauretanicus mauretanicus* (black scorpion) venom. *Toxicon* 29: 951-960.
- Oukkache N, Rosso JP, Alami M, Ghalim N, Saïle R, et al. (2008) New analysis of the toxic compounds from the *Androctonus mauretanicus mauretanicus* scorpion venom. *Toxicon* 51: 835-852.
- Martin-Eauclaire MF, Alami M, Giamarchi A, Missimili V, Rosso JP, et al. (2006) A natural anatoxin, Amm VIII, induces neutralizing antibodies against the potent scorpion alpha-toxins. *Vaccine* 24: 1990-1996.
- Karlson-Stiber C, Persson H, Heath A, Smith D, al-Abdulla IH, et al. (1997) First clinical experiences with specific sheep Fab fragments in snake bite. Report of a multicentre study of *Vipera berus* envenoming. *J Intern Med* 241: 53-58.
- Ismail M, Abd-Elsalam MA (1998) Pharmacokinetics of 125I-labelled IgG, F(ab')₂ and Fab fractions of scorpion and snake antivenins: merits and potential for therapeutic use. *Toxicon* 36: 1523-1528.
- Abroug F, ElAtrous S, Nouira S, Haguiga H, Touzi N, et al. (1999) Serotherapy in scorpion envenomation: a randomised controlled trial. *Lancet* 354: 906-909.
- Sami-Merah S, Hammoudi-Triki D, Martin-Eauclaire MF, Laraba-Djebari F (2008) Combination of two antibody fragments F(ab')₂/Fab: an alternative for scorpion envenoming treatment. *Int Immunopharmacol* 8: 1386-1394.
- Sofer S, Gueron M (1988) Respiratory failure in children following envenomation by the scorpion *Leiurus quinquestriatus*: hemodynamic and neurological aspects. *Toxicon* 26: 931-939.
- Cupo P, Hering SE (2002) Cardiac troponin I release after severe scorpion envenoming by *Tityus serrulatus*. *Toxicon* 40: 823-830.
- Meki AR, Mohamed ZM, Mohey El-deen HM (2003) Significance of assessment of serum cardiac troponin I and interleukin-8 in scorpion envenomed children. *Toxicon* 41: 129-137.
- Ismail M, Abd-Elsalam MA (1988) Are the toxicological effects of scorpion envenomation related to tissue venom concentration? *Toxicon* 26: 233-256.
- Devaux C, Jouirou B, Naceur Krifi M, Clot-Faybesse O, El Ayeb M, et al. (2004) Quantitative variability in the biodistribution and in toxinokinetic studies of the three main alpha toxins from the *Androctonus australis hector* scorpion venom. *Toxicon* 43: 661-669.
- Hamers-Casterman C, Atarhouch T, Muyldermans S, Robinson G, Hamers C, et al. (1993) Naturally occurring antibodies devoid of light chains. *Nature* 363: 446-448.
- Muyldermans S, Atarhouch T, Saldanha J, Barbosa JA, Hamers R (1994) Sequence and structure of VH domain from naturally occurring camel heavy chain immunoglobulins lacking light chains. *Protein Eng* 7: 1129-1135.
- Vu KB, Ghahroudi MA, Wyns L, Muyldermans S (1997) Comparison of llama VH sequences from conventional and heavy chain antibodies. *Mol Immunol* 34: 1121-1131.
- Hmila I, Abdallah R BA, Saerens D, Benlasfar Z, Conrath K, et al. (2008) VHH, bivalent domains and chimeric Heavy chain-only antibodies with high neutralizing efficacy for scorpion toxin AahI. *Mol Immunol* 45: 3847-3856.
- Hmila I, Saerens D, Ben Abderrazek R, Vincke C, Abidi N, et al. (2010) A bispecific nanobody to provide full protection against lethal scorpion envenoming. *FASEB J* 24: 3479-3489.
- Abderrazek RB, Hmila I, Vincke C, Benlasfar Z, Pellis M, et al. (2009) Identification of potent nanobodies to neutralize the most poisonous polypeptide from scorpion venom. *Biochem J* 424: 263-272.
- Bradford MM (1976) A rapid and sensitive method for the quantitation of microgram quantities of protein utilizing the principle of protein-dye binding. *Anal Biochem* 72: 248-254.
- El Ayeb M, Delori P, Rochat H (1983) Immunochemistry of scorpion alpha-toxins: antigenic homologies checked with radioimmunoassays (RIA). *Toxicon* 21: 709-716.
- Bouhaouala-Zahar B, Ducancel F, Zenouaki I, Ben Khalifa R, Borchani L, et al. (1996) A recombinant insect-specific alpha-toxin of *Buthus occitanus tunetanus* scorpion confers protection against homologous mammal toxins. *Eur. J. Biochem. FEBS* 238: 653-660.

40. Miranda F, Kupeyan C, Rochat H, Rochat C, Lissitzky S, et al. (1970) Purification of animal neurotoxins. Isolation and characterization of eleven neurotoxins from the venoms of the scorpions *Androctonus australis hector*, *Buthus occitanus tunetanus* and *Leiurus quinquestriatus quinquestriatus*. *Eur. J. Biochem. FEBS* 16: 514-523.
41. Bouhaouala-Zahar B, Ben Abderrazek R, Hmila I, Abidi N, Muijldermans S, et al. (2011) Immunological aspects of scorpion toxins: current status and perspectives. *Inflamm Allergy Drug Targets* 10: 358-368.
42. Meddeb-Mouelhi F, Bouhaouala-Zahar B, Benlasfar Z, Hammadi M, Mejrj T (2003) Immunized camel sera and derived immunoglobulin subclasses neutralizing *Androctonus australis hector* scorpion toxins. *Toxicon* 42: 785-791.
43. Oukkache N, Malih I, Chgoury F, El Gnaoui N, Saïle R, et al. (2009) Modifications histopathologiques après envenimation scorpionique expérimentale chez la souris. *Medical Sciences Rev Médicopharmaceutique* 53: 48-52.
44. Chgoury F, Oukkache N, El Gnaoui N, Benomar H, Saïle R, et al. (2011) Etude cinétique et biologique du venin de scorpion *Androctonus mauretanicus* chez le lapin. *Toxins and ions transferts* 19: 141-145.
45. Clot-Faybesse O, Guieu R, Rochat H, Devaux C (2000) Toxicity during early development of the mouse nervous system of a scorpion neurotoxin active on sodium channels. *Life Sci* 66: 185-192.
46. Nunan EA, Moraes MF, Cardoso VN, Moraes-Santos T (2003) Effect of age on body distribution of Tityustoxin from *Tityus serrulatus* scorpion venom in rats. *Life Sci* 73: 319-325.
47. Sandoval MRL, Lebrun I (2003) TsTx toxin isolated from *Tityus serrulatus* scorpion venom induces spontaneous recurrent seizures and mossy fiber sprouting. *Epilepsia* 44: 904-911.
48. Sampaio SV, Coutinho-Netto J, Arantes EC, Marangoni S, Oliveira B, et al. (1996) Isolation of toxin TsTX-VI from *Tityus serrulatus* scorpion venom. Effects on the release of neurotransmitters from synaptosomes. *Biochem Mol Biol Int* 39: 729-740.
49. Lourenço GA, Lebrun I, Dorce VA (2002) Neurotoxic effects of fractions isolated from *Tityus bahiensis* scorpion venom (Perty, 1834). *Toxicon* 40: 149-157.
50. Nencioni AL, Lourenço GA, Lebrun I, Florio JC, Dorce VA (2009) Central effects of *Tityus serrulatus* and *Tityus bahiensis* scorpion venoms after intraperitoneal injection in rats. *Neurosci Lett* 463: 234-238.
51. Ossanai LT, Lourenço GA, Nencioni AL, Lebrun I, Yamanouye N, et al. (2012) Effects of a toxin isolated from *Tityus bahiensis* scorpion venom on the hippocampus of rats. *Life Sci* 91: 230-236.
52. Ladjel-Mendil AL, Martin-Eauclaire MF, Laraba-Djebari F (2013) Neurophysiological effect and immuno-inflammatory response induced by kaliotoxin of *Androctonus* scorpion venom. *Neuroimmunomodulation* 20: 99-106.
53. De Matos IM, Rocha OA, Leite R, Freire-Maia L (1997) Lung oedema induced by *Tityus serrulatus* scorpion venom in the rat. *Comp Biochem Physiol C Pharmacol Toxicol Endocrinol* 118: 143-148.
54. D'Suze G, Salazar V, Diaz P, Sevcik C, Azpuru H, et al. (2004) Histopathological changes and inflammatory response induced by *Tityus discrepans* scorpion venom in rams. *Toxicon* 44: 851-860.
55. Petricevich VL (2010) Scorpion venom and the inflammatory response. *Mediators Inflamm* 1-16.
56. Paneque Peres AC, Nonaka PN, de Carvalho Pde T, Toyama MH, Silva CA, et al. (2009) Effects of *Tityus serrulatus* scorpion venom on lung mechanics and inflammation in mice. *Toxicon* 53: 779-785.
57. Suze GD, Moncada S, González C, Sevcik C, Aguilar V, et al. (2003) Relationship between plasmatic levels of various cytokines, tumor necrosis factor, enzymes, glucose and venom concentration following *Tityus* scorpion sting. *Toxicon* 41: 367-375.
58. Bahloul M, Chaari A, Dammak H, Bouaziz M (2012) "Pulmonary edema induced by scorpion venom: evidence of cardiogenic nature". *Int J Cardiol* 158: 292-293.
59. Deshpande SB, Akella A (2012) Non-cardiogenic mechanisms for the pulmonary edema induced by scorpion venom. *Int J Cardiol* 157: 426-427.
60. Tilg H, Diehl AM (2000) Cytokines in alcoholic and nonalcoholic steatohepatitis. *N Engl J Med* 343: 1467-1476.
61. Natu VS, Murthy RK, Deodhar KP (2006) Efficacy of species specific anti-scorpion venom serum (AScVS) against severe, serious scorpion stings (*Mesobuthus tamulus concanensis* Pocock) an experience from rural hospital in western Maharashtra. *J Assoc Physicians. India* 54: 283-287.
62. Zayerzadeh E, Koochi MK, Mirakabadi AZ, Fardipour A, Kassaian SE, et al. (2012) Amelioration of cardio-respiratory perturbations following *Mesobuthus eupeus* envenomation in anesthetized rabbits with commercial polyvalent F (ab')₂ antivenom. *Toxicon* 59: 249-256.
63. Jalali A, Bavarsad-Omidian N, Babaei M, Najafzadeh H, Rezaei S, et al. (2012) The pharmacokinetics of *Hemiscorpius lepturus* scorpion venom and Razi antivenom following intramuscular administration in rat. *J Venom Res* 3: 1-6.
64. Alvarez A, Montero Y, Jimenez E, Zerpa N, Parrilla P, et al. (2013) IgY antibodies anti-*Tityus caripitensis* venom: purification and neutralization efficacy. *Toxicon* 74: 208-214.
65. Riaño-Umbarila L, Contreras-Ferrat G, Olamendi-Portugal T, Morelos-Juárez C, Corzo G, et al. (2011) Exploiting cross-reactivity to neutralize two different scorpion venoms with one single chain antibody fragment. *J Biol Chem* 286: 6143-6151.
66. Costal-Oliveira F, Duarte CG, Machado de Avila RA, Melo MM, Bordon KC, et al. (2012) General biochemical and immunological characteristics of the venom from Peruvian scorpion *Hadruroides lunatus*. *Toxicon* 60: 934-942.
67. Alvarenga L, Moreau V, Felicori L, Nguyen C, Duarte C, et al. (2010) Design of antibody-reactive peptides from discontinuous parts of scorpion toxins. *Vaccine* 28: 970-980.
68. Devaux C, Moreau E, Goyffon M, Rochat H, Billiard P, et al. (2001) Construction and functional evaluation of a single-chain antibody fragment that neutralizes toxin Aahl from the venom of the scorpion *Androctonus australis hector*. *Eur J Biochem* 268: 694-702.
69. Yardehnavi N, Behdani M, Pooshang Bagheri K, Mahmoodzadeh A, Khanahmad H, et al. (2014) A camelid antibody candidate for development of a therapeutic agent against *Hemiscorpius lepturus* envenomation. *FASEB J Off Publ Fed Am Soc Exp Biol* 28: 247-478.
70. Hmila I, Cosyns B, Tounsi H, Roosens B, Cavelliers V, et al. (2012) Pre-clinical studies of toxin-specific nanobodies: evidence of *in vivo* efficacy to prevent fatal disturbances provoked by scorpion envenoming. *Toxicol Appl Pharmacol* 264: 222-231.
71. Mesquita MB, Moraes-Santos T, Moraes MF (2003) Centrally injected tityustoxin produces the systemic manifestations observed in severe scorpion poisoning. *Toxicol Appl Pharmacol* 187: 58-66.