

## Effect of Interleukin-2 Treatment Combined with Magnetic Fluid Hyperthermia on Lewis Lung Cancer-Bearing Mice

Runlei Hu<sup>1</sup>, Xianfu Ke<sup>2</sup>, Hong Jiang<sup>1</sup>, Shenglin Ma<sup>3\*</sup>, Hu Li<sup>1</sup>, Guoqing Wang<sup>1</sup>, Dongshan Wei<sup>1</sup> and Wei Wang<sup>1</sup>

<sup>1</sup>Department of Thoracic Surgery, Hangzhou First People's Hospital, Nanjing Medical University, Hangzhou, Zhejiang Province, China

<sup>2</sup>Laboratory Animal Center Zhejiang Academy of Medical Sciences, Hangzhou, Zhejiang Province, China

<sup>3</sup>Department of Radiation Oncology, Hangzhou First People's Hospital, Nanjing Medical University, Hangzhou, Zhejiang Province, China

\*Corresponding author: Dr. Shenglin Ma, Department of Radiation Oncology, Hangzhou First People's Hospital, Nanjing Medical University, Hangzhou, Zhejiang Province, China 310006, E-mail: [mashenglin@medmail.com.cn](mailto:mashenglin@medmail.com.cn).

Received date: July 21, 2015, Accepted date: November 02, 2015, Published date: November 9, 2015

Copyright: © 2015 Hu R, et al. This is an open-access article distributed under the terms of the Creative Commons Attribution License, which permits unrestricted use, distribution, and reproduction in any medium, provided the original author and source are credited.

### Abstract

**Objective:** The study aimed to investigate the therapeutic effect of interleukin-2 (IL-2) treatment combined with magnetic fluid hyperthermia (MFH) on Lewis lung cancer-bearing mice.

**Materials and Methods:** Magnetic fluids were prepared in vitro and directly injected into the tumors in the mice, which were subjected to an alternating magnetic field. The temperature in the tumor reached 43°C and was maintained by controlling the strength of magnetic field for 30 minutes. Twenty-four hours later, IL-2 was injected directly into the tumors. Mice were divided into four groups: group I (control), group II (MFH), group III (IL-2), and group IV (IL-2+MFH).

**Results:** The tumor grew gradually in group II and group IV (both  $P < 0.05$ ) compared to the control group. Histological analysis showed that the tumor cells underwent apoptosis and necrosis. Immunohistochemistry results demonstrated that heat shock protein 70 (HSP70) and CD8-positive T cells were strongly expressed.

**Conclusion:** The results have provided evidence that IL-2 treatment combined with MFH could improve the therapeutic effect on lung cancer-bearing mice.

**Keywords:** Magnetic fluid; Hyperthermia; Interleukin-2; Lung cancer

### Introduction

Lung cancer is one of the most common malignant tumors in the world. Current therapeutic options remain unsatisfactory for most patients. Surgical resection has been recognized as the most effective method for the treatment of lung cancer, but it is available only for a small number of patients [1]. Therefore, it is crucial to identify a new method to treat lung cancer [2].

Magnetic fluid hyperthermia (MFH) is a thermal therapy using nanotechnology and hyperthermia [3]. Dispersions of biocompatible iron oxide nanoparticles in water (magnetic fluids) can be injected into tumors and heated in an externally applied alternating magnetic field (AMF) by Brownian and Neel relaxation mechanism [4]. Since the magnetic particles were directly injected into tumors, there was no distribution of magnetic particles in the periphery of normal tissues and the temperature of these normal tissues did not increase significantly.

Thereby, the hyperthermia was specifically targeted to the tumors. The efficacy of hyperthermia was demonstrated using MFH in animals with several types of tumors such as B16 mouse melanoma, T-9 rat glioma, SMMC-7721 mouse hepatocarcinoma, and BT-474 mouse breast cancer [5-8]. This method was found to be effective to induce regression of tumors and increase the life span of the animals. As a

result, MFH appears to be a promising method for targeting lung cancer.

Immunotherapy has become an accepted therapeutic modality. Interleukin-2 (IL-2) is a potent stimulator of lymphocyte proliferation and augments the activity of cytotoxic T lymphocytes (CTLs). IL-2 has a broad range of immunologic effects such as inducing specific T helper cells, natural killer (NK) cells, and lymphokine-activated killer cells [9]. Due to these effects, IL-2 is widely used in cancer therapy to enhance cellular immunity and the cytotoxic activity of effector cells [10].

Based on these results, the study examined the feasibility of combining IL-2 and MFH for lung cancer treatment. For the first time, the combination of local injection of IL-2 and MFH has been shown to exhibit an obvious antitumor effect against lung cancer.

### Materials and Methods

#### Cell line and animal model

Lewis lung cancer cells were purchased from the Institute of Biochemistry and Cell Biology, Shanghai Institute of Biological Sciences, Institute of Materia Medica, Chinese Academy of Medical Sciences and supplemented with 10% fetal bovine serum (FBS).

C57/BL6 mice (male, 8 weeks old) were purchased from the Shanghai Institute of Biological Sciences, Chinese Academy of Medical

Sciences. The mice were fed with sterile food and water, kept in sterile cages on sterile bedding, and housed in rooms with a constant temperature and humidity.

To prepare tumor model, the cell density was adjusted to about  $1.0 \times 10^7$ /ml. To induce tumors, 0.2 ml of Lewis lung cancer cell suspension (approximately  $2 \times 10^6$  cells) was injected in to the right flank of each mouse through hypodermic inoculation. The noticeable tumors can be observed 4 days after inoculation. The sizes of tumors were measured by vernier calipers every day, and the volume of tumor was calculated using the following formula:

$$V=1/2ab^2cm^3$$

Where 'a' is the major diameter of tumor and 'b' is the minor diameter perpendicular to the major diameter (unit in cm).

The treatment started when the major diameter was about  $0.8 \pm 0.1$  cm.

All the animal experiments were performed according to the principles described in the Guide for the Care and Use of Laboratory Animals as promulgated by the Zhejiang Standing Committee.

## Hyperthermia

The mice were randomly selected and anesthetized with 2% pentobarbital sodium (Beijing Reagent Company) by intraperitoneal injection (50 mg/kg). The mice were divided into four groups (n=15): group I (control), II (MFH), III (IL-2), and IV (MFH+IL-2).

In group II and IV, 15 mg of magnetic fluid was slowly injected into the tumors with 1 ml syringe. Following the magnetic fluid injection (24 h), the tumors of mice in group II and IV and were subjected to AMF for 30 min. Tumor and rectum temperature during AMF irradiation was measured by optical fiber probe (YF-200). The temperature was kept at 43°C for 30 min by controlling the strength of magnetic field. Mice in groups III (IL-2) and IV (MFH+IL-2) were injected with recombinant IL-2 ( $5 \times 10^4$  U, Beijing four biological pharmaceutical Co., LTD), after 24 hours of hyperthermia, IL-2 was injected directly into the nodules. Administration of cytokines was carried out daily for 2 days.

After 14 days, all the mice were sacrificed. The weight and volume inhibitory rates (IW and IV, respectively) of the tumor were calculated as follows:

$IW=(1 - \text{the weight of tumor of experimental group}/\text{the weight of tumor of control group}) \times 100\%$ ;  $IV=(1 - \text{the volume of tumor of experimental group}/\text{the volume of tumor of control group}) \times 100\%$ .

## Pathological observation

Next day of hyperthermia, three mice were randomly chosen from each group, sacrificed by neck dislocation. The tumors were taken out immediately and dissected. The resected tumors were fixed in 10% formalin, embedded in paraffin, sectioned, and stained with hematoxylin-eosin which was then followed by histological observation on the tumors.

## Preparation of specimens for IHC staining

After 24 hours of hyperthermic treatment, tumors were removed and specimens for IHC staining were prepared. For immunostaining of heat shock protein 70 (HSP70), CD4, and CD8, the resected tumors were fixed in 10% formalin solution and embedded in paraffin. Thin (4

$\mu\text{m}$ ) sections of paraffin-embedded specimens were deparaffinized in xylene and rehydrated with a series of ethanol washes.

Autoclave treatment at 120°C for 10 min in 10 mM sodium citrate buffer (pH 6.0) for antigen retrieval. Paraffin-embedded sections were incubated at 37°C for 60 min with mouse monoclonal antibody preparations (MAbs) and with rat MAbs against HSP70 and CD4, CD8 (BD PharMingen, San Jose, CA) antigens, respectively. These sections were subsequently incubated at 37°C for 60 min with biotinylated goat anti-mouse IgG (Boster Company, Wuhan, China) or biotinylated mouse anti-rat IgG (Boster Company, Wuhan, China).

Specimens were incubated at 37°C for 30 min with alkaline phosphatase. Each step was followed by washing with phosphate buffered saline (PBS). Alkaline phosphatase and peroxidase activities were visualized by New Fuchsin Substrate and diaminobenzidine tetrahydrochloride solution containing 0.005% hydrogen peroxide, respectively. All slides were counterstained with hematoxylin. For negative controls, primary antibodies were replaced with either unrelated monoclonal antibodies or PBS.

## Statistical

To evaluate the significance of overall differences in tumor volumes and tumor weights among all *in vivo* groups, statistical analysis was performed by analysis of variance (ANOVA).  $P<0.05$  was considered as statistically significant. The tumor volumes and weight data were represented as mean +/- standard error on graphs.

## Results

### Hyperthermia by means of magnetic fluid *in vivo*

During hyperthermia, the tumor temperature increased to above 43°C in 5 min and fluctuated around 43°C with controlled strength of AMF, and the rectum temperature remained around 30°C.

### Histological analysis

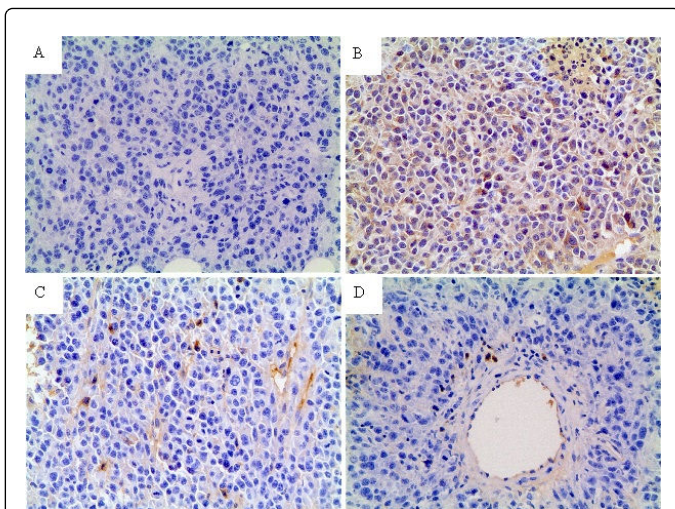
After hyperthermia, in group II and IV, the surface of most tumors scabbed and local necrosis occurred after 2-3 days. A large number of apoptotic tumor cells were discovered with the characteristics of karyopycnosis and condensation. In addition, there was coagulation necrosis in some areas.

The acidophilia increased and normal cell structure disappeared. Hemorrhagic lesions were detected in some apoptotic and necrotic areas. There were many red blood cells around the necrotic tumor cells and angiorrhesis occurred. The magnetic fluid was distributed between the apoptotic and necrotic areas.

In group I and III, the sizes of tumors were increased with time and regular with smooth surface. The nucleoli were stained and karyokinesis was occasionally detected. There were some ischemic necrotic tissues in the center.

### IHC of Lewis lung cancer after MFH

Expression of HSP70, CD4-positive, and CD8-positive T cells in Lewis lung cancer was investigated and the results were shown in Figure 1. Without hyperthermia, staining for HSP70, CD4, and CD8 had negative findings (Figure 1A). However, after hyperthermia, HSP70, CD4, and CD8 were strongly expressed in the viable cells around the necrotic area as shown in Figure 1B-1D.



**Figure 1:** Expression of HSP70, CD4-positive and CD8-positive T cells in Lewis lung cancer was investigated. Without hyperthermia, staining for HSP70, CD4, and CD8 T was negative (A). However, after hyperthermia, HSP70, CD4, and CD8 were strongly expressed in the viable cells around the necrotic area (B-D).

### Antitumor effects of hyperthermia

In group I and III, the tumors grew progressively. In group II and IV, the tumors grew slowly. Day 14 after treatment, the mass and volume inhibitory ratio of the group III and IV was IM=45.8% and 68.1%, and IV=37.8% and 71.4%, respectively. Hence, the ratio of group IV was much higher than that of the other groups (Table 1).

Groups	Tumor volumemm3 $\bar{x} \pm s$	Volume inhibitory Rate (%)	Tumor mass g, $\bar{x} \pm s$	Mass inhibitory Rate (%)
Control group	4459.8 $\pm$ 2044.1	-	8.31 $\pm$ 4.11	-
MFH group	2775.1 $\pm$ 90.4	37.8 <sup>▲</sup>	4.51 $\pm$ 0.25	45.8 <sup>▲</sup>
IL-2 group	3875.8 $\pm$ 1284.1	13.1 <sup>*</sup>	7.13 $\pm$ 2.40	14.2 <sup>*</sup>
MFH+IL-2 group	1277.8 $\pm$ 645.9	71.4 <sup>▲</sup>	2.65 $\pm$ 1.21	68.1 <sup>▲</sup>

<sup>▲</sup> P<0.01 vs. control group; <sup>\*</sup>P>0.05 vs. control group

**Table 1:** Volume and mass inhibitory rate of Lewis lung cancer in nude mice after treatment.

### Discussion

MFH represents an innovative technique to heat deep-seated tumors such as lung cancer. It may have several merits over conventional techniques employed for regional hyperthermia such as radiofrequency, microwave, and ultrasound methods, which are often limited by their inability to selectively target the tumor tissue. The method of MFH is able to heat the specific tumor. Moreover, the temperature during hyperthermia can be controlled by AMF, which

allows the operator to induce the tumor cell apoptosis and necrosis without damaging the surrounding normal tissue.

Hyperthermia induces expression of HSPs [11] such as HSP70, HSP90, and glucose-regulated protein 96 (gp96). HSPs have a chaperone function for tumor antigens. The mechanism of antitumor immunity induced by MFH, is the possible mechanisms have been proposed about the antigen presentation by HSP70 expression during hyperthermia [12]. One such mechanism is heat-induced enhancement of antigenic peptide presentation through major histocompatibility complex (MHC) class I antigens of tumor cells and hence, enhanced tumor immunogenicity and subsequently augmented T-cell cross-priming [13]. These results have suggested that HSP70 is an important modulator of tumor-cell immunogenicity during hyperthermia and CTLs are the effector cells.

The most important finding from the study was that, MFH combined with IL-2 improves the therapeutic effect on Lewis lung cancer in mice. IL-2 is a cytokine from the cytokine-receptor chain family with many functions including stimulating the proliferation of T cells, inducing the production of NK cells, inducing CTL generation, and facilitating the synthesis of immunoglobulins produced by B cells [14,15].

IL-2 has been used in antigen presenting cell (APC) based tumor vaccines [16]. This has already been approved for clinical use in patients with metastatic renal cell carcinoma and malignant melanoma [17,18]. The study demonstrated that there was no substantial expression of CD4 or CD8 in the tumors injected with IL-2 and essentially the growth of the tumors was not inhibited, which suggests that IL-2 alone has a poor antitumor effect on lung cancer. This might be related with the correlation between the implication of IL-2 in the immunological regulation and the self-regulation of T lymphocytes, although exact mechanism remains to be revealed.

In contrast to group III, the growth of the tumors in group II (MFH) and IV (IL-2+MFH) was significantly inhibited, with the inhibition more robust in group IV, which suggests that IL-2 could enhance the antitumor effect of MFH against lung cancer.

In summary, the results have provided evidence that IL-2 treatment combined with MFH could improve the therapeutic effect on lung cancer.

### Acknowledgments

This study was supported by grants from the Medicine and Health Foundation of Zhejiang Province (Grant no. 2009A163), the Science and Technology Development Foundation of Hangzhou (Grant no. 20080333B02), and Medicine and Health Foundation of Hangzhou (Grant no. 2012Z002).

### References

1. Amorin Kajatt E (2013) Lung cancer: a review of current knowledge, diagnostic methods and therapeutic perspectives. Rev Peru Med Exp Salud Publica 30: 85-92.
2. Zhang Y, Li X (2010) Clinical application and advances in radiofrequency ablation of lung neoplasms. Zhongguo Fei Ai Za Zhi 13: 1064-1069.
3. Li XH, Rong PF, Jin HK, (2012) Magnetic fluid hyperthermia induced by radiofrequency capacitive field for the treatment of transplanted subcutaneous tumors in rats. Exp Ther Med 3: 279-284
4. Thiesen B, Jordan A (2008) Clinical applications of magnetic nanoparticles for hyperthermia. Int J Hyperthermia 24: 467-474.

5. Ito A, Matsuoka F, Honda H (2004) Antitumor effects of combined therapy of recombinant heat shock protein 70 and hyperthermia using magnetic nanoparticles in an experimental subcutaneous murine melanoma. *Cancer Immunol Immunother* 53: 26-32
6. Yanase M, Shinkai M, Honda H (1998) Antitumor immunity induction by intracellular hyperthermia using magnetite cationic liposomes. *Jpn J Cancer Res* 89: 775-82
7. Wang ZY, Song J, Zhang DS (2009) Nanosized As<sub>2</sub>O<sub>3</sub>/Fe<sub>2</sub>O<sub>3</sub> complexes combined with magnetic fluid hyperthermia selectively target liver cancer cells. *World J Gastroenterol* 15: 2995-3002
8. Kikumori T, Kobayashi T, Sawaki M (2009) Anti-cancer effect of hyperthermia on breast cancer by magnetite nanoparticle-loaded anti-HER2 immunoliposomes. *Breast Cancer Res Treat* 113: 435-41
9. Liao W, Lin JX, Leonard WJ (2013) Interleukin-2 at the crossroads of effector responses, tolerance, and immunotherapy. *Immunity* 38: 13-25.
10. Chou SH, Shetty AV, Geng Y (2013) Palmitate-derivatized human IL-2: a potential anticancer immunotherapeutic of low systemic toxicity. *Cancer Immunol Immunother* 62: 597-603.
11. Wang L, Dong J, Ouyang W (2012) Anticancer effect and feasibility study of hyperthermia treatment of pancreatic cancer using magnetic nanoparticles. *Oncol Rep* 27: 719-26.
12. Tanaka K, Ito A, Kobayashi T (2005) Intratumoral injection of immature dendritic cells enhances antitumor effect of hyperthermia using magnetic nanoparticles. *Int J Cancer* 116: 624-33.
13. Torigoe T, Tamura Y, Sato N (2009) Heat shock proteins and immunity: application of hyperthermia for immunomodulation. *Int J Hyperthermia* 25: 610-6.
14. Beyer M (2012) Interleukin-2 treatment of tumor patients can expand regulatory T cells. *Oncoimmunology* 1: 1181-1182
15. Quintarelli C, Savoldo B, Dotti G (2010) Gene therapy to improve function of T cells for adoptive immunotherapy. *Methods Mol Biol* 651: 119-30.
16. Yang JY, Li X, Gao L, et al. (2012) Co-transfection of dendritic cells with AFP and IL-2 genes enhances the induction of tumor antigen-specific antitumor immunity. *Exp Ther Med* 4: 655-660.
17. Rosenberg SA. (2012) Raising the bar: the curative potential of human cancer immunotherapy. *Sci Transl Med* 4: 127ps8.
18. Ellebaek E, Engell-Noerregaard L, Iversen TZ, et al. (2012) Metastatic melanoma patients treated with dendritic cell vaccination, Interleukin-2 and metronomic cyclophosphamide: results from a phase II trial. *Cancer Immunol Immunother*. 61:1791-804.