

Effect of Ethanol Leaf Extract of *Moringa oleifera* on Oxidative Stress and Atherogenic Indices of Otapiapia-Exposed Albino Rats

Chidi Uzoma Igwe^{1*}, Linus A. Nwaogu¹, Emeka E. Ezeokeke¹, Callistus I. Iheme¹, and Love Nma Alison²

¹Department of Biochemistry, Federal University of Technology Owerri, Owerri, Imo State, Nigeria

²Department of Biology, Federal University of Technology Owerri, Owerri, Imo State, Nigeria

*Corresponding author: Chidi Uzoma Igwe, Department of Biochemistry, Federal University of Technology Owerri, Owerri, Imo State, Nigeria, Tel: +234-0806-607-5587; E-mail: igwechidi9@gmail.com

Received date: April 14, 2017; Accepted date: May 29, 2017; Published date: June 05, 2017

Copyright: © 2017 Igwe CU, et al. This is an open-access article distributed under the terms of the Creative Commons Attribution License, which permits unrestricted use, distribution, and reproduction in any medium, provided the original author and source are credited.

Abstract

Objective: Otapiapia is a locally produced, easily accessible, non-regulated household pesticide, which could easily contaminate human food. The ameliorative effect of ethanol leaf extract of *Moringa oleifera* on otapiapia-induced changes in oxidative stress, lipid profile and atherogenic indices of albino rats was investigated using standard methods.

Methodology: Twenty-four apparently healthy Wister male albino rats (150-180 g) were divided into 4 groups (I-IV) of 6 animals each. Group I served as the control, while group II animals were given otapiapia contaminated feed and distilled water. Group III were fed uncontaminated diet and *M. oleifera* extract drink. Group IV animals were also given the contaminated diet and *M. oleifera* extract. The feed and drinks were provided *ad libitum* for a period of 14 days.

Result: The results show that intake of otapiapia significantly ($p < 0.05$) reduced serum superoxide dismutase and catalase activities and HDL-c concentration but increased significantly ($p < 0.05$) the concentrations of malondialdehyde, total cholesterol, triacylglycerol, LDL-c and VLDL-c. The derangements were significantly more pronounced in the atherogenic predictor indices than with lipid profile values. The observed effects of otapiapia were significantly ($p < 0.05$) countered by administration of *M. oleifera* leaf extract.

Conclusion: The results indicate that *M. oleifera* is a potent anti-poison with ameliorative effect against otapiapia-induced changes in biomarkers of oxidative and atherogenic damages in animals.

Keywords: Drum stick; Anti-poison; Lipid profile; Pesticides; Drug antidote

Introduction

Otapiapia is a vernacular name of Eastern Nigeria origin. It is a household name for pesticides, which translates to 'that which completely consumes/devours'. Local pesticide producers emphasize the potency of their products with the name "otapiapia" indicating that such products will completely eradicate all pest problems at homes [1]. Its acceptance and widespread use in Nigeria could be attributed to its cheapness, efficacy, accessibility and affordability. Reports assert that otapiapia is an unspecified pesticide, whose application is regarded as dangerous practice since its chemical constituents are unknown [2]. However, some evidence indicates that dichlorvos is the major active pesticide ingredient of otapiapia formulations. Other chemical constituents reported to be contained in this locally formulated pesticide include toluene, (1-methylethyl)-benzene, 1,2,3-trimethyl benzene, decane, undecane, dodecane and 11,12-dibromotetradecan-1-ol acetate [3]. Some may also contain a homemade cocktail of kerosene, oil, alcohol or any other suitable solvent.

For pesticides to be effective against the pests intended for control, they must be biologically active. Thus, they are potentially hazardous to humans, animals, other organisms and the environment. Pesticide

toxicity can result from ingestion, inhalation or dermal absorption. People who use pesticides or regularly come in contact with them must understand the relative toxicity, potential health effects, and preventive measures needed to reduce exposure to the products they use [4]. Locally produced pesticides have led to many morbidity and mortality in Nigeria and the world at large [5,6]. Their effects being mainly via contamination of food [2]. Children are more prone to accidental poisoning by such products [7,8].

Moringa oleifera is the most widely cultivated species of the family, Moringaceae [9]. It is a slender, softwood small tree that branches freely and can be extensively fast growing. All parts of moringa tree are edible. Moringa-based food has been attributed to have a high protein, amino acids, micronutrients antioxidants, flavonoids and glucosinolate contents. It provides an important supplement to low-nutrition foods such as cereals and bulb crops. Moringa is known in the developing world as a vegetable, a medicinal plant and a source of vegetable oil [10]. It was employed for the treatment of different ailments in the indigenous system of medicine [11]. It has also been found scientifically to have various medicinal effects, as well as blood and water purifying potentials [12].

The present study is aimed at assessing the anti-poison potential of *Moringa oleifera* leaves. The study determined the ameliorative effects of the intake of ethanol extract of *M. oleifera* leaves on oxidative stress,

lipid profile and atherogenic indices of albino rats exposed to otapiapia contaminated feed.

Materials and Methods

Collection of otapiapia

The locally formulated pesticide, otapiapia was randomly purchased from Eke-onunwa Market in Owerri Municipal Area of Imo State. The pesticides bought were in 10 ml bottles. Examination of the bottles showed that product registration number and chemical contents were not displayed on any of the bottles.

Preparation of otapiapia contaminated feed

The content of ten bottles of the otapiapia were emptied into a conical flask and mixed. Then, 20 ml was measured out with a calibrated syringe, mixed with 20 ml of distilled water and evenly dispersed on 1000 g of growers' chicken feed (Guinea Feed Nigeria Ltd.). The contaminated feed was air-dried to a constant weight and stored in an air-tight bag at room temperature ready for use.

Collection of *Moringa* leaves

Healthy leaves of *M. oleifera* were obtained from an Agriculturist, Mr. Patrick Ezegbudo at Umuawulu, Anambra State, Nigeria. The leaves were authenticated at the Department of Forestry and Wildlife, Federal University of Technology, Owerri. The leaves were air-dried to a constant weight and milled to powder form.

Preparation of plant extract

The dried powdered leaves (500 g) were dissolved in 1200 ml of ethanol and the flask allowed to stand for 4 days with intermittent shaking. The solution was filtered with Whatman No. 1 filter paper into another glass jar of known weight and the filtrate was completely extracted with a soxhlet extractor. The ethanol extract obtained was concentrated to 140 g on a hot plate at 50°C. Suspensions of the extract were prepared in distilled water at 10 g per litre of water.

Experimental animals

Twenty-four male Swiss albino rats weighing 150-180 g used for the study were purchased from Animal Friend Ltd., Owerri, Imo State.

Treatment	Groups			
	Control	CFG	MOG	CF+MOG
Untaminated feed (100g/day)	√	-	√	-
Contaminated feed (100g/day)	-	√	-	√
Distilled water (15 ml/day)	√	√	-	-
Moringa oleifera	-	-	√	√

Table 1: Animal grouping and treatments. CFG: Contaminated Feed Group; MOG: Moringa oleifera Group; CF+MOG: Contaminated Feed +M. oleifera Group.

The animals were acclimatized to standard laboratory conditions of 12 h light/dark cycle for 14 days at the small animal House of the Department of Biochemistry, Federal University of Technology,

Owerri. They were provided with water and standard uncontaminated feed *ad libitum*. Later, the animals were weighed and randomly allotted into 4 groups of 6 animals each with similar average weight ranges per group. The animals were treated as shown in Table 1.

The contaminated and uncontaminated feed, distilled water and *M. oleifera* extract were freshly provided for each group every morning *ad libitum*. Ethical approval for all stages of the study was obtained from the Federal University of Technology Owerri ethical committee. The animals were humanely handled in accordance with the Principles of Laboratory Animal Care as described in NIH publication of 1985-1993.

Blood sample collection and processing

At the end of 14 days of treatment, the animals were fasted overnight, anaesthetized with diethyl ether vapour and whole blood was quickly collected by cardiac puncture. About 5 ml of blood collected was dispensed carefully into heparin bottle and thoroughly but gently mixed. The anticoagulated blood was centrifuged at 3000 rpm for 5 minutes and the plasma separated into freshly labeled bottle for determination of the biochemical parameters.

Analyses of biochemical parameters

The plasma samples were analyzed for the activities of catalase and superoxide dismutase using previously described methods [13,14], while the concentration of malondialdehyde was determined using Gutteridge and Wilkins method [15]. Total cholesterol (TC) and high density lipoprotein cholesterol (HDL-c) concentrations were respectively determined by enzymatic [16] and HDL-c precipitant [17] methods. Triacylglycerol (TG) concentration was assessed as earlier described [18]. The concentrations of plasma LDL-c and VLDL-c were calculated using previously published formulae [19,20].

The atherogenic predictor indices were estimated using the following formulae as earlier described [21,22].

Atherogenic Index of Plasma (AIP)=log TG/HDL-c;

Castelli's Risk Index I (CRI-I)=TC/HDL-c;

Castelli's Risk Index II (CRI-II)=LDL-c/HDL-c; and

Atherogenic Coefficient (AC)=(TC-HDL-c)/HDL-c.

Statistical analysis

One-way analysis of variance (ANOVA) and Turkey's post-hoc tests were carried out with the aid of GraphPad Prism version 5.3 software (GraphPad Inc., USA) to determine statistical differences between means of the animal groups. Values were adjudged statistically significant at $p \leq 0.05$.

Results and Discussion

Figure 1 shows that intake of the otapiapia contaminated feed significantly ($p < 0.05$) reduced serum activities of superoxide dismutase (SOD) and catalase (CAT), but significantly ($p < 0.05$) increased the malondialdehyde (MDA) concentration of the animals. SOD and CAT are the key antioxidant enzymes for cellular defense system against oxidative stress. SOD catalyzes the conversion of superoxides (O_2^-) to hydrogen peroxide (H_2O_2) and thus it is a major defense system for aerobic cells in combating the toxic effects of superoxide radicals. Meanwhile, the product of SOD catalysis is a harmful by-product of

many normal metabolic processes. To prevent H₂O₂ based damage to cells and tissues, it must be quickly converted into other less toxic substances. CAT is used by cells to rapidly catalyze the decomposition of H₂O₂ into less reactive gaseous oxygen and water molecules [23]. The SOD and CAT activities of the animals fed otapiapia contaminated feed were significantly lower than that of the control and *M. oleifera* groups. Toxicants induce disturbances in the physiological state of animals, which could affect enzyme activity. These may cause distortions in cell organelles, which may lead to either elevation or reduction in activity of enzymes, depending on whether there was a cellular damage releasing such enzymes into blood or disruption in the biosynthetic pathway of the enzyme protein [24].

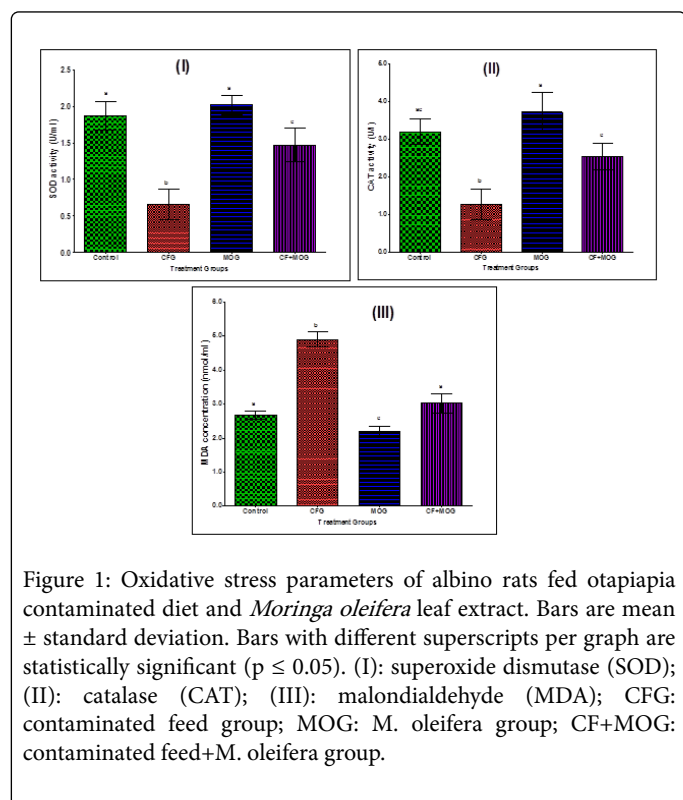


Figure 1: Oxidative stress parameters of albino rats fed otapiapia contaminated diet and *Moringa oleifera* leaf extract. Bars are mean ± standard deviation. Bars with different superscripts per graph are statistically significant (p ≤ 0.05). (I): superoxide dismutase (SOD); (II): catalase (CAT); (III): malondialdehyde (MDA); CFG: contaminated feed group; MOG: *M. oleifera* group; CF+MOG: contaminated feed+*M. oleifera* group.

MDA is a product that results from lipid peroxidation of polyunsaturated fatty acids and thus has been applied in the estimation of degree of peroxidation in tissues [25]. The observed significant increase in MDA of the toxicant's exposed animals buttresses the presence of oxidative stress in the exposed animals as indicated by the increased serum activities of SOD and CAT.

Moringa oleifera administration to intoxicated animals significantly (p<0.05) ameliorated the observed oxidative toxicity induced by otapiapia. The Figure shows that *M. oleifera* significantly improved CAT and SOD activities but reduced MDA concentrations to values comparable with those of the control animals. The result collaborates an earlier report that *M. oleifera* prevents acetaminophen induced liver injury through restoration of declined glutathione level [26]. The observation could be attributed to the presence in the plant of rich combination of antioxidant phytochemicals that have been reported to possess antioxidant, antitumour and antiinflammatory activities [11,12].

Intake of otapiapia intoxicated feed significantly (p<0.05) increased the plasma concentrations of TC, TG, LDL-c and VLDL-c as shown in

Table 2. On the other hand, the HDL-c concentration of the intoxicated animals reduced significantly. Administration of *M. oleifera*, which had opposite effects to those of otapiapia, significantly ameliorated the observed dyslipidaemia elicited by intake of the contaminated diet. The observed increases in the plasma TC, TG and LDL-c concentrations of otapiapia exposed animals is in agreement with the reported findings of hypercholesterolaemia and hypertriglyceridaemia after induction of organ injury such as in hepatotoxicity with common toxicants [27]. Organophosphate-based pesticides have been reported to cause an increase in total cholesterol and lipid levels [28]. The observed dyslipidaemia may be attributed to the effects of pesticide toxicants on the permeability of liver cell membranes or the blockage of liver bile ducts, causing a reduction or cessation of cholesterol secretion into the duodenum [29].

Parameters (mmol/l)	Groups			
	Control	CFG	MOG	CF+MOG
TC	3.73 ± 0.13 ^{ac}	3.94 ± 0.11 ^a	2.57 ± 0.20 ^b	3.59 ± 0.23 ^c
TG	1.56 ± 0.05 ^a	2.45 ± 0.04 ^b	1.52 ± 0.08 ^a	1.66 ± 0.07 ^a
HDL-c	0.94 ± 0.06 ^a	0.46 ± 0.05 ^b	1.47 ± 0.07 ^c	0.82 ± 0.08 ^a
LDL-c	0.72 ± 0.07 ^a	1.61 ± 0.03 ^b	0.67 ± 0.10 ^a	0.96 ± 0.06 ^c
VLDL-c	0.26 ± 0.02 ^{ac}	0.32 ± 0.01 ^b	0.23 ± 0.03 ^a	0.28 ± 0.03 ^c

Values are mean ± standard deviation. Values with different superscripts per row are statistically significant (p ≤ 0.05). TC: Total Cholesterol; TG: Triacylglycerol; HDL-c: High Density Lipoprotein Cholesterol; LDL-c: Low Density Lipoprotein Cholesterol; VLDL-c: Very Low Density Lipoprotein Cholesterol; CFG: Contaminated Feed Group; MOG: *M. oleifera* Group; CF+MOG: Contaminated Feed+*M. oleifera* Group.

Table 2: Lipid and lipoprotein profile parameters of albino rats fed Otapiapia contaminated diet and *Moringa oleifera* leaf extract.

The observed cholesterol lowering ability of *M. oleifera* could be attributed to its saponin content [30]. Saponins prevent excessive intestinal absorption of cholesterol and thus have been associated with the risk reduction for cardiovascular diseases [31]. The observed significant elevation of HDL-c concentration in animals administered *M. oleifera* further indicates its beneficial effect against cardiovascular diseases. HDL-c is synthesized and secreted by liver cells.

It removes excess cholesterol from circulation and carries them back to the liver for degradation or conversion to bile acids [32]. Table 3 shows the effect of intake of otapiapia contaminated diet on atherogenic predictor indices of the animals. The results showed that the intoxicated diet significantly (p<0.05) increased the serum total non-HDL cholesterol concentration with concomitant significant increases in Castelli's risk index I (TC/HDL-c) and II (LDL-c/HDL-c). The diet also significantly increased atherogenic coefficient (TC - HDL-c)/HDL-c and atherogenic index of plasma (log TG/HDL-c) levels of the treated animals. These are as expected since they are calculated based on the use of HDL-c value as the denominator. Thus, reduction in HDL-c concentration as elicited by the intake of otapiapia led to significantly high values for the atherogenic indices.

Interestingly, administration of *M. oleifera* significantly ($p < 0.05$) ameliorated the observed effects of otapiapia intoxication.

Parameters	Groups			
	Control	CFG	MOG	CF+MOG
TC/HDL-c	3.97 ± 0.16 ^a	8.56 ± 0.27 ^b	1.75 ± 0.32 ^c	4.38 ± 0.23 ^a
LDL-c/HDL-c	0.77 ± 0.13 ^a	3.50 ± 0.19 ^b	0.46 ± 0.17 ^c	1.17 ± 0.10 ^d
Total non-HDL-c (mmol/l)	2.79 ± 0.07 ^a	3.48 ± 0.15 ^b	1.10 ± 0.09 ^c	2.77 ± 0.18 ^a
(TC-HDL-c) / HDL-c	2.97 ± 0.10 ^a	7.56 ± 0.23 ^b	0.75 ± 0.18 ^c	3.38 ± 0.26 ^d
Log TG/HDL-c	0.22 ± 0.01 ^a	0.73 ± 0.05 ^b	0.12 ± 0.01 ^c	0.31 ± 0.04 ^d

Table 3: Atherogenic predictor indices of albino rats fed otapiapia contaminated diet and *Moringa oleifera* leaf extract.

These observations were significantly more pronounced in the atherogenic predictor indices than with the exact lipid profile values as reported in Table 2. This further buttresses the link between derangements in lipid profile and the atherogenic predictor indices. However, it also indicates that the calculated atherogenic predictor indices may be better indicators than lipid profile parameters in monitoring of diseases associated with dyslipidaemia. These findings agree with the earlier reports that determination of the relative proportions of cholesterol in proatherogenic (TC, TG, and LDL-c) and antiatherogenic (HDL-c) lipoproteins are more valuable than the individual lipid measurements in cardiovascular disease (CVD) risk assessment [33].

Conclusion

Intake of feed contaminated with otapiapia, an organophosphate based pesticide, caused significant decreases in plasma activities of antioxidant enzymes and HDL-c concentrations but increased concentrations of MDA, TC, TG, LDL-c and VLDL-c. It also led to increases in atherogenic predictor indices suggesting possible induction of oxidative stress, dyslipidaemia and associated cardiovascular risk in exposed subjects. Administration of *M. oleifera* extract significantly ameliorated the effects of the otapiapia exposure. The results indicate that *M. oleifera* could be an effective antidote to pesticide-induced oxidative damage, lipid abnormality and other possible atherogenic complications thereof in animals. Further studies are needed to explain the mechanism of pesticide-induced oxidative and lipid abnormality and to ascertain the component(s) of *M. oleifera* extract with the observed potentials.

References

- Mortui C (2006) Igbo lesson. Nijaryders.
- Akunyili D (2007) Otapiapia' not registered with NAFDAC. Daily Triumph Newspaper.
- Ofordile CP, Okoye PAC, Raphael P (2014) Determination of actual chemical composition of a locally formulated pesticide product in a Nigerian market. Int J Sci Technol 3:264-268.
- Lorenz ES (2009) "Potential Health Effects of Pesticides". Ag Communications and Marketing 1-8.
- USEPA (2007) Dichlorvos TEACH Chemical Summary U.S. EPA. Toxicity and Exposure Assessment for Children.
- Olebunne CE (2009) Social Entrepreneurship; The Nigerian Perspective.
- Okeniyi SO, Adedoyin BJ, Garba S (2013) Phytochemical Screening, Cytotoxicity, Antioxidant and Antimicrobial Activities of Stem and Leave Extracts of Euphorbia heterophylla. J Biol Lif Sci 4: 24-31.
- Gilden RC, Huffling K, Sattler B (2010) Pesticides and health risks. J Obstet Gynecol Neonatal Nurs 39: 103-110.
- Mahmood KT, Mugal T, Haq IU (2010) Moringa oleifera: A natural gift-A review. J Pharmacy 2: 775- 781.
- Paliwal R, Sharma V, Pracheta SS (2011) A review of Horse Radish Tree (*Moringa oleifera*): A Multipurpose Tree with High Economic and Commercial Importance. As J Biotechnol 3: 317-328.
- Anwar F, Latif S, Ashraf M, Gilani AH (2007) Moringa oleifera: a food plant with multiple medicinal uses. Phytother Res 21: 17-25.
- Kumar V, Pandey N, Mohan V, Singh RP (2012) Antibacterial and antioxidant activity of extract of Moringa oleifera leaves-An in vitro study. Int J Pharm Scis Rev Res 12: 89-94
- Sinha AK (1972) Colorimetric assay of catalase. Anal Biochem 47: 389-394.
- Olatosin TM, Akinduko DS, Uche CZ, Bardi J (2014) Effects of Moringa oleifera seed oil on acetaminophen-induced oxidative stress and liver damage in Wistar albino rats. IOSR J Pharm Biolo Sci 9: 53-59.
- Gutteridge JMC, Wilkins S (1982) Copper-dependent hydroxyl radical damage to ascorbic acid: formation of a thiobarbituric acid reactive product. Federation of European Biomedical Societies Letters 327-330.
- Allain CC, Poon LS, Chan CSG, Richmond W, Fu PC (1974) Enzymatic Determination of total serum cholesterol. Clin Chem 20: 470-475.
- Lopes-Virella MF, Stone P, Ellis S, Colwell JA (1977) Cholesterol determination in high-density lipoproteins separated by three different methods. Clin Chem 23: 882-884.
- Bucolo G, David H (1973) Quantitative determination of serum triglycerides by the use of enzymes. Clin Chem 19: 476-482.
- Friedewald WT, Levy RL, Fredrickson DS (1972) Estimation of the concentration of low density lipoprotein cholesterol in plasma without use of the preparative ultracentrifuge. Clin Chem 18: 499-502.
- Crook MA (2006) Plasma lipids and Lipoproteins. In: Clinical Chemistry and Metabolic Medicine, 7th edn, Edward Arnold publishers Ltd., UK.
- Bhardwaj S, Bhattacharjee J, Bhatnagar MK, Tyagi S (2013) Atherogenic index of plasma, Castelli Risk Index and Atherogenic coefficient-New parameters in assessing Cardiovascular Risk. Int J Pharm Biol Sci 3: 359-364.
- Castelli WP, Abbott RD, McNamara PM (1983) Summary estimates of cholesterol used to predict coronary heart disease. Circulation 67: 730-734.
- Chelikani P, Fita I, Loewen PC (2004) Diversity of structures and properties among catalases. Cell Mol Life Sci 61: 192-208.
- Mahmoud K, Shalahmetove T, Deraz SH (2011) Effect of crude oil intoxication on antioxidant and marker enzymes of tissue damage in liver of rats. Inter J Biol Veteri Agric Food Enginer. 5: 93-96.
- Davey M, Stals E, Panis B, Keulemans J, Swennen R (2005) High-throughput determination of malondialdehyde in plant tissues. Anal. Biochem. 347: 201-207.
- Fakurazi S, Hairuszah I, Nanthini U (2008) Moringa oleifera Lam prevents acetaminophen induced liver injury through restoration of glutathione level. Food Chem Toxicol 46: 2611-2615.
- Aba PE, Eneasato CP, Onah JA (2016) Effect of Quail Egg Pretreatment on the Lipid Profile and Histomorphology of the Liver of Acetaminophen-Induced Hepatotoxicity in Rats. J Applied Biol Biotech 4: 034-038.
- Kalender S, Ogutcu A, Uzunhisarcikli M, Açikgoz F, Durak D, et al. (2005) Diazinon-induced hepatotoxicity and protective effect of vitamin E on some biochemical indices and ultrastructural changes. Toxicology 211: 197-206.

-
29. Zaahkook SM, Helal EE, Abd-Rado TI, Rashed SA (2000) Carbamate toxicity and protective effect of Vit A and Vit E on some biochemical aspects of male albino rats. Egyptian J Hosp Medici 1: 60-77.
 30. Adesina SK (2005) The Nigerian Zanthoxylum: Chemical and Biological Values African. Compl Alter Med 2: 282-381.
 31. Olaleye MT (2007) Cytotoxicity and antibacterial activity of methanolic extract of Hibiscus sabdariffa. J Med Plant Res 1: 009-013.
 32. Rahilly Tierney CR, Spiro A, Vokonas P, Gaziano JM (2011) Relation between high-density lipoprotein cholesterol and survival to age 85 years in men (from the VA normative aging study). Am J Cardiol 107: 1173-1177.
 33. Ranjit PM, Guntuku G, Pothineni RB (2015) New atherogenic indices: Assessment of cardiovascular risk in postmenopausal dyslipidemia. Asian J Med Sci 6: 25-32.