

Ectopic Syringoma with Localized Alopecia in Axillary Region

Shin Han Kim, Jae Wan Go and Han Kyoung Cho*

Departments of Dermatology, Myongji Hospital, Kwandong University College of Medicine, Goyang-si, Gyeonggi-do, Korea

Abstract

Syringomas are common benign neoplasm of eccrine gland. Usually syringomas are encountered in face, especially periorbital region. However, in uncommon cases, these tumors arise at atypical site with discrete clinical feature. In other side, there has been lots of discussions that focus on relationship of alopecia, cicatricial or not, and syringoma. Herein, we report a case of syringoma as grouped yellowish papules in axillary region with localized alopecia.

Keywords: Alopecia; Axillae; Syringoma

Introduction

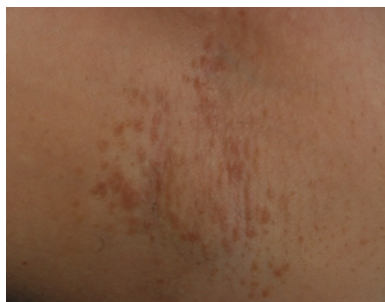Syringomas are common benign tumors of skin, predominantly occur in the second and third decades with affection in female [1]. It usually arise at lower eyelids and upper cheek and other affected locations are abdomen, vulva, scalp, forehead, extremities, buttock, axillae, less commonly.

There have been numerous investigations about relationship of syringoma and other dermatologic disease. Syringomas are occasionally associated with inflammatory cutaneous disease and other skin tumor. In recent decades, rare cases of alopecia accompanied with occult type syringoma had been reported. Although syringomas are known to be able to induce fibrosis with inflammatory response and provoke alopecia, the clear mechanism of it is still uncertain. Herein, we report here on a rare case of axillary syringoma with localized alopecia.

Case Report

A 20-year-old Korean woman presented a 10-year-history of asymptomatic multiple papules on her both axillae. She was unremarkable of medical history and family history. At physical examination, several 2~3mm sized, yellow-brown or tan colored papules in bilateral axillae. (Figure 1) There were not any similar papules on her eyelids. Papules on axillae were discrete from follicular orifices or skin pores. She did not ever have hairs in both axillary regions and there were not mature or vellus hairs in close visual inspection. Patient had normal scalp and pubic hairs and those were same in extremities.

Laboratory analyses of common blood count, blood chemistry and urinalysis were within normal limits. Histopathologic examinations were done by 4-mm punch biopsy. The histopathology showed



(A)

Figure 1: Characteristic several 2~3mm sized, yellow-brown or tan colored papules in axillae. Note that there are no mature or vellus hair on Aug. 20, 2010, when patient was visited to our Hospital (A).

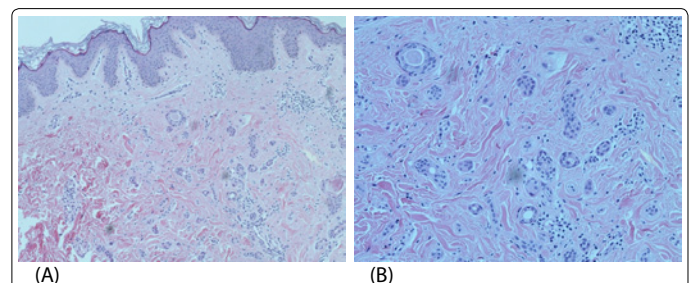


Figure 2: Histological examinations of a brownish papule revealed epithelial strand and small duct dispersed in a fibrous stroma in dermis. (A, H&E x100) Wall of the ducts are lined by single or double rows of epithelial cells. Some duct presents characteristic comma-like tails as "tadpole" configuration. (B, H&E x200).

small multiple ductal and cystic structure presentation, which are surrounded by connective tissues of dermis along with epithelial strands. Ductal structures are along with single layered epithelial cells and some presents a "tadpole" configuration. (Figure 2) These findings were consistent with diagnosis of syringoma. In addition, there were no histologic pilosebaceous units in specimen. Patient was advised with treatment of topical tretinoin and CO₂ laser ablation therapy, but she did not want treatment.

Discussion

Syringomas are benign tumors of eccrine duct and predominantly occur in women at the second and third decades, with typical onset at puberty. In these days, syringomas are not believed to be hereditary, although familial cases have been reported [2]. Associated several systemic diseases with this tumor were reported, especially in patients

***Corresponding authors:** Han Kyoung Cho, M.D, Departments of Dermatology, Myongji Hospital, Kwandong University College of Medicine, 697-24 Hwajeong-dong, Deokyang-gu, Goyang-si, Gyeonggi-do, Korea, Tel: 8231810543; Fax: 82318107057; E-mail: dermy@kd.ac.kr

Received November 14, 2010; **Accepted** January 05, 2011; **Published** January 10, 2011

Citation: Kim SH, Go JW, Cho HK (2011) Ectopic Syringoma with Localized Alopecia in Axillary Region. J Clin Exp Dermatol Res 2:116. doi:10.4172/2155-9554.1000116

Copyright: © 2011 Kim SH, et al. This is an open-access article distributed under the terms of the Creative Commons Attribution License, which permits unrestricted use, distribution, and reproduction in any medium, provided the original author and source are credited.

with Down syndrome or diabetes mellitus, however, syringomas are generally more common in individuals with no other comorbid conditions.

Eccrine sweat ducts are normally distributed in skin, typically at palm and sole, axillary region, and forehead, but they are absent in mucocutaneous border of lip, nail bed, labia minora, glans pedis and inner aspect of the prepuce. Syringomas are generally known to originate from the straight portion of the intradermal eccrine sweat duct. Most commonly involved sites are head and neck region, particularly on the eyelids. Also they are seen at scalp, forehead, cheeks, abdomen, extremities, genitalia and buttocks [3]. Friedman and Butler classified syringomas in a pattern of distribution and clinical feature as localized, familial, Down syndrome associated, and generalized form [4].

Clinically, syringomas appear as multiple, flesh colored or yellowish, round or flat-topped firm papules, ranging from 1-5mm in diameter. Typically follow a bilateral, symmetric pattern; although, rare cases of unilateral occurrences have been reported [5]. Patients may complain of mild to moderate itching sense, but often the lesions are asymptomatic and more of a cosmetic concern.

On histologic finding, syringomas have a symmetrical, well-circumscribed appearance and are confined to the upper dermis with no connection to the overlying epidermis [6]. Epithelial cell proliferations are arranged in cords, nests, or tubules, which can display the characteristic "comma" or "tadpole" shapes, and are all embedded in a fibrous dermal stroma [3,6]. Monomorphous cuboidal epithelial cells with small normochromatic nuclei and a small to moderate amount of pale eosinophilic cytoplasm line the tubules in a single or double layer. There are subsets of tumors in which the neoplastic cells display abundant clear cytoplasm [6]. In histochemical stain, syringomas react strongly with lysozymes, epithelial membrane antigen, antibodies to the breast cystic fluid proteins GCDPF-15 and 24, and with S100, the carcinoembryonic antigen [7].

In our case, patient presented syringomas with localized alopecia in axillary region. There were various discussions about relationship of cutaneous tumors and alopecia lesions. One of the well known phenomena is scalp alopecia due to a clinically unapparent or minimally apparent neoplasm (SACUMAN) [8]. The mechanism of SACUMAN is infiltration of tumor cells in dermis, and this cells are directly overrun the normal cellular population and induce destruction of pilosebaceous units. Additionally, tumor cells can produce cytokines and interleukin which provoke inflammation of skin, which induce dermal fibroplasia and lacking follicular structure. This inflammatory cascade makes SACUMAN as irreversible cicatricial alopecia. Causes of SACUMAN are various from benign disorder to malignant neoplasm. Syringomas are representative cause of benign neoplasm in SACUMAN. Malignant tumors such as breast cancer, gastric cancer may be metastatic cause and basal cell carcinomas, melanoma, angiosarcoma, and syringomatous carcinomas can be localized cause.

Also, rare cases about alopecia associated with occult syringomas had been reported [9-10]. Generally occult syringoma is defined as eccrine ductal hyperplasia without clinical findings and histologically it shows multiple cystic or ductal hyperplasia with lining of single or double layered epithelial wall, similar as syringoma except no comma or tadpole shapes. Mehregan et al. [9] reported alopecia with underlying occult syringomas related to fibrosis with scar formation result from secondary inflammation. In other hand, Shelley and Wood [10] reported syringomas induce changing of dermal stroma and this converted stromal material invades pilosebaceous unit and cause atrophy or degeneration of hair follicle that evoke alopecia.

Though treatment is rarely indicated, it is often requested for cosmetic reasons. Treatment options include dermabrasion, cryosurgery, electrodesiccation, excision, laser ablation, oral and topical retinoids and atropine. Unfortunately, treatment is often unsatisfactory due to potential scarring, pigmentary alterations, and recurrence.

Our patient shows quite discrete clinical feature as multiple brownish papules limited to the both axillae and localized alopecia where it involved. We could find no similar case of syringomas in the medical literature, so suggest it as first report of unusual cutaneous manifestation of ectopic presentation of syringomas in combination with secondary alopecia. Additionally, it can be a proof that SACUMAN or occult syringomas, which can cause alopecia in scalp region, are not only limited to scalp, but also induce localized alopecia in any site where syringomas involved. Physicians should know the various clinical forms of syringomas and must consider syringomas when making the differential diagnosis of papular lesions of the axillae. In addition, we suggest it as another evidence of syringoma that can be cause of alopecia or induce follicular atrophy.

References

1. Butterworth T, Strean LP, Beerman H, WOOD MG (1964) Syringoma and mongolism. *Arch Dermatol* 90: 483-487.
2. Yesudion P, Thomblah A (1975) Familial syringoma. *Dermatologica* 150: 32-35.
3. Nguyen DB, Patterson JW, Wilson BB (2003) Syringoma of the moustache area. *J Am Acad Dermatol* 49: 337-339.
4. Friedman SJ, Butler DF (1987) Syringoma presenting as milia. *J Am Acad Dermatol* 16: 310-314.
5. Chi HI (1996) A case of unusual syringoma: unilateral linear distribution and plaque formation. *J Dermatol* 23: 505-506.
6. Obaidat NA, Alsaad KO, Ghazarian D (2007) Skin adnexal neoplasm part 2: An approach to tumours of cutaneous sweat glands. *J Clin Pathol* 60: 145-159.
7. Ambrojo P, Requena Caballero L, Aquilar Martinez A, Sánchez Yus E, Furió V (1989) Clear cell syringoma. *Dermatologica* 178: 164-165.
8. Scheinfeld N (2006) Review of scalp alopecia due to a clinically unapparent or minimally apparent neoplasm(SACUMAN). *Acta Derm Venereol* 86: 387-392.
9. Mehregan AH (1981) Proliferation of sweat ducts in certain diseases of the skin. *Am J Dermatopathol* 3: 27-30
10. Shelley WB, Wood MG (1980) Occult syringomas of scalp associated with progressive hair loss. *Arch Dermatol* 116: 843-844.