

Ebstein-Barr Virus-Associated Iris Leiomyosarcoma in an AIDS Patient : A Case Report

Yanin Suwan^{1*}, Duangnate Rojnapor¹, Chaiwat Teekhasaenee¹ and Rangsim Aroonroch²

¹Department of Ophthalmology, Faculty of Medicine, Ramathibodi Hospital, Mahidol University, Bangkok, Thailand

²Department of Pathology, Faculty of Medicine, Ramathibodi Hospital, Mahidol University, Bangkok, Thailand

*Corresponding author: Yanin Suwan, M.D., Department of Ophthalmology, Faculty of Medicine, Ramathibodi Hospital, Mahidol University, Bangkok, Thailand, Tel: 662-201-2729; Fax: 662-354-7280; E-mail: yanin.suwan@gmail.com

Received date: April 29, 2014, Accepted date: June 09, 2014, Published date: June 16, 2014

Copyright: © 2014 Suwan Y, et al. This is an open-access article distributed under the terms of the Creative Commons Attribution License, which permits unrestricted use, distribution, and reproduction in any medium, provided the original author and source are credited.

Abstract

Importance: Report of an AIDS patient with Ebstein-Barr virus (EBV)-associated iris leiomyosarcoma.

Observations: A 19-year-old AIDS patient presented with a painless rapidly growing mass in the right iris. EBV-associated leiomyosarcoma was confirmed by an immunohistochemical study of the excisional biopsy.

Conclusion: This is the second case report on immunohistochemically proven EBV-associated iris leiomyosarcoma in AIDS.

Keywords: Human immunodeficiency virus (HIV); Acquired immunodeficiency syndrome (AIDS); Iris tumor; Ebstein-Barr virus; Leiomyosarcoma

Introduction

AIDS patients have an increased susceptibility to develop multiple malignant neoplasms. The association between leiomyosarcoma and EBV in AIDS is widely recognized [1]. The sarcoma commonly occurs in gastrointestinal tract, uterus and lungs [1]. Less commonly, it can also involve liver, spleen, adrenal gland, lesser sphenoidal wing, cavernous sinus, and orbit [2,3]. However, leiomyosarcoma rarely occurs in the uveal tract. There has been only one case report of EBV-associated iris leiomyosarcoma in the English literature [4]. We are reporting another AIDS patient with EBV-associated iris leiomyosarcoma.

Case Report

A 19-year-old Thai male developed a painless iris mass in the right eye 2 months previously. He has been suffering from vertically transmitted AIDS for 10 years. The most recent CD4 count was 4 cells/mm³. He was currently taking Isoniazid, Pyrazinamide, Levofloxacin, and Cycloserine for active pulmonary tuberculosis.

Best corrected visual acuity was 20/150 OD and 20/80 OS. Slit-lamp biomicroscopy in the right eye revealed an oval demarcated yellowish iris mass with 3.6 mm horizontal diameter and 4.7 mm vertical diameter extending from 4:00 to 7:00 o'clock positions with engorged and tortuous limbal vessels traversing across the tumor surface into the anterior chamber (Figure 1A). Slit-lamp biomicroscopy in the left was unremarkable. Dilated ophthalmoscopy revealed inactive CMV retinitis confined in the posterior pole OU. Gonioscopy showed a tumor occupying the inferior peripheral iris adjacent to the anterior chamber angle, which remained open. A blood reflux into the nearby schlemm's canal was observed. Initial ultrasound biomicroscopy

(UBM) revealed a hypoechoic oval mass extending from the pupil. The largest diameter was 4.42 mm radially from pupillary border towards the limbus and the thickness was 2.54 mm by ultrasonic measurements (Figure 1B). The patient lost to follow up and returned to our hospital two months later. His visual acuity decreased to hand motion. Slit lamp biomicroscopy showed a significant enlargement of the iris mass (8.93 mm horizontal diameter, 9.34 mm vertical diameter) displacing the entire pupil towards superiorly (Figure 1C). In addition, it expanded anteriorly pressing on corneal endothelium (Figure 1D). Gonioscopy showed a large iris mass extending from four to seven o'clock positions obscuring the anterior chamber angle view. Fiberoptic limbal transillumination fail to demonstrate ciliary body shadow. Since the tumor confined in the iris tissue only without ciliary body extension, a sectoral iridectomy was performed removing the entire iris mass. There was minimal intraoperative hemorrhage. The histopathological examination showed intersecting fascicles of mildly differentiated atypical smooth muscle cells with an increased mitotic activity and admixing intralesional lymphocytes (Figure 2A). The immunohistochemical studies were positive for Smooth Muscle Actin (SMA) (Figure 2B) and Caldesmon, but negative for S100 protein and HMB45 (Figure 2C). The *in situ* hybridization for EBV-encoded RNA (EBER) was also positive (Figure 2D). Neither acid fast bacilli nor fungi were identified by the acid fast and GMS stain. The diagnosis of iris leiomyosarcoma was established. There has been no tumor recurrence during 1 year follow up. Visual acuity improved but limited to 20/80 OD due to CMV retinitis.

Comment

Iris leiomyosarcoma is an extremely rare malignant tumor [4-6]. It arises from the dilator and sphincter muscles, which are of neuroectoderm in origin. Ebstein-Barr virus has been intimately associated, though not necessarily in a causal fashion, with multiple malignancies in AIDS including Burkitt's lymphoma, nasopharyngeal carcinoma, Hodgkin's disease, B-cell lymphomas [1], and leiomyosarcoma [4,5,7,8].

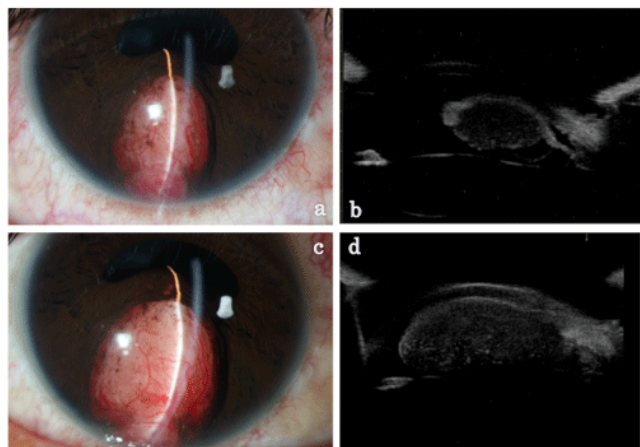


Figure 1: (a) A well circumscribed amelanotic iris mass with prominent feeding vessels over the surface. (b) Initial UBM revealed a hypoechoic mass in the iris stroma with 3.6 mm horizontal diameter and 4.7 mm vertical diameter, in the absence of a visible peduncle. (c) The iris mass doubled in size within 2 months displacing the entire pupil superiorly. (d) Successive UBM at two months later disclosed a significant enlargement of the iris mass occupying 70 percent of anterior chamber volume.

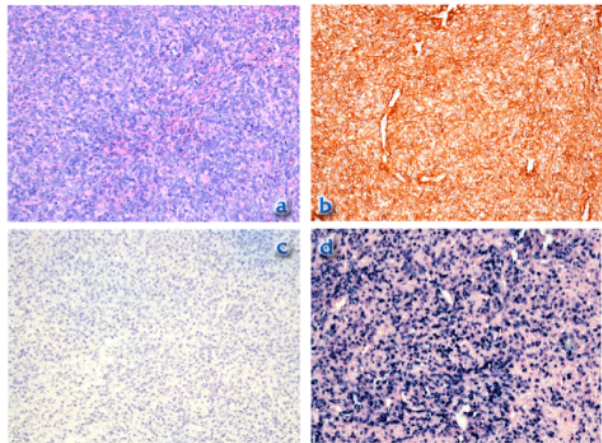


Figure 2: (a) The histopathology illustrated intersecting fascicles of smooth muscle cells with some nuclear atypia, increase mitotic activity and admixed intralesional lymphocytes (H&E, 200x). (b) The immunohistochemical study for SMA is positive (SMA, 200x). (c) The immunohistochemical study for HMB45 is negative (HMB45, 200x). (d) The in situ hybridization for EBER is positive (EBER, 200x).

Although intraocular leiomyosarcoma has a potential to spread locally, it rarely metastasizes to distant organs resulting in an excellent survival prognosis [9]. In contrast to primary orbital leiomyosarcoma, which has a guarded survival prognosis due to its strong tendency to recur and metastasize [10].

Since there may be transitional cells in between melanocytes and smooth muscles, histological differentiation of leiomyoma/leiomyosarcoma from amelanotic spindle cell melanoma is difficult without electron microscopy and immunohistochemical studies. Foss et al. [6] had shown 24 cases that had been initially diagnosed for smooth muscle origin were all melanocytic neoplasms when studied with appropriate immunohistochemical studies. Due to lightly pigmented nature of the tumor, transillumination defects may be difficult to determine tumor extension. Fluorescein angiography has suggested a valuable tool to establish the extension of the tumor [11].

Although several cases of iris leiomyosarcoma have been reported in the literature, only one was proved to have EBV-associated leiomyosarcoma by immunohistochemical studies [4,9]. Our patient is the second case report with immunohistochemically proven EBV associated iris leiomyosarcoma. Our patient was fifteen years older than the previous case. Serial slit-lamp photography documented a hundred percentage enlargement of the tumor dimension within two months. Although the iris mass in our patient was much larger than that of the previous patient, it was surprisingly quiet and minimally disturbed the patient. Both of them shared a common feature of having a very low CD4 count, which might favor the tendency of this condition to occur in a severely compromised host.

References

1. McClain KL, Leach CT, Jenson HB, Joshi VV, Pollock BH, et al. (1995) Association of Epstein-Barr virus with leiomyosarcomas in children with AIDS. *N Engl J Med* 332: 12-18.
2. Zevallos-Giampietri EA, Yañes HH, Orrego Puelles J, Barrionuevo C (2004) Primary meningeal Epstein-Barr virus-related leiomyosarcoma in a man infected with human immunodeficiency virus: review of literature, emphasizing the differential diagnosis and pathogenesis. *Appl Immunohistochem Mol Morphol* 12: 387-391.
3. Zetler PJ, Filipenko JD, Bilbey JH, Schmidt N (1995) Primary adrenal leiomyosarcoma in a man with acquired immunodeficiency syndrome (AIDS). Further evidence for an increase in smooth muscle tumors related to Epstein-Barr infection in AIDS. *Arch Pathol Lab Med* 119: 1164-1167.
4. Tulvatana W, Pancharoen C, Mekmullica J, Thisyakorn U, Tinnungwattana U, et al. (2003) Epstein-Barr virus-associated leiomyosarcoma of the iris in a child infected with human immunodeficiency virus. *Arch Ophthalmol* 121: 1478-1481.
5. Suankratay C, Shuangshoti S, Mutirangura A, Prasanthai V, Lerdlum S, et al. (2005) Epstein-Barr virus infection-associated smooth-muscle tumors in patients with AIDS. *Clin Infect Dis* 40: 1521-1528.
6. Foss AJ, Pecorella I, Alexander RA, Hungerford JL, Garner A (1994) Are most intraocular "leiomyomas" really melanocytic lesions? *Ophthalmology* 101: 919-924.
7. Levine PH, Blattner WA (1992) The epidemiology of human virus-associated hematologic malignancies. *Leukemia* 6 Suppl 3: 54S-59S.
8. Gaffey MJ, Weiss LM (1992) Association of Epstein-Barr virus with human neoplasia. *Pathol Annu* 27 Pt 1: 55-74.
9. Dugmore WN (1972) 11-year follow up of a case of iris leiomyosarcoma. *Br J Ophthalmol* 56: 366-367.
10. Meekins BB, Dutton JJ, Proia AD (1988) Primary orbital leiomyosarcoma. A case report and review of the literature. *Arch Ophthalmol* 106: 82-86.
11. Sevel D, Tobias B (1972) The value of fluorescein iridography with leiomyoma of the iris. *Am J Ophthalmol* 74: 475-478.