

## Early Infantile Galactosialidosis Presenting with an Unusual Renal Involvement

Banu Guzel Nur<sup>1</sup>, Gulsah Kaya Aksoy<sup>2</sup>, Mustafa Koyun<sup>2</sup>, Sema Akman<sup>2</sup> and Ercan Mihci<sup>1\*</sup>

<sup>1</sup>Akdeniz University School of Medicine, Department of Pediatrics, Division of Pediatric Genetics, Antalya, Turkey

<sup>2</sup>Akdeniz University School of Medicine, Department of Pediatrics, Division of Pediatric Nephrology, Antalya, Turkey

### Abstract

Galactosialidosis is a rare lysosomal storage disease associated with deficiencies of beta-galactosidase and neurominidase. In this report, we present a 9-month-old early infantile Galactosialidosis infant with renal involvement. In the literature only isolated cases of Galactosialidosis with IgA nephropathy, renal insufficiency and renal transplantation reported. To the best of our knowledge, the patient is the first case reported in the literature in which steroid resistant nephrotic syndrome has been found in a Galactosialidosis patient.

**Keywords:** Galactosialidosis; Steroid resistant nephrotic syndrome; Early infantile form

### Introduction

Galactosialidosis (GS; OMIM 256540) is a rare lysosomal storage disorder caused by deficiency of the protective protein/cathepsin A (PPCA). It is transmitted as an autosomal recessive trait. Protective protein/cathepsin A forms a complex with beta-galactosidase and alpha-neuraminidase and in turn controls the lysosomal compartmentalization, catalytic activation, and stability of the two glycosidases. A mutation in the CTSA gene that encoding PPCA localized on chromosome 20q13.1 were found to be responsible [1].

Galactosialidosis patients present a combination of clinical and biochemical findings of that are typical of those found both in GM1-gangliosidosis and sialidosis types I/II. Three galactosialidosis subtypes are recognized based on age of onset and the severity of clinical manifestations [2]. The early infantile form (type 1) mainly characterized by hydropsfetalis, cherry red spots, hepatosplenomegaly, psychomotor delay, coarse facies, skeletal dysplasia, and early death. Late infantile form (type 2) is characterized by corneal clouding, cardiac involvement, visceromegaly, growth retardation and, rarely, psychomotor retardation. Most patients with the milder juvenile/adult form (type 3) mainly exhibited myoclonus, ataxia, neurological deterioration, mental retardation, angiokeratoma, absence of visceromegaly. Late infantile and juvenile/adult galactosialidosis are slowly progressive diseases that are less severe than the early infantile type. Juvenile/adult form of galactosialidosis is typically associated with a normal life expectancy [3,4].

Nephrotic syndrome is a clinical condition characterized by massive proteinuria, hypoalbuminemia, hypercholesterolemia, and generalized edema. It occurs more commonly in children than in adults, and usually manifests as one of two usually idiopathic diseases: Minimal change nephrotic syndrome or focal segmental glomerulosclerosis. Other histological patterns of nephrotic syndrome seen in children include membranoproliferative glomerulonephritis, and rarely membranous nephropathy and diffuse mesangial hypercellularity. Children having steroid resistant nephrotic syndrome with focal and segmental glomerular sclerosis run a high risk of resistance to immunosuppressive therapy [5,6].

In galactosialidosis patients only a few cases with renal involvement determined. Here, we report a galactosialidosis patient with steroid resistant nephrotic syndrome. The aim of the present report is to

both describe the characteristic features of this rare disease, and draw attention to galactosialidosis association with steroid resistant nephrotic syndrome.

### Case Report

A 9-month-old male admitted to hospital with abdominal distention and limb edema. He was born at 37 weeks of gestation as a second child of consanguineous parents. Fetal ultrasound and family history was normal. At age of 2 month he had inguinal hernia operation. On physical examination, birth length was 46 cm (<3th percentile), birth weight was 2650 g (10th percentile), and head circumference was 33cm (3-10th percentile). Blood pressure was 110/60 mmHg and heart rate was 90 beats/min. He didn't hold his head and eye-tracking had just begun. Muscular hypotonia, coarse face, broad forehead, hypertelorism, bitateral epicanthus, depressed nasal bridge, broad nasal tip, low-set ears, gingival hypertrophy, pectus carinatus, shorth neck, abdomen distention, hepatosplenomegaly, ascites, scrotal edema, thoracolumbar gibbus, and psychomotor retardation detected. Facial dysmorphism at age of 10 month seen in the Figure 1.

The skeletal survey showed the ovoid spine, beaked vertebra and lumbar scoliosis (Figure 2). The long bones and the pelvis appeared normal. Echocardiography detected mitral insufficiency. Ophthalmological evaluation was normal. Abdominal ultrasound showed bilateral grade 2 echogenity, enlarged kidneys and ascites.

Nephrological evaluation showed hypoalbuminemia (1.9 gr/dl), massive proteinuria (urine protein/creatinine ratio of 3.5 mg/mg) and hypertriglyceridemia (521 mg/dL) was detected; serum creatinine was within normal limits. There was no hematuria.

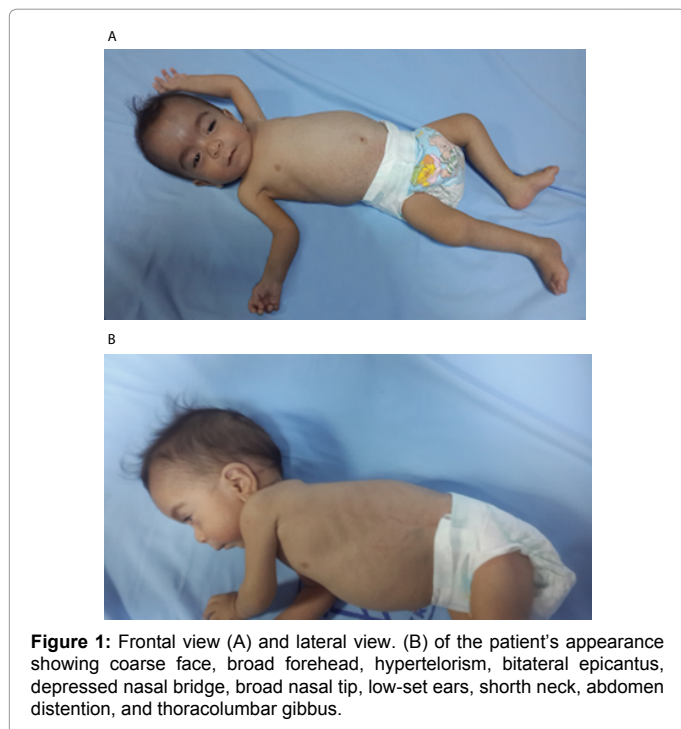Laboratory tests, including hemoglobin, electrolytes, blood

**\*Corresponding author:** Ercan Mihci, Pediatrician, Akdeniz University School of Medicine, Department of Pediatric Genetics, Antalya, Turkey, Tel:+90-242-249-6517; Fax:+90-242-227-4320; E-mail: [emihci@akdeniz.edu.tr](mailto:emihci@akdeniz.edu.tr)

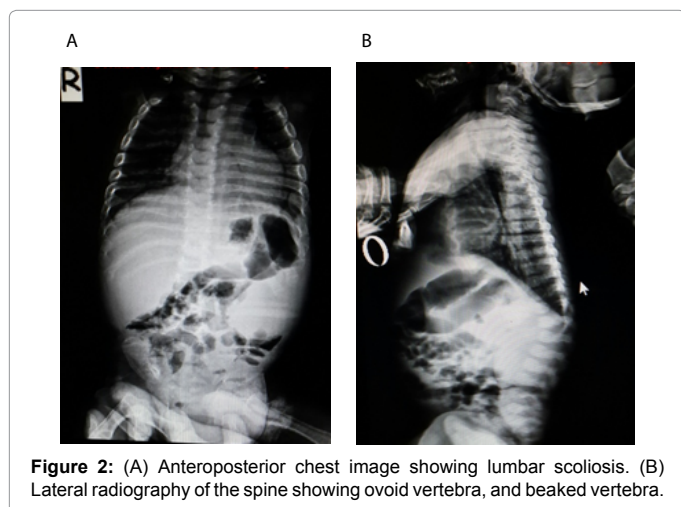
**Received** August 01, 2014; **Accepted** September 17, 2014; **Published** September 23, 2014

**Citation:** Nur BG, Aksoy GK, Koyun M, Akman S, Mihci E (2014) Early Infantile Galactosialidosis Presenting with an Unusual Renal Involvement. J Genet Syndr Gene Ther 5: 244. doi:10.4172/2157-7412.1000244

**Copyright:** © 2014 Nur BG, et al. This is an open-access article distributed under the terms of the Creative Commons Attribution License, which permits unrestricted use, distribution, and reproduction in any medium, provided the original author and source are credited.



**Figure 1:** Frontal view (A) and lateral view. (B) of the patient's appearance showing coarse face, broad forehead, hypertelorism, bilateral epicanthus, depressed nasal bridge, broad nasal tip, low-set ears, shorth neck, abdomen distention, and thoracolumbar gibbus.



**Figure 2:** (A) Anteroposterior chest image showing lumbar scoliosis. (B) Lateral radiography of the spine showing ovoid vertebra, and beaked vertebra.

urea nitrogen, creatinine, thyroid function tests, plasma and urine aminoacids, urine reducing substances, ammoniac, and lactate levels, were all found to be normal. The peripheral blood smear showed intracytoplasmic vacuolation of lymphocytes. Increased urinary oligosaccharides and sialic acid excretion was detected. We analyzed the activity of beta-galactosidase both in peripheral blood leucocytes and cultured skin fibroblasts. The low beta-galactosidase activities of 20.8  $\mu\text{mol/g/h}$  (normal values: 100-400  $\mu\text{mol/g/h}$ ) and 53.5  $\text{nmol/g/h}$  (normal controls: 476 and 503  $\text{nmol/g/h}$ ) were detected both in leucocytes and fibroblasts, respectively. The low neuraminidase activity 0.28  $\mu\text{mol/g/h}$  (affected control: 0.49  $\mu\text{mol/g/h}$ ; normal controls: 25 and 34  $\mu\text{mol/g/h}$ ) was detected in skin fibroblasts.

Furosemide and albumin infusions in addition to prednisone therapy (2  $\text{mg/kg/d}$ ) were given. After four-week treatment with prednisone, as massive proteinuria was continued, prednisone was stopped and ACE inhibitors were started. The presented patient was

diagnosed as steroid-resistant nephrotic syndrome due to massive proteinuria without clinical response after four weeks of prednisone treatment. Cyclosporine could not be started as he had severe infection. Renal biopsy was performed, a sclerotic and nonproliferative glomeruli was seen.

The patient was later admitted to our hospital because of pneumonia at 11 months of age. His psychomotor development was severe retarded especially concerning motor skills. He developed progressive hepatosplenomegaly, feeding difficulties, and hypoproteinemia. He died because of sepsis and heart failure shortly after then.

## Discussion

Early infantile galactosialidosis is the most severe form of this disease and is associated with premature mortality. It is not easy to diagnose in the infant period because of early death and necessary of urinary sialoligosaccharide excretion, and both enzyme activities of beta-galactosialidase and neuraminidase. However the age and presentation as a steroid-resistant nephrotic syndrome corresponds with the most common presentation of the infantile form of sialidosis (nephrosialidosis), including the absence of cherry-red spots or corneal clouding in early infancy, the present case is compatible to early infantile galactosialidosis with severe psychomotor delay, skeletal abnormalities, organomegaly, early death, and low beta-galactosidase and neuraminidase activities. In the present case, any ophthalmologic findings of galactosialidosis were detected. Although several cases of galactosialidosis reported with no eye abnormalities, galactosialidosis has been usually associated with various ocular anomalies, such as optic nerve atrophy, macular cherry-red spots, cloudy cornea, ocular albinism, and bilateral cataracts [7-9].

Protective protein cathepsin A, is a multifunctional enzyme, with deamidase, esterase and carboxypeptidase activities. In the lysosome, PPCA is essential for the stabilization of a multienzyme complex with lysosomal beta-galactosidase, sialidase/neuraminidase and galactosamino-6-sulfatase and for activation of neuraminidase. Deficiency of PPCA leads to secondary deficiency of beta-galactosidase and neuraminidase, and causes galactosialidosis. The distended lysosomes primarily contain accumulated sialylated glycoconjugate substrates of neuraminidase. Therefore, galactosialidosis is highly similar to sialidosis which caused by deficiency of neuraminidase [10]. Early and progressive nephrotic syndrome leading to end stage renal failure in the first years of life is one of the components of nephrosialidosis and related to the renal storage of undegraded sialyloligosaccharides [11,12]. Patients with GM1-gangliosidosis also can present extensive renal histological lesions, but impairment of renal function is not typically described. Kidney findings of galactosialidosis in autopsy material of early infantile and young/adult galactosialidosis have been reported [13-15]. These findings include swollen glomerular epithelial cells, tubular epithelial cells, glomerular endothelium, and renal blood vessels with many vacuoles, which are either empty or contain sparse tubular profiles. Proximal tubular epithelial cells contain PAS-positive storage material. Firstly, Sewell et al reported a 4 months old a infantile galactosialidosis patient with large kidneys [16]. Koike et al. described a 31 years old young/adult form of galactosialidosis Japanese patient with IgA nephropathy and normal renal function. They showed the electron microscopy findings of storage material in the kidney which have not been described till now [17]. Shortly after than Kiss et al reported a 9 years old Brazilian girl with galactosialidosis with severe nephrological symptomatology, which led to renal failure and renal transplantation. They hypothesized that end stage renal failure is not a typical finding in galactosialidosis

and end stage renal failure is secondary to the sialidosis component of the patient [18]. In the present patient, prednisone therapy were given. After four-week treatment with prednisone, as massive proteinuria was continued, prednisone was stopped and ACE inhibitors were started. The patient was diagnosed as steroid-resistant nephrotic syndrome due to massive proteinuria without clinical response after four weeks of prednisone treatment. Cyclosporine could not be started as the patient had severe infection. Renal biopsy was performed, a sclerotic and nonproliferative glomeruli was seen. We speculated that the accumulation of oligosaccharides in the in the organs and the urine may underlie the glomerular visceral epithelial cell dysfunction and proteinuria.

A rare reason of the nonimmun hydrops fetalis is lysosomal storage disorders [19]. In prenatal diagnosis of the lysosomal storage disorders the vacuolated lymphocytes present in the peripheral fetal blood smear may be the first clue to a lysosomal storage disease, but prenatal diagnosis of galactosialidosis is reliably possible by the investigation of the secondary deficiencies of beta-galactosidase and neuraminidase in amniocytes [9]. In the present patient, prenatal diagnosis could not be given to family because of normal fetal ultrasound and no history of recurrent hydropsfetalis.

In conclusion, there were a few cases with galactosialidosis, and only isolated cases of galactosialidosis with IgA nephropathy, renal insufficiency and renal transplantation reported in the literature. Presented case is particularly interesting because of its presentation with an unusual renal involvement. To our knowledge this is the first report of a galactosialidosis patient with steroid resistant nephrotic syndrome. When coarse facies, hepatosplenomegaly, dysostosis multiplex, and early neurological deterioration are detected in an infant, we should be considering galactosialidosis in the differential diagnosis. Also in order to not omit a possible diagnosis of galactosialidosis urinary sialoligo saccharide excretion and both enzyme activities of beta-galactosialidase and neuraminidase is necessary. Early diagnosis of this disease will allow for more effective treatment, genetic counseling and prenatal diagnosis in galactosialidosis.

## References

1. van der Spoel A, Bonten E, d'Azzo A (1998) Transport of human lysosomal neuraminidase to mature lysosomes requires protective protein/cathepsin A. *EMBO J* 17: 1588-1597.
2. d\_Azzo A, Andria G, Strisciuglio P, Galjaard H (2001) Galactosialidosis. In: *The Metabolic and Molecular Bases of Inherited Disease*. Scriver CR, Beaudet AL, Sly WS, Valle D (eds.), McGraw-Hill, New York: 3811-3826.
3. Darin N, Kyllerman M, Hård AL, Nordborg C, Månsson JE (2009) Juvenile galactosialidosis with attacks of neuropathic pain and absence of sialyloligosacchariduria. *Eur J PaediatrNeurol* 13: 553-555.
4. Lehman A, Mattman A, Sin D, Pare P, Zong Z, et al. (2012) Emphysema in an adult with galactosialidosis linked to a defect in primary elastic fiber assembly. *Mol Genet Metab* 106: 99-103.
5. Burgstein JM (2008) Nephrotic syndrome. In: *Nelson Textbook of Pediatrics* Behrman RE, Kliegman RM, Jenson HB (eds.), WB Saunders, Philadelphia: 2340-2342.
6. Eddy AA, Symons JM (2003) Nephrotic syndrome in childhood. *Lancet* 362: 629-639.
7. Okamura-Oho Y, Zhang S, Callahan JW (1994) The biochemistry and clinical features of galactosialidosis. *BiochimBiophysActa* 1225: 244-254.
8. Usui T, Takagi M, Abe H, Iwata K, Tsuji S, et al. (1991) Adult-form galactosialidosis: ocular findings in three cases. *Ophthalmologica* 203: 176-179.
9. Patel MS, Callahan JW, Zhang S, Chan AK, Unger S, et al. (1999) Early-infantile galactosialidosis: prenatal presentation and postnatal follow-up. *Am J Med Genet* 85: 38-47.
10. Lehman A, Mattman A, Sin D, Pare P, Zong Z, et al. (2012) Emphysema in an adult with galactosialidosis linked to a defect in primary elastic fiber assembly. *Mol Genet Metab* 106: 99-103.
11. Gubler MC (1998) Congenital nephrotic syndrome. In: *Inherited Disorders of the Kidney* Morgan SH, Grünfeld JP (eds) Oxford University Press, New York: 177-191.
12. Schiff M, Maire I, Bertrand Y, Cochat P, Guffon N (2005) Long-term follow-up of metachronous marrow-kidney transplantation in severe type II sialidosis: what does success mean? *Nephrol Dial Transplant* 20: 2563-2565.
13. Toyooka K, Fujimura H, Yoshikawa H, Taniike M, Inui K, et al. (1993) Nephrosialidosis: ultrastructural and lectin histochemical study. *Acta Neuropathol* 86: 198-205.
14. Nordborg C, Kyllerman M, Conradi N, Månsson JE (1997) Early-infantile galactosialidosis with multiple brain infarctions: morphological, neuropathological and neurochemical findings. *Acta Neuropathol* 93: 24-33.
15. Oyanagi K, Ohama E, Miyashita K, Yoshino H, Miyatake T, et al. (1991) Galactosialidosis: neuropathological findings in a case of the late-infantile type. *Acta Neuropathol* 82: 331-339.
16. Sewell AC, Pontz BF, Weitzel D, Humburg C (1987) Clinical heterogeneity in infantile galactosialidosis. *Eur J Pediatr* 146: 528-531.
17. Koike K, Hamaguchi T, Kitamura H, Imasawa T, Joh K (2008) Galactosialidosis associated with IgA nephropathy: morphological study of renal biopsy. *PatholInt* 58: 295-299.
18. Kiss A, Zen PR, Bittencourt V, Paskulin GA, Giugliani R, et al. (2008) A Brazilian galactosialidosis patient given renal transplantation: a case report. *J Inher Metab Dis* 31 Suppl 2: S205-208.
19. Stone DL, Sidransky E (1999) Hydropsfetalis: lysosomal storage disorders in extremis. *Adv Pediatr* 46: 409-440.