

Double Layer Continuous Intradermal Sutures in Keloid Operation

Youbin Wang* and Xiao Long

Plastic Surgery Department, Peking Union Medical College Hospital, Peking, China

Abstract

Objective: Keloid often occurs on chest wall, shoulder and back. Surgical incision and postoperative radiation is an effective method in keloid treatment. Many of the wound in these places can be directly closed after keloids being removed. Recurrence prevention and cosmetic result should all be considered. Operation method especially suture method is one of the key issues which determine the treatment result. Many methods have been developed. However, many of them are designated to prevent recurrence. Cosmetic result is not fully considered. In this article, we reported a new suture method which is with good treatment and cosmetic results in our clinical study.

Methods: One hundred and thirty-three patients with chest keloids were treated from 2006 to 2011. Double layer continuous intradermal suture was used in fifty four patients, interrupted epidermal suture was used in forty one patients, and one layer continuous intradermal suture was used in thirty eight patients. All operation sites were treated with radiotherapy on the first and seventh postoperative day. The follow-up time was from 9 to 26 months. The recurrence rate and cosmetic satisfactory rate was recorded. Data was analyzed with SPSS17.0 software. Recurrence and satisfactory rate were compared with Chi-square test between double layer and interrupted suture, double layer and one layer suture.

Results: There were no difference in recurrence rate between double layer and interrupted suture ($X^2=2.46$, $P>0.05$) or double layer and one layer suture ($X^2=0.16$, $P>0.05$). Satisfactory cosmetic rates were 72.22%, 29.27% and 39.47% in double layer continuous intradermal suture group, interrupted suture group and one layer continuous intradermal suture group. Difference in satisfactory cosmetic rates is obvious between double layer and interrupted suture ($X^2=9.30$, $P<0.01$) or double layer and one layer suture ($X^2=9.05$, $P<0.01$).

Conclusion: Double layer continuous intradermal suture can reach good treatment results and more satisfactory cosmetic results in keloid operation.

Keywords: Double layer continuous intradermal suture; Keloid operation; Interrupted suture; Continuous intradermal suture

Introduction

Keloid is benign fibrous growths that usually occur in chest wall, shoulder, back and mandible. It may be induced by acne, folliculitis, insect bites or other skin injuries such as surgery, lacerations and abrasion [1]. Keloid is often difficult to treat. The reported therapy methods include excision, irradiation, steroid injection, and pressure therapy with silicone gel sheets or bandages [2,3]. Surgical methods especially wound closure methods are very important in recurrence prevention. Many suture methods were reported in literature. Cosmetic result is another issue to be considered in keloid treatment [4]. Cosmetic outcome is as important as recurrence prevention. Based on the principle of recurrence prevention and cosmetic consideration, we used double layer continuous intradermal suture besides basic surgery techniques in keloid operation and compared it with interrupted suture and one layer continuous intradermal suture. This study has been approved by the ethical review board of Peking Union Medical College Hospital. Informed consent has been signed by all the patients before operation.

Methods

Patient group

One hundred and thirty-three patients with chest keloids were treated with in our department from 2006 to 2011. The patients were divided into three groups randomly based on the month at which the operation was carried out. Patients whose operations were carried out in January, April, July and October were the double layer continuous intradermal suture group. Patients whose operations were carried out in February, May, August and September were the conventional

interrupted epidermal suture. Patients whose operations were carried out in other months were the one layer continuous intradermal suture. There were fifty four patients in the double layer continuous intradermal suture group. The average age of these is 24.6 years old. All of the keloids were in the front chest wall. The average size of the keloid was 4.2 cm×2.8 cm. Five of the keloids occurred after local operation. Twenty eight were after folliculitis. No specific reason could be traced out in other patients. Fifteen of the patients received steroid injection but failed. No previous treatment was used in other patients. There were forty one patients in interrupted epidermal suture group. The average age of these is 21.3 years old. All of the keloids were in the front chest wall. The average size of the keloid was 3.8 cm×2.4 cm. Three of the keloids occurred after local operation. Twenty six were after folliculitis. No specific reason could be traced out in other patients. Nine of the patients received steroid injection but failed. No previous treatment was used in other patients. There were thirty eight patients in one layer continuous intradermal suture group. The average age of these patients was 25.3 years old. All of the keloids were in the front chest wall. The average size of the keloid was 5.1 cm×2.6 cm. Three of the keloids occurred after local operation. Twenty three were after folliculitis.

***Corresponding author:** Youbin Wang, Peking Union Medical College Hospital, Beijing 100032, PR China, Tel: (86)1069152711; Fax: (86)1069152713; E-mail: wuybenz@aliyun.com

Received December 24, 2013; **Accepted** January 20, 2014; **Published** January 26, 2014

Citation: Wang Y, Long X (2014) Double Layer Continuous Intradermal Sutures in Keloid Operation. J Clin Exp Dermatol Res 5: 205. doi:10.4172/2155-9554.1000205

Copyright: © 2014 Wang Y, et al. This is an open-access article distributed under the terms of the Creative Commons Attribution License, which permits unrestricted use, distribution, and reproduction in any medium, provided the original author and source are credited.

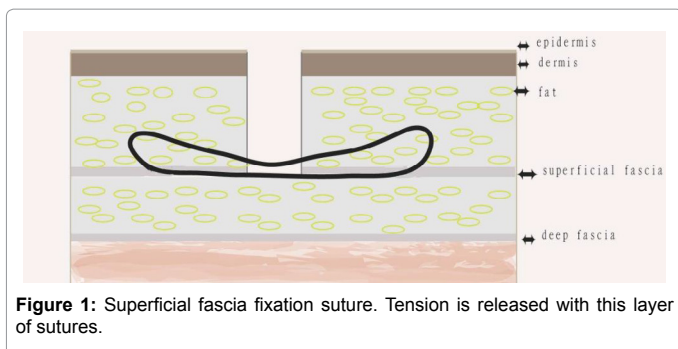


Figure 1: Superficial fascia fixation suture. Tension is released with this layer of sutures.

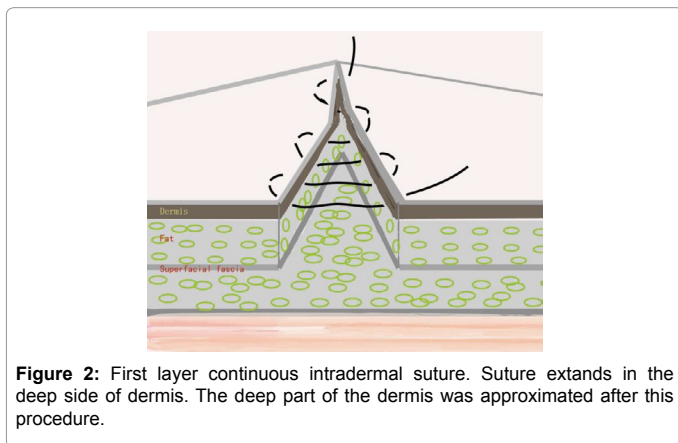


Figure 2: First layer continuous intradermal suture. Suture extends in the deep side of dermis. The deep part of the dermis was approximated after this procedure.

No specific reason could be traced out in other patients. Eight of the patients received steroid injection but failed. No previous treatment was used in other patients. The follow-up time was from 9 to 26 months. The recurrence rate and cosmetic satisfactory rate was recorded and compared.

Surgical technique

The edge of the keloid was marked with gentian violet. 0.5% lidocaine was used for local infiltration anesthesia in skin around the keloid. A full-thickness incision was made along the mark and the keloid was removed. After hemostasia, skin 3-5cm around the incision border was undermined at the deep layer of superficial fascia. As for wound closing and tension releasing, one layer of superficial fascia stitches was put with normal silk thread. This layer of stitch was fixation suture. The thread should tolerate skin tension and keep the superficial fascia part contact. In order to maintain the fixed wound elevated, we usually put the stitch at the superficial fascia layer 1-2 cm away from the wound edge (Figure1). More suture stitches would increase foreign body reaction and scar formation. We avoid this side effect by using few stitches with best tension releasing effect. After the wound being fixed and the tension being released, the first layer of continuous intradermal suture was put. 3-0 monofilament nylon thread was used. The suture began from one end of the wound, extended at the deep side of skin dermis, ended on the other end of the wound (Figure 2). Each end of the thread was fixed on the skin with a piece of silicone tube. The deep side of skin dermis was approximated after this procedure. But the superficial side of the dermis and the epidermis usually remained little apart from one another. Another layer of suture was need. This layer of continuous intradermal suture was put on the superficial side of the skin dermis, just under the layer of epidermis (Figure 3). 3-0 monofilament nylon thread was used in this layer. The suture also

began from one end of the wound, ended on the other end of the wound and each end was fixed on the skin with a piece of silicone tube. The epidermis was then well approximated. The wound was then fixed with strips and covered with sterile gauze. Radiation therapy was taken one and seven days after operation. Sutures can be removed easily 14 to 21 days after operation.

Deep layer fixation method was the same in interrupted suture and one layer continuous intradermal suture method surgery. After the wound being fixed and the tension being released, the wound would be closed with interrupted suture or one layer continuous intradermal suture. The patients received the same auxiliary treatment.

Radiotherapy methods

Radiotherapy was applied at the operation sites on the first and seventh postoperative day. Every operation site received 900 cGy electron beam irradiation each time [3].

Evaluation after therapy

The scar at the operation site was evaluated during the follow-up period. The scar was rated using the following guidelines: Ordinary scar: The scar is flat, pale in color, and it is in the range of the operation incision; the patient may experience an occasional tickle at the site of the scar. Recurred keloid scar: The scar is protuberant, red or purplish red in color, and it exceeds the range of the operation incision; the patient often experiences serious itching and aching. The keloid therapy results were graded as follows: cured, an ordinary scar at the operation site; recurrence, a keloid scar in a part or the entirety of the operation site.

The patients' aesthetic satisfaction was also recorded and evaluated. The aesthetic results were graded as good, acceptable, or poor.

Data analysis methods

Data was analyzed with SPSS17.0 software. Recurrence and satisfactory rate were compared with Chi-square test between double layer and interrupted suture, double layer and one layer suture.

Results

Two recurrences were observed during follow-up time in patients treated with double layer continuous intradermal suture. The recurrence rate was 3.70%. Recurrence rate was 12.19% (5/41) and 7.89% (3/38) in patients treated with interrupted and one layer continuous intradermal suture. Satisfactory cosmetic rates (graded as good and acceptable) were 72.22% (37/54) in double layer continuous intradermal suture group, 29.27% (12/41) in interrupted suture group and 39.47% (15/38) in one

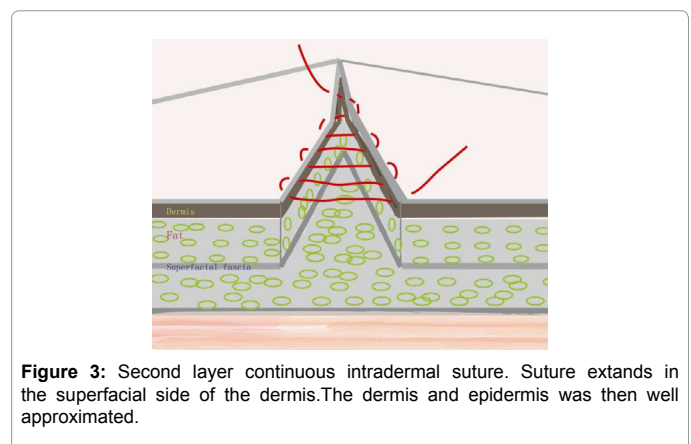


Figure 3: Second layer continuous intradermal suture. Suture extends in the superficial side of the dermis. The dermis and epidermis was then well approximated.

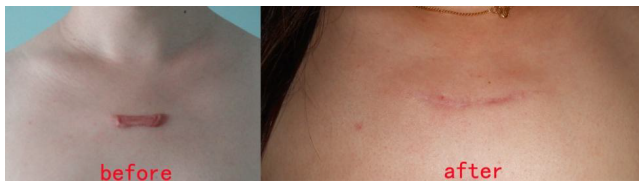

Figure 4: Chest keloid treated with double layer continuous intradermal suture. Before and twenty six months after operation. The scar was thin.

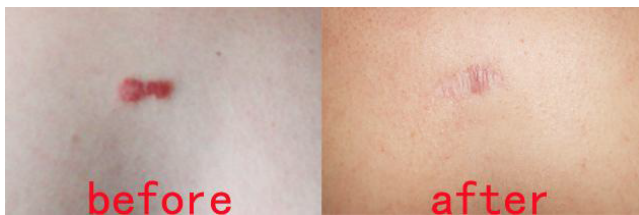

Figure 5: Chest keloid treated with interrupted suture. Before and twenty three months after operation. Suture mark was still obvious.

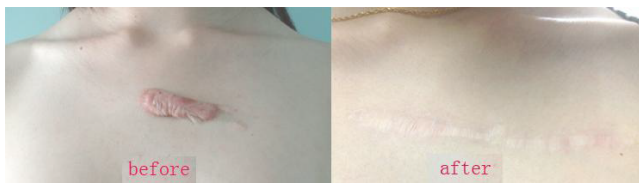

Figure 6: Chest keloid treated with one layer continuous intradermal suture. Before and eighteen months after operation. The scar was pale but wide.

layer continuous intradermal suture group. There were no difference in recurrence rate between double layer and interrupted suture ($X^2=2.46$, $P>0.05$) or double layer and one layer suture ($X^2=0.16$, $P>0.05$). There were difference in satisfactory cosmetic rates between double layer and interrupted suture ($X^2=9.30$, $P<0.01$) or double layer and one layer suture ($X^2=9.05$, $P<0.01$) (Figure 4). Obvious suture marks was observed in the patients treated with interrupted epidermal suture (Figure 5). Wider scar was observed in patients treated with interrupted epidermal suture and one layer continuous intradermal suture (Figure 6).

Discussion

Tension releasing is one of the important procedures in keloid recurrence prevention. To release natural skin tension after wound closure, many suture methods were recommended. Hyakusoku used three-layer suture in the subdermal, dermal, and epidermal layer [5]. They used skin adhesive and buried running sutures in epidermal layer closure to prevent suture marks after subdermal and dermal suture which keep the wound edge elevated. In Ogawa's report, they emphasized the importance of subcutaneous/fascia tensile reduction suture [4]. They usually put some sutures in deep fascia layer. The superficial fascia layer is also closed. These wound closure methods are effective and important in keloid recurrence prevention. But the importance of dermal layer closure is not emphasized.

Traditional closure methods of the dermis described in literatures are interrupted intradermal suture with interrupted epidermal suture or epidermal buried running suture [6]. Aim of such suture is wound approximation and tension reduction. The suture thread is usually

left in skin tissue. Thread knots leaved in tissue can induce foreign body reaction and scar formation. Salamon et al observed the tissue reaction to suture thread histologically. They found that connective tissue capsule is formed around threads which are not absorbed. The histological reaction is the most intense around the traditional linen thread which leads to cicatrization [7]. Prolonged foreign body reaction can induce keloids and foreign body granuloma [8,9]. Absorbable suture are sometimes used in such circumstance, but the possibilities of wide scars or wound failure need to be considered. If the strength can not resist wound-shearing forces before the scar gain sufficient strength, wide scars or wound failure may occur as reported by Nordström [10].

Great care has been taken to prevent recurrence in keloid treatment in our department. Many methods and principles were considered in surgical procedure and postoperative treatment. These include wound tension reduction, postoperative radiation, micro-trauma surgical procedure, less postoperative inflammation reaction. Design of double layer continuous intradermal suture is based on these principles. Besides superficial fascia tension reduction suture, wound tension was further reduced by the deep layer continuous intradermal suture. On the other hand, this layer of suture can be removed easily 14-21 days after operation. No suture thread is left in the dermal layer later on. Foreign body reaction induced inflammation is then prevented. Combined with postoperative radiation, recurrence rate is great reduced.

Satisfactory cosmetic outcome is also reached with this design. With the superficial layer continuous intradermal suture, the wound edge is well approximated. Healing process of the epidermis was enhanced. Suture mark was avoided and scar is less obvious after operation than traditional suture methods.

In conclusion, dermal and epidermal layers of the wound are all well approximated after the keloid being removed when it is closed with double layer continuous intradermal suture. Good treatment and more satisfactory cosmetic results are reached.

References

- Scramali L, Lomeo G, Nolfo C, Pompili G, Tamburino S, et al. (2010) Treatment of hypertrophic scars and keloids with a fractional CO₂ laser: a personal experience. J Cosmet Laser Ther 12: 218-221.
- Shockman S, Paghdal KV, Cohen G (2010) Medical and surgical management of keloids: a review. J Drugs Dermatol 9:1249-1257.
- Qi Z, Liang W, Wang Y, Long X, Sun X, et al. (2012) "X"-shaped incision and keloid skin-flap resurfacing: a new surgical method for auricle keloid excision and reconstruction. Dermatol Surg 38: 1378-1382.
- Ogawa R, Akaishi S, Chenyu H, Dohi T, Aoki M, et al. (2011) Clinical applications of basic research that shows reducing skin tension could prevent and treat abnormal scarring: the importance of fascial/subcutaneous tensile reduction sutures and flap surgery for keloid and hypertrophic scar reconstruction. J Nippon Med Sch. 78: 68-76.
- Hyakusoku H, Ogawa R (2004) A new skin closure technique with running sutures and tissue adhesive. Plast Reconstr Surg 113: 1526-1527.
- Krunick AL, Weitzel S, Taylor S (2005) Running Combined simple and vertical mattress suture: a rapid skin-everting stitch. Dermatol Surg 31:1325-1329.
- Salamon A, Kádas L, Sarang I, Vidó S, Ihász M, et al. (1980) [Histological reactions caused by various types of suturing threads]. Acta Chir Acad Sci Hung 21: 31-42.
- Choudhary SV, Khairkar P, Singh A, Gupta S (2009) Dermatitis artefacta: keloids and foreign body granuloma due to overvalued ideation of acupuncture. Indian J Dermatol Venereol Leprol 75: 606-608.
- Ogawa R (2010) The most current algorithms for the treatment and prevention of hypertrophic scars and keloids. Plast Reconstr Surg 125: 557-568.
- Nordström RE, Nordström RM (1986) Absorbable versus nonabsorbable sutures to prevent postoperative stretching of wound area. Plast Reconstr Surg 78: 186-190.