

Discrete and Coalescing Pustules Masking Severe Recalcitrant Rosacea due to *Demodex*

Chase Wilson¹, Stefanie Ali², Nico Mousdicas¹ and Megan Brinkworth^{1*}

¹Department of Dermatology at Indiana University School of Medicine, Indianapolis

²Department of Pathology and Laboratory Medicine at Indiana University School of Medicine, Indianapolis, Indiana

*Corresponding author: Megan Brinkworth, Indiana University School of Medicine, United states, Tel: 502-299-5224; E-mail: mbrinkwo@indiana.edu

Received date: Aug 03, 2015; Accepted date: Aug 27, 2015; Published date: Aug 31, 2015

Copyright: © 2014 Wilson C, et al. This is an open-access article distributed under the terms of the Creative Commons Attribution License, which permits unrestricted use, distribution, and reproduction in any medium, provided the original author and source are credited.

Abstract

We describe a clinical case concerning a 36 year old man with a recalcitrant dermatosis involving the face and neck to demonstrate how multiple pathogenic mechanisms may ultimately prohibit disease resolution. This patient's disease persisted despite multiple standard treatments for the leading differential diagnoses early in the disease course including: topical/systemic corticosteroids for an initially suspected facial dermatitis followed by minocycline and oral ivermectin for granulomatous rosacea with high *Demodex* burden. These failed therapies prompted the use of oral prednisone and topical pimecrolimus that resulted in some improvement but worsening flares if therapy was discontinued. The leading differential shifted toward rosacea fulminans or an unusual manifestation of immune reconstitution inflammatory syndrome (IRIS) in the setting of possible HIV or iatrogenic immunosuppression. An extensive diagnostic workup was completed and showed isolated IgM deficiency (49 mg/dl, normal range 60 to 300 mg/dl), low levels of 25 hydroxyvitamin D (15 pg/mL, normal range 18 to 64 pg/mL), and low ascorbic acid (0.3 mg/dl, normal range 0.6 to 2.0 mg/dl). The rash finally resolved following a tapering course of cyclosporine and vitamin repletion through supplements and dietary alteration. Our case is one with multiple confounding variables that may have contributed to the recalcitrant nature of this dermatosis: (1) presence of *Demodex*; (2) iatrogenic immunosuppression due to prolonged systemic and topical steroid use; and (3) vitamin deficiency. It is unclear exactly what role each of these factors played but the purpose of our case is to illustrate these variables can be encountered in regular practice and that sometimes the physician must explore and correct all potential vectors of pathogenesis in order to successfully treat recalcitrant dermatoses.

Keywords: Rosacea; *Demodex*; Vitamin deficiency

Case Report

Our patient is a 36-year-old otherwise healthy male referred to Indiana University (IU) Department of Dermatology for an 8-month history of a recalcitrant dermatosis involving the face and neck.

He was initially treated for 5 months by his primary care physician for a facial dermatitis of unknown etiology with multiple courses of steroids including: 5 courses of oral prednisone, 2 cortisone intramuscular injections, and a 3-week course of a topical steroid. The rash failed to improve, and he was referred to an outside dermatologist who initially treated him for rosacea with a month of minocycline and azelaic acid in March 2013. At one-month follow up, a skin biopsy was performed and a thorough rheumatologic work up completed to rule out systemic lupus; Metronidazole 1% gel was added to his regimen. Antinuclear antibody (ANA), Anti-Sm antibody, Anti-Scl-70, Anti-SS-A/SS-B, and erythrocyte sedimentation rate (ESR) were all within normal limits; skin biopsy showed spongiosis with a chronic perivascular dermal inflammatory infiltrate. At his May 2013 visit, patch testing revealed reactions to bacitracin and neomycin but these were not believed to be relevant to the current dermatitis. Therapy with topical pimecrolimus 1% cream and a single injection of intramuscular triamcinolone were initiated and he was then referred to IU for further evaluation and more extensive patch testing.

At his initial visit with IU Dermatology on July 29, 2013, he was noted to have an edematous and erythematous scaling papular

eruption on his face that extended to both sides of the neck including Wilkinson's triangle, but sparing the nose (Figure 1). With this distribution, airborne contact dermatitis was initially entertained but patch testing with North American and fragrance series was negative.

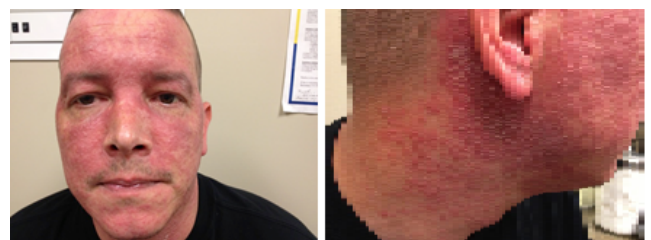

Figure 1: Erythematous and edematous face and neck consistent of discrete and coalescing papules and pustules.

On July 3 he returned with a more extensive and increasingly erythematous rash studded with numerous pustules that raised suspicion for steroid induced rosacea due to discontinuation of the oral steroid 10 days prior. A pustule on the neck was scraped and revealed numerous *Demodex* organisms on microscopy (Figure 2). Therapy was initiated with oral ivermectin 15 mg on day 1 and 7 and doxycycline 100 mg daily. Over the next 3 months, the patient returned to clinic on multiple occasions for persistent and at times

worsening inflammation. Eventually, he was given a 3-month course of prednisone with slow taper and isotretinoin 30 mg daily.

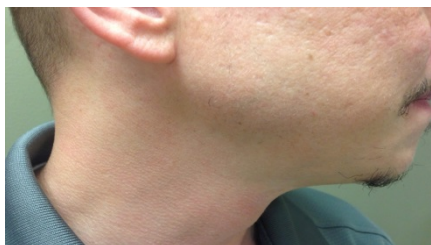


Figure 2: High power view of 10 *Demodex* mites on skin scraping.

On November one day after completion of prednisone, the patient flared. At this point, there were growing concerns for rosacea fulminans or an unusual manifestation of immune reconstitution inflammatory syndrome (IRIS) in the setting of possible HIV or iatrogenic immunosuppression. An extensive diagnostic workup was completed and included a second skin scraping that again demonstrated *Demodex* organisms (Figure 2). Laboratory results showed isolated IgM deficiency (49 mg/dl, normal range 60 to 300 mg/dl), low levels of cholecalciferol (15 pg/mL, normal range 18 to 64 pg/mL), and low ascorbic acid (0.3 mg/dl, normal range 0.6 to 2.0 mg/dl). Zinc, HIV, *H. pylori*, TSH, IgA, and IgG were within normal limits. Biopsies taken from the left upper chest demonstrated subtle spongiosis with focal granulomatous perifolliculitis, consistent with granulomatous rosacea. A cyclosporine 50 mg taper (five day intervals starting with thrice daily then twice daily, and finishing with approximately 2 weeks of daily medication) and Ivermectin 3 mg daily for 3 weeks was initiated along with ascorbic acid 500 mg and cholecalciferol 1000 units daily to assist with vitamin repletion. After 4 weeks of therapy, the patient had significant improvement on physical exam showing only small residual patches of erythema involving glabella, eyebrows, and bilateral cheeks. IgM levels returned to normal. Cyclosporin was tapered to 50 mg every other day for four doses then every third day for three doses and ivermectin was discontinued. He continued with vitamin supplementation daily and dietary changes, including daily intake of green smoothies, and at his 6 month follow up his skin was clear without any evidence of inflammation (Figure 3).




Figure 3: Resolution of recalcitrant dermatosis following, *Demodex* treatment, tapering of immunosuppressives, and nutritional supplementation.

Discussion

The clinical manifestations of rosacea are hypothesized to be the result of a dysregulation of the innate immune system that begins with increased toll like receptor 2 (TLR2) expression [1]. TLR2 stimulates production of kallikrein 5, a serine protease that abnormally processes the antimicrobial peptide cathelicidin into a larger molecular weight form compared to that of normal epidermis. This abnormal form, LL-37, contributes to the inflammation and flushing seen in rosacea by increasing leukocyte chemotaxis and angiogenesis [2]. Additionally, it has a lower antimicrobial power compared to normally processed molecules [3].

Demodex folliculorum and *Demodex brevis* are two mite species known to be obligatory parasites found in hair follicles and pilosebaceous glands, particularly concentrated on the scalp, face, and upper chest. A higher concentration of mites are found in the skin of patients with papulopustular rosacea (PPR) and it has been hypothesized that *Demodex* may contribute to its pathogenesis. One proposed mechanism is that *Demodex* infection is due to an initial immune defect, innate or acquired, that allows for organism proliferation. After months to years, the mites induce epithelial barrier disruption and via chitin activate TLR2 which enhances proteolytic cleavage of cathelicidins into the LL-37 form contributing to the pathogenesis of rosacea [3,4].

Now the question arises, what allowed for proliferation of *Demodex* mites in an otherwise young, healthy individual? The highest rate of *Demodex* infestation occurs in the second and third decade of life, likely due to increased sebum secretion, but it is an underlying immune suppression, either primary or acquired, that allows for the development of clinical disease [5]. In our patient, multiple courses of steroids were used to treat his initial condition, which likely played a role in immunosuppression. Additionally, his extremely recalcitrant presentation elicited a comprehensive laboratory work up that revealed deficiency in vitamin C and vitamin D both of which have well documented roles in skin integrity and the immune response.

For innate immunity, vitamin D has an anti-inflammatory and antimicrobial role via up-regulation of cathelicidins. Cathelicidins are expressed in high amounts in barrier tissues and, through multiple immune mechanisms, cause a reduction in skin inflammation, vascular response, and secondary skin infections [6,7]. However, patients deficient in vitamin D, specifically calcifediol levels below 20 ng/dl, may be unable to fully express cathelicidins making them increasingly susceptible to infection secondary to barrier dysfunction [8]. Vitamin C is well known for its role in maintaining skin integrity and wound healing. Together these two deficiencies may have permitted the proliferation and barrier penetration of *Demodex* resulting in an inflammatory process recalcitrant to the established treatment protocols. As for adaptive immunity, vitamin D affects T-helper cell balance by inhibition of Th1 response while vitamin C increases the production of IgM [9,10]. It is uncertain what role the diminished IgM levels played in our patient but vitamin deficiency may have contributed to his low level.

Our case has multiple confounding variables, including: (1) presence of *Demodex*; (2) iatrogenic immunosuppression due to prolonged systemic and topical steroid use; and (3) vitamin deficiency. It is unclear exactly what role each of these factors played in our patient's condition. Of greater importance is that these conditions can be commonly encountered in practice and should be individually investigated in cases of recalcitrant dermatoses.

It is important to note, the prevalence of *Demodex* induced clinical disease is not rare in dermatology practice; however, it is often overlooked and under diagnosed. Forton et al. [11] found an average of 2.4 demodicoses were diagnosed per week in their observed dermatology practices but the diagnosis varied greatly depending on the physician and familiarity with the condition.

Secondly, iatrogenic immunosuppression can arise in dermatology with the use of topical, injectable, or oral steroids and calcineurin inhibitors. IRIS most commonly follows immune recovery in HIV patients after starting highly active antiretroviral therapy; however, it can be seen in HIV-negative patients and has been documented in various case reports of pregnancy, stem cell and solid organ transplant recipients, and neutropenic patients [12]. In our case, the patient was treated with multiple courses of immunosuppressants and with each taper the eruption flared suggesting this observation may have represented a type of immune reconstitution reaction.

Lastly, vitamin deficiencies are not uncommon in the United States. Approximately 7.1% of the population was vitamin deficient in the 2003-2004 National Health and Nutrition Examination Survey. The highest concentrations of deficient individuals were men aged 20-59 with low socioeconomic status and positive smoking history [13]. For vitamin D, Jeng et al. [8] found 66.5% of their healthy controls to have insufficient levels. Of note, our patient was of high socioeconomic status reiterating the point it is important to consider deficiency in any demographic.

In conclusion, all pathogenic mechanisms must be explored and addressed in cases of recalcitrant dermatoses; we highlight that nutritional deficiencies, despite their controversy, may have significant effects on the immune system and skin integrity thus complicating cutaneous disease. For this patient, it was not enough to simply increase the complexity of pharmacologic therapy; complete resolution without relapse was only achieved with eradication of *Demodex*, slow tapering of immunosuppressants, and vitamin repletion.

Learning Points

1. *Demodex* overgrowth should be evaluated for and treated in cases of recalcitrant rosacea as it is a relatively common confounding but reversible factor in rosacea pathogenesis.
2. Physicians should be aware that flares of cutaneous disease may be iatrogenic and result from improper tapering of topical or systemic immunosuppressive therapy.
3. Dermatologist should consider underlying nutrition deficiencies, regardless of patient demographics, as they may adversely affect skin barrier function and alter its immune response.

4. An integrative approach to medicine that is mindful of a patient's lifestyle encourages one to think beyond the skin as a cause of underlying disease and empowers patients to make lifestyle changes to better their overall health.

References

1. Yamasaki K, Kanada K, Macleod DT, Borkowski AW, Morizane S, et al. (2011) TLR2 expression is increased in rosacea and stimulates enhanced serine protease production by keratinocytes. J Invest Dermatol 131: 688-697.
2. Yamasaki K, Di Nardo A, Bardan A, Murakami M, Ohtake T, et al. (2007) Increased serine protease activity and cathelicidin promotes skin inflammation in rosacea. Nat Med 13: 975-980.
3. Forton FM (2012) Papulopustular rosacea, skin immunity and *Demodex*: pityriasis folliculorum as a missing link. J Eur Acad Dermatol Venereol 26: 19-28.
4. Da Silva CA, Hartl D, Liu W, Lee CG, Elias JA (2008) TLR-2 and IL-17A in chitin-induced macrophage activation and acute inflammation. J Immunol 181: 4279-4286.
5. Rather PA, Hassan I (2014) Human demodex mite: the versatile mite of dermatological importance. Indian J Dermatol 59: 60-66.
6. Schaubert J, Gallo RL (2008) The vitamin D pathway: a new target for control of the skin's immune response? Exp Dermatol 17: 633-639.
7. Youssef DA, Miller CW, El-Abbassi AM, Cutchins DC, Cutchins C, et al. (2011) Antimicrobial implications of vitamin D. Dermatoendocrinol 3: 220-229.
8. Jeng L, Yamshchikov AV, Judd SE, Blumberg HM, Martin GS, et al. (2009) Alterations in vitamin D status and anti-microbial peptide levels in patients in the intensive care unit with sepsis. J Transl Med 7: 28.
9. Boonstra A, Barrat FJ, Crain C, Heath VL, Savelkoul HF, et al. (2001) 1alpha,25-Dihydroxyvitamin d3 has a direct effect on naive CD4(+) T cells to enhance the development of Th2 cells. J Immunol 167: 4974-4980.
10. Prinz W, Bloch J, Gilich G, Mitchell G (1980) A systematic study of the effect of vitamin C supplementation on the humoral immune response in ascorbate-dependent mammals. I. The antibody response to sheep red blood cells (a T-dependent antigen) in guinea pigs. Int J Vitam Nutr Res 50: 294-300.
11. Forton F, Germaux MA, Brasseur T, De Liever A, Laporte M, et al. (2005) Demodicosis and rosacea: epidemiology and significance in daily dermatologic practice. J Am Acad Dermatol 52: 74-87.
12. Scharschmidt TC, Amerson EH, Rosenberg OS, Jacobs RA, McCalmont TH, et al. (2013) Immune reconstitution reactions in human immunodeficiency virus-negative patients: report of a case and review of the literature. JAMA Dermatol 149: 74-78.
13. Schleicher RL, Carroll MD, Ford ES, Lacher DA (2009) Serum vitamin C and the prevalence of vitamin C deficiency in the United States: 2003-2004 National Health and Nutrition Examination Survey (NHANES). Am J Clin Nutr 90: 1252-1263.