

Demystifying Tibial-Tuberosity Trochlear Groove Distance, the J-Sign and Trochlear Dysplasia: An Imaging Encomium

GL Meena*, Md Khizer Razak and Surbhi Gupta

Sardar Patel Medical College, Radiodiagnosis & Nuclear Medicine, Bikaner, Rajasthan, India

*Corresponding author: GL Meena, Senior Professor & HOD, Consultant Incharge Nuclear Medicine, Sardar Patel Medical College, Radiodiagnosis & Nuclear Medicine, Iii/3, Medical Boys Hostel Campus, S.P. Medical Boys Hostel Campus, Bkaner, Rajasthan-334003, India, Tel: +919413143709, E-mail: meenabkn@yahoo.co.in

Received date: July 24, 2017; Accepted date: August 17, 2017; Published date: August 25, 2017

Copyright: © 2017 Meena GL, et al. This is an open-access article distributed under the terms of the Creative Commons Attribution License, which permits unrestricted use, distribution, and reproduction in any medium, provided the original author and source are credited.

Abstract

Aims and objective: The purpose of our study was to examine the association of the clinical J-sign with trochlear dysplasia and TTTG distance in patients with symptomatic patellofemoral instability.

Material and methods: After obtaining approval from the institutional review board (class: 8.1-16/47-2, Nr.: 02/21AG, April 11, 2017), in our retrospective cross-sectional review study, 2 raters mutually assessed the type of trochlear dysplasia and separately measured the TTTG distance at 4-week intervals using 2 methods (standard and by Nizi#) on static and dynamic CT-images of 55 knees (46 patients) with clinical record of J-sign and anterior knee pain.

Statistical analysis: All reported P values were 2-tailed with a level of <0.05 indicating statistical significance. The associations between variables were analyzed with appropriate correlation coefficients (Pearson, rp, point-biserial, rpb, and phi, r#). The Wilcoxon signed-rank test for paired samples was used to evaluate the differences between static and dynamic tibial tuberosity-trochlear groove.

Conclusion: The clinical manifestation of the J-sign, considered a dynamic marker of patellofemoral instability, has been frequently associated with numerous conditions, such as trochlear dysplasia, higher values of the Q-angle, and lateralized tibial tuberosity, yet its fundamental cause remains unknown, and the diagnostic value uncertain.

Keywords: J sign; Trochlea; Dysplasia; (TTTG) Tibial tuberosity trochlear groove

Introduction

A severe lateral subluxation of the patella at active terminal extension of the knee is called the J-sign [1,2] or J-tracking [3]. It is a straight forward clinical sign, sometimes shortly referred to as "dislocation in extension" [4]. A positive J-sign might suggest patellar maltracking [5], and potentially a need for trochleoplasty [6]. Yet, the underlying anatomical features and its actual diagnostic value are somewhat cryptic [7]. On the contrary, both trochlear dysplasia and the tibial tuberosity-trochlear groove (TTTG) distance, as a measure of lateralization of the extensor mechanism of the knee, are well-known phenomena with regard to recurrent patellofemoral instability [6].

In skeletally mature patients, the anterior knee pain and the value of the TTTG distance #20 mm could imply surgical treatment [8], namely medialization of the tibial tuberosity [6]. The purpose of our study was to examine the association of the clinical J-sign with trochlear dysplasia and TTTG distance in patients with symptomatic patellofemoral instability. After obtaining approval from the institutional review board in 2017, in our retrospective cross-sectional review study (Figure 1), 2 raters mutually assessed the type of trochlear dysplasia (Figure 2) and separately measured the TTTG distance at 4-week intervals using 2 methods (standard [9] and by Nizi# [10])

(Figure 3 and 4) on static and dynamic CT-images of 55 knees (46 patients) with clinical record of J-sign and anterior knee pain [11].

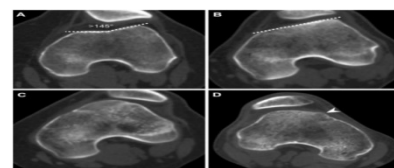


Figure 1: Dejour's classification of trochlear dysplasia. Type A (A), B (B), C (C) and D (D); cliff

All reported P values were 2-tailed with a level of <0.05 indicating statistical significance. The associations between variables were analyzed with appropriate correlation coefficients (Pearson, rp, point-biserial, rpb, and phi, r#) [12-14].

The Wilcoxon signed-rank test for paired samples was used to evaluate the differences between static and dynamic TTTG values. The intermethod and interrater agreements were assessed using intraclass correlation coefficient (ICC), with visualization on Bland-Altman plots [15].

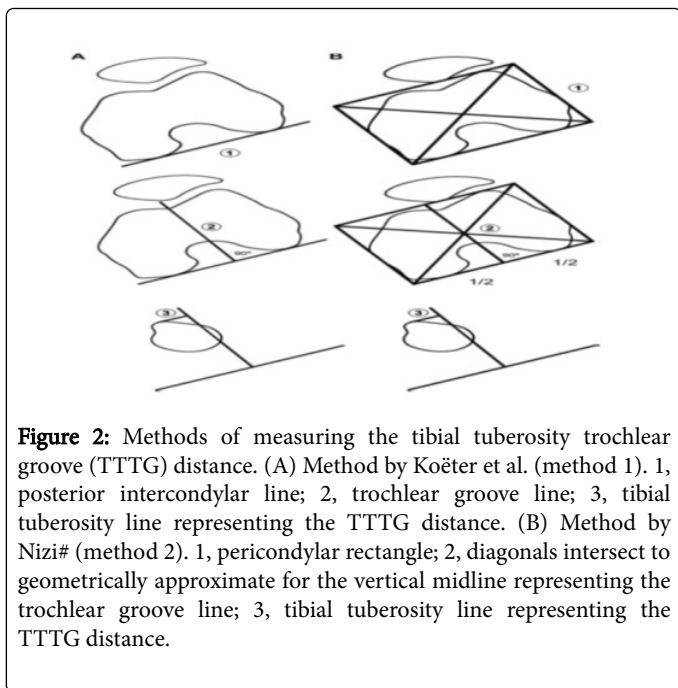


Figure 2: Methods of measuring the tibial tuberosity trochlear groove (TTTG) distance. (A) Method by Koeter et al. (method 1). 1, posterior intercondylar line; 2, trochlear groove line; 3, tibial tuberosity line representing the TTTG distance. (B) Method by Nizi# (method 2). 1, pericondylar rectangle; 2, diagonals intersect to geometrically approximate for the vertical midline representing the trochlear groove line; 3, tibial tuberosity line representing the TTTG distance.

Results

No significant association was detected when the clinical record of J-sign was compared to various variables, such as age ($P=0.127$), sex ($P=0.329$), laterality ($P=0.383$), presence of trochlear dysplasia ($P=0.999$) and severe trochlear dysplasia ($P=0.651$), or TTTG values obtained by both methods, whether non-dichotomized ($P=0.457$ to 0.655), or dichotomized ($P=0.347$ to 1.000), as well as clinical record of prior lateral patellar (sub)luxation ($r\#=-0.07$, $P=1.000$). Out of 55 knees, 50 (90.0%) were dysplastic, with 27 (49.1%) exhibiting trochlear dysplasia type A, 15 (27.3%) type B, 5 (9.1%) type C, 3 (5.5%) type D and 5 (9.1%) were non-dysplastic. Therefore, 18 (32.7%) knees had high-grade trochlear dysplasia. On average, the mean value of the TTTG distance was 21.3 ± 5.70 mm for method 1, and 21.5 ± 4.53 mm for method 2.

The TTTG values, non-dichotomized as well as dichotomized, were not associated with age ($P=0.107$ to 0.873), laterality ($P=0.165$ to 1.000), or trochlear dysplasia ($P=0.140$ to 0.643), yet showed a low positive correlation with sex ($rpb=0.43$ to 0.50 , $P<0.0001$ to 0.001 , and $r\#=-0.37$ to 0.46 , $P=0.0007$ to 0.009 , respectively), except in one case (method 2, rater 1: $r\#=-0.26$, $P=0.098$) [16]. The non-dichotomized TTTG values in static and dynamic imaging conditions were not significantly different with regard to both methods ($P=0.348$ to 0.987) (Figure 5). The intermethod correlation was very high for each rater ($n=53$, $rp=0.90$, $P<0.0001$, $rp\ 2=0.81=81.0\%$, and $n=54$, $rp=0.92$, $P<0.0001$, $rp\ 2=0.85=85.0\%$, respectively). Both intermethod and interrater agreements were almost perfect (0.937 ; 95% CI, $0.891-0.964$, 0.944 ; 95% CI, $0.902-0.968$, and 0.982 ; 95% CI, $0.968-0.989$ and 0.994 ; 95% CI, $0.989-0.997$, respectively), with little to very little bias (-0.35 , -0.63 and 0.39 , 0.08 , respectively). Method 1 systematically underestimated the TTTG values while method 2 showed 1.6 times lesser mean variance, with 5 times lesser interrater bias and 2 times narrower limits of agreement [17].

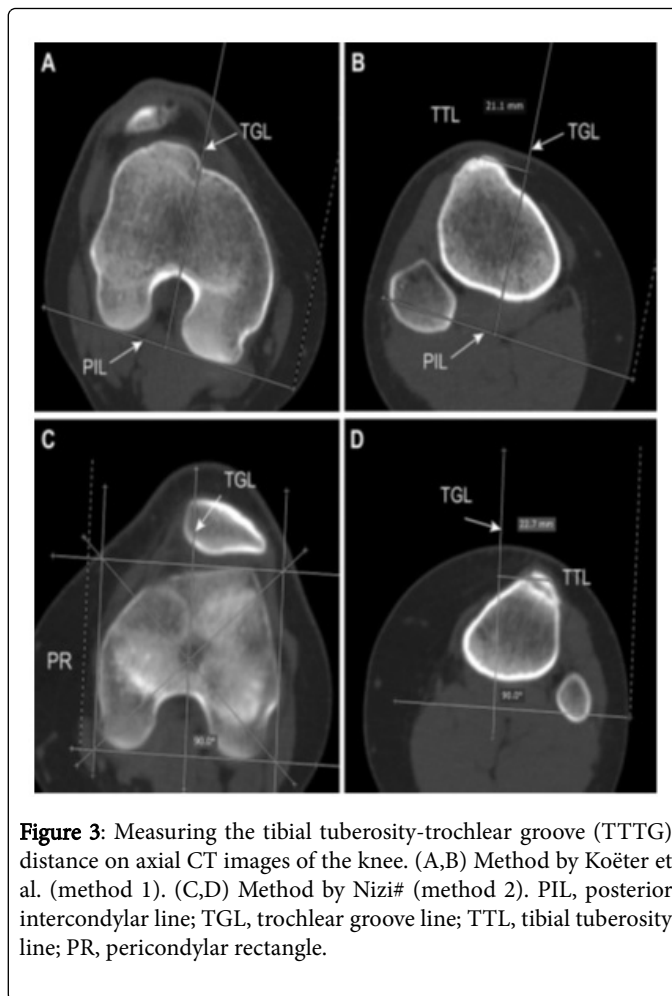


Figure 3: Measuring the tibial tuberosity-trochlear groove (TTTG) distance on axial CT images of the knee. (A,B) Method by Koeter et al. (method 1). (C,D) Method by Nizi# (method 2). PIL, posterior intercondylar line; TGL, trochlear groove line; TTL, tibial tuberosity line; PR, pericondylar rectangle.

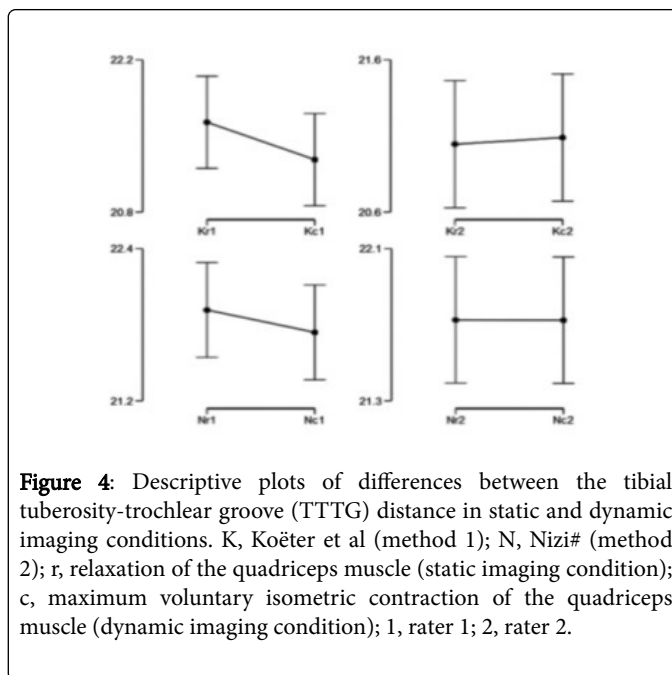


Figure 4: Descriptive plots of differences between the tibial tuberosity-trochlear groove (TTTG) distance in static and dynamic imaging conditions. K, Koeter et al (method 1); N, Nizi# (method 2); r, relaxation of the quadriceps muscle (static imaging condition); c, maximum voluntary isometric contraction of the quadriceps muscle (dynamic imaging condition); 1, rater 1; 2, rater 2.

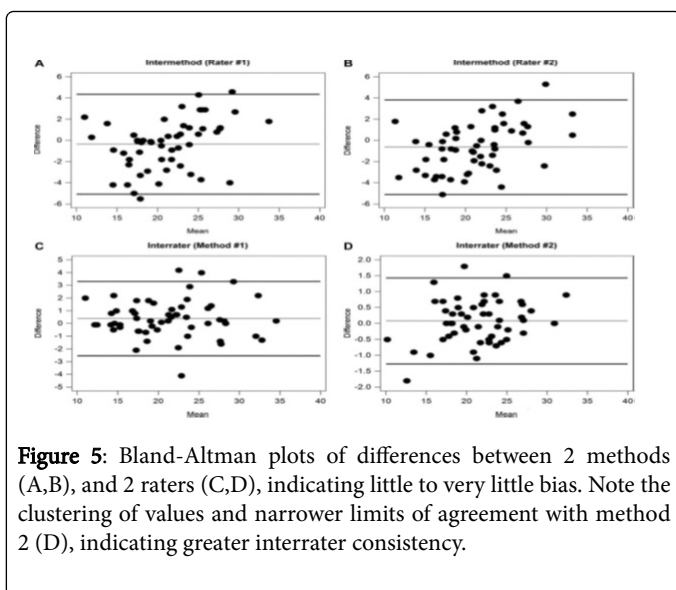


Figure 5: Bland-Altman plots of differences between 2 methods (A,B), and 2 raters (C,D), indicating little to very little bias. Note the clustering of values and narrower limits of agreement with method 2 (D), indicating greater interrater consistency.

Conclusion

The clinical manifestation of the J-sign, considered a dynamic marker of patellofemoral instability, has been frequently associated with numerous conditions, such as trochlear dysplasia, higher values of the Q-angle, and lateralized tibial tuberosity, yet its fundamental cause remains unknown, and the diagnostic value uncertain. To the best of our efforts, we have not been able to detect a comparable study to analogize. If the TTTG distance were indeed a radiological analogue of the Q-angle, which in itself is dubious, we could draw a parallel with the study by Sheehan et al. [18] who found no correlation of the Q-angle and the clinical J-sign. McDermott et al. [19] deemed the J-sign useful as preoperative estimation of the distance needed for tibial tuberosity transfer, quantifying the clinical J-sign with the help of preoperative axial MRI-images in full knee extension and 30 degrees of flexion. Edwards et al. [20] falsely hypothesized that the quadriceps active measure of the lateral patellar edge was the best predictor of how far the tibial tuberosity needs to be transferred to in order to eliminate the J-sign.

Nevertheless, both studies are conceptually and methodologically too distant to allow any juxtapositions. We can, therefore, merely speculate that our results indirectly support the theory of the clinical J-sign as an indicator of ligamentous disorder rather than a patellofemoral malalignment, as the deficiency of the vastus medialis muscle seems an unlikely cause. Even so, the association of the clinical J-sign with other relevant indices of patellofemoral maltracking, such as patella alta or patellar tilt, remains to be thoroughly scrutinized. Since the biases available from the literature (up to 4.5 mm) exceeded the biases obtained in our study (0.08 to 0.63 mm), both methods appeared interchangeable. In addition, the interrater agreement was almost perfect, which is similar to other studies, at least partially comparable in this segment. As to limitations, the sex bias was evident, yet expected. Also, we have not evaluated intrarater agreement because the purpose of this study was not to fully validate the two methods but rather to investigate the potential association of J-sign with the TTTG distance. Moreover, the intrarater validation of the TTTG distance has already been investigated.

References

1. Callaghan JJ, Rosenberg AG, Rubash HE, Simonian PT, Wickiewicz TL (2003) *The adult knee. Volume 1* Philadelphia, PA: Lippincott Williams & Wilkins, USA 330.
2. Luhmann SJ, Schoenecker PL, Dobbs MB, Gordon JE (2008) Adolescent patellofemoral pain: Implicating the medial patellofemoral ligament as the main pain generator. *J Child Orthop* 2: 269-277.
3. Andrish J (2008) The management of recurrent patellar dislocation. *Orthop Clin North Am* 39: 313-327.
4. Bonin M, Amendola NA, Bellemans J, MacDonald S, Ménétrey J (2012) *The knee joint: Surgical techniques and strategies*. Paris: Springer Verlag France.
5. Minkowitz R, Inzerillo C, Sherman OH (2007) Patella instability. *Bull NYU Hosp Jt Dis* 65: 280-293.
6. Weber AE, Nathani A, Dines JS, Allen AA, Shubin-Stein BE, et al. (2016) An algorithmic approach to the management of recurrent lateral patellar dislocation. *J Bone Joint Surg Am* 98: 417-427.
7. Gerbino PG (2006) Immature and adolescent athletes. In: Schepsis AA, Busconi BD (eds). *Sports medicine*. Philadelphia, PA: Lippincott Williams & Wilkins, USA 74.
8. Beaconsfield T, Pintore E, Maffulli N, Petri GJ (1994) Radiological measurements in patellofemoral disorders: A review. *Clin Orthop Relat Res* 308: 18-28.
9. Koëter S, Horstmann WG, Wagenaar FC, Huysse W, Wymenga AB, et al. (2007) A new CT scan method for measuring the tibial tubercle trochlear groove distance in patellar instability. *Knee* 14: 128-132.
10. Nizi D (2012) Comparison of positions of the trochlear groove line and the vertical midline of the pericondylar rectangle on axial computed tomography: A retrospective pilot study. *Skeletal Radiol* 41: 1099-1104.
11. Post WR (1999) Clinical evaluation of patients with patellofemoral disorders. *Arthroscopy* 15: 841-851.
12. Colaco H, Sivananthan S, James L (2012) History and examination techniques. In: Sivananthan S, Sherry E, Warnke P, Miller MD (eds). *Mercer's textbook of orthopaedics and trauma*. (10th edtn). Boca Raton, Florida: CRC Press, USA 26.
13. Fredericson M, Yoon K (2006) Physical examination and patellofemoral pain syndrome. *Am J Phys Med Rehabil* 85: 234-243.
14. Cooney AD, Kazi Z, Caplan N, Newby M, St Gibson CA, et al. (2012) The relationship between quadriceps angle and tibial tuberosity-trochlear groove distance in patients with patellar instability. *Knee Surg Sports Traumatol Arthrosc* 20: 2399-2404.
15. Camp CL, Stuart MJ, Krych AJ, Levy BA, Bond JR, et al. (2013) CT and MRI measurements of tibial tubercle-trochlear groove distances are not equivalent in patients with patellar instability. *Am J Sports Med* 41: 1835-1840.
16. Ho CP, James EW, Surowiec RK, Gatlin CC, Ellman MB, et al. (2015) Systematic technique dependent differences in CT versus MRI measurement of the tibial tubercle-trochlear groove distance. *Am J Sports Med* 43: 675-682.
17. Smith TO, Davies L, Toms AP, Hing CB, Donell ST (2011) The reliability and validity of radiological assessment for patellar instability. A systematic review and meta-analysis. *Skeletal Radiol* 40: 399-414.
18. Sheehan FT, Derasari A, Fine KM, Brindle TJ, Alter KE (2010) Q-angle and J-sign: indicative of maltracking subgroups in patellofemoral pain. *Clin Orthop Relat Res* 468: 266-275.
19. McDermott SE, Anthony CA, McCuniff P, Duchman K, Albright JP (2013) A clinical and radiographic approach for establishing proper tibial tubercle transfer when using quad active femoral nerve stimulation. *Iowa Orthop J* 33: 84-89.
20. Edwards A, Larson E, Albright J (2014) Correlation of radiographic patellofemoral indices with tibial tubercle transfer distance in Fulkerson osteotomy procedures. *Iowa Orthop J* 34: 24-29.