

Case Report

Open Access

# Cytogenetic Evolution in a Patient with Chronic developing a Secondary Acute Myelogenous Leukemia Subtype M5 Resistant to Imatinib Mesylate Therapy

Walid AL Achkar<sup>1\*</sup>, Faten Moassass<sup>1</sup>, Adnan Ikhtiar<sup>2</sup>, Moneeb AK Othman<sup>3</sup>, Thomas Liehr<sup>3</sup> and Abdulsamad Wafa<sup>1</sup>

<sup>1</sup>Human Genetics Division, Flow-cytometry Laboratory; Department of Molecular Biology and Biotechnology, Atomic Energy Commission of Syria, Damascus, Syria

<sup>2</sup>Mammals Biology Division, Flow-cytometry Laboratory; Department of Molecular Biology and Biotechnology, Atomic Energy Commission of Syria, Damascus, Syria

<sup>3</sup>Jena University Hospital, Institute of Human Genetics, Jena, Germany

## Abstract

Here we report an unusual case of Chronic Myelogenous Leukemia (CML) developing towards an Acute Myelogenous Leukemia subtype M5 (AML-M5). The chromosomal constitution was at (final) stage of AML-M5: Philadelphia chromosome positivity with multiple trisomies, a double t (9; 22) (q34; q11) and an AML1/MDS1/EVI1 (AME) fusion transcript resulting from a t (3; 21) (q26; q22). The latter translocation was detectable first in blast phase of CML and remained present in AML-M5 stage. Overall, four chromosomal analyses were done within 19 months, describing the ongoing karyotypic evolution during this transformation. Unfortunately this exceptional patient did not respond to Imatinib- (IM) or Nilotinib-therapy. These finding May by a first hint that CML-patients acquiring a t (3; 21) (q26; q22) might be appropriate to bone marrow transplantation rather than for IM-therapy.

**Keywords:** Chronic myeloid leukemia (CML); Acute myeloid leukemia (AML); Trisomy 9; Fluorescence in situ hybridization (FISH); Imatinib resistant

## Introduction

The Philadelphia (Ph) chromosome is a common cytogenetic abnormality in hematologic malignancies. Although it is most frequently associated with Chronic Myelogenous Leukemia (CML), it can also be present in Adult Precursor B-Lymphoblastic Leukemia/Lymphoma (ALL) and less commonly in pediatric and Adult Acute Myelogenous Leukemia (AML) [1]. At the molecular level, the t (9; 22) (q34; q11) juxtaposes the 5' end of the breakpoint cluster region (BCR) gene on chromosome 22 to the 3' end of the Abelson Tyrosine Kinase (ABL) gene on chromosome 9. CML in blast crisis is often accompanied by the presence of additional chromosomal aberrations [1]. Amongst those, activation of the *EVII* (Ectopic Viral Integration Site 1) gene has been reported in a small percentage of patients; ectopic expression of the *EVII* gene is usually due to recurrent 3q26 rearrangements such as the t(3;21)(q26;q22) and the inv(3;3)(q21q26) [1]. The t (3;21) (q26;q22) resulting in the AML1/MDS1/EVI1 (AME) fusion is reported in t-AML, t-MDS (i.e. myelodysplastic syndrome) and in CML [2]. In this translocation parts of the AML1 gene could be fused to one of the two aforementioned genes which are adjacent in 3q26. These fusion products, in cooperation with other genetic abnormalities, are capable of blocking myeloid differentiation possibly by interfering with the normal transcriptional regulatory functions of AML1. Furthermore, they initiate malignant transformation in cell lines and myeloid leukemia in mouse tumor models. However, the clinical features of t(3;21)-associated human leukemia have not been well defined to date due to the lack of any large clinical case studies [3].

The association of acquired trisomies involving various chromosomes and hematological malignancies is well established. The presence of some single acquired autosomal trisomies may be indicative for prognosis, too [4]. Trisomies 9 and 10 are rare observed in AML [4,5].

Here we reported a Ph chromosome positive Acute Myelogenous Leukemia Subtype M5 (AML-M5) which transformed from a Chronic Myelogenous Leukemia (CML) presenting multiple trisomies,

including a double t (9; 22) (q34; q11) and an AME fusion transcript resulting from a t(3;21)(q26;q22).

## Case Report

A 27-year old male was diagnosed with CML in chronic phase in March 2010 due to splenomegaly. In June 2011, the patient presented for the third time (Table 1) with a WBC of  $4.3 \times 10^9/l$  consisting of 48.6% neutrophils, 27.7% lymphocytes and 23.7% monocytes. The platelets count was  $55 \times 10^9/l$  and the hemoglobin level was 10.1 g/dl. The serum LDH level was 1024 U/l and the serum Alkaline Phosphatase (ALP) level was 301 U/l (normal level up to 300 U/l). The patient was treated with Imatinib mesylate (IM) at 400 mg/day for overall 15 months in the total; treatment regime was not altered as still the clinicians expected to have a positive effect from it even after blastic change was evident. In October 2011, the patient presented for the fourth time, having a WBC of  $4.4 \times 10^9/l$  consisting of 63% neutrophils, 28.4% lymphocytes and 8.4% monocytes (Table 1). The platelets count was  $70 \times 10^9/l$  and the hemoglobin level was 12 g/dl. The serum LDH level was 900 U/l. The patient was treated with Nilotinib at 800 mg/day for overall 4 months. In November 2011, he passed away under the treatment due to unknown reasons.

Karyotyping was performed one time before, two times during IM treatment and one time under Nilotinib treatment (Table 1). Initially a CML-specific karyotype 46, XY, t (9; 22) (20) was found, which evolved

**\*Corresponding author:** Walid Al-Achkar, Human Genetics Division, Department of Molecular Biology and Biotechnology, Atomic Energy Commission of Syria, 17th Nissan St., Kafersouseh, Damascus, 6091, Syria, Tel: 963-11-2132580; Fax: 963-11-6112289; E-mail: [ascientific@aec.org.sy](mailto:ascientific@aec.org.sy), [i8lith@mtl.uni-jena.de](mailto:i8lith@mtl.uni-jena.de)

Received May 22, 2013; Accepted July 18, 2013; Published July 22, 2013

**Citation:** Achkar WAL, Moassass F, Ikhtiar A, Othman MAK, Liehr T, et al. (2013) Cytogenetic Evolution in a Patient with Chronic developing a Secondary Acute Myelogenous Leukemia Subtype M5 Resistant to Imatinib Mesylate Therapy. J Leuk 1: 118. doi:10.4172/2329-6917.1000118

**Copyright:** © 2013 Achkar WAL, et al. This is an open-access article distributed under the terms of the Creative Commons Attribution License, which permits unrestricted use, distribution, and reproduction in any medium, provided the original author and source are credited.

within 6 months under IM therapy to a more complex one: 46, XY, t (3; 21) (q26; q22), t (9; 22) (q34; q11.2) (7) /46, XY (13). This evolution continued and 15 months after diagnosis the karyotype was 51, XY, t (3;21) (q26;q22), +8, +9, t (9;22) (q34;q11.2) x 2, +10, +12, +22 (20) (Figure 1 and 2). Interestingly, under Nilotinib the karyotype became less complex and was: 49, XY, t (3; 21) (q26; q22), +8, t (9; 22) (q34; q11.2) x2, +10, +22 (16) /46, XY [4].

RT-PCR-analysis for BCR/ABL and AME fusion transcripts were done on samples taken 6, 15 and 19 months after diagnosis. Test for BCR/ABL demonstrated the presence of a p210, b2a2 fusion transcript most often found in CML at all three times (Figure 3A). DNA sequencing for BCR/ABL kinase domain did not show any mutation (data not showed). The t (3; 21) translocation was characterized in more detail by multiplex RT-PCR, which revealed a typical AME fusion transcript product of 832 bp (Figure 3B) in all three samples.

Sanger DNA sequencing confirmed the presence of AME fusion transcripts with breakpoints in MDS1 at amino acid position 115 (asparagine) and 227 (glutamic acid), and in EVI1 at amino acid 26

(methionine); the AML1 breakpoint was located at amino acid 821 (glutamine) (Figure 3C).

Immunophenotypic analysis of peripheral blood at all four times of cytogenetic studies is summarized in table 1. The immunophenotype of the last two patient samples were consistent with AML-M5 according to FAB classification.

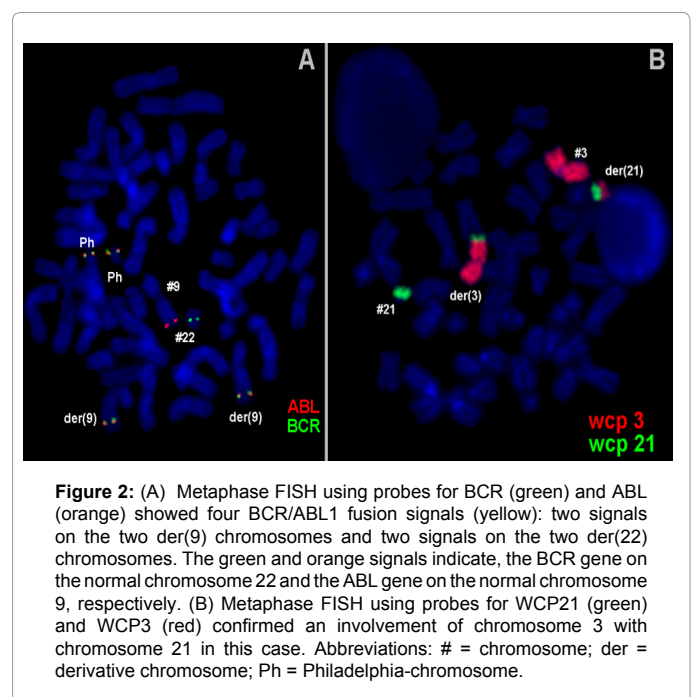
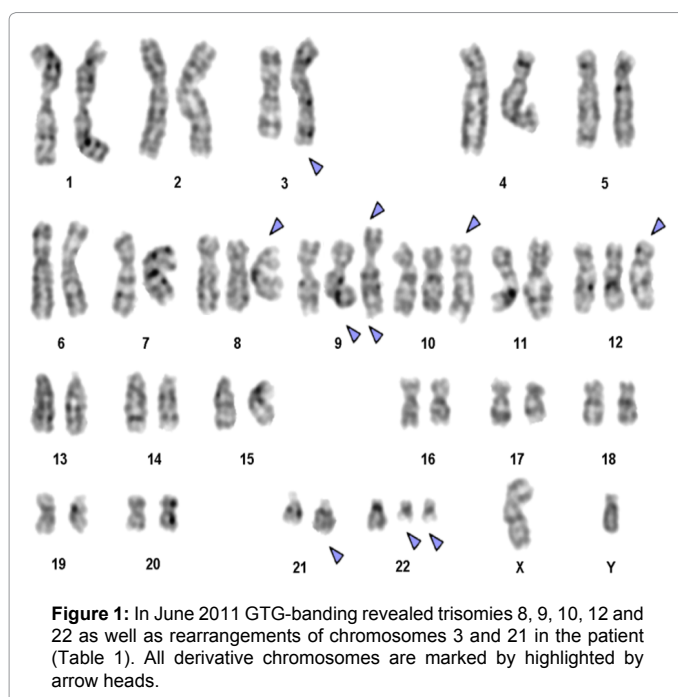
## Discussion

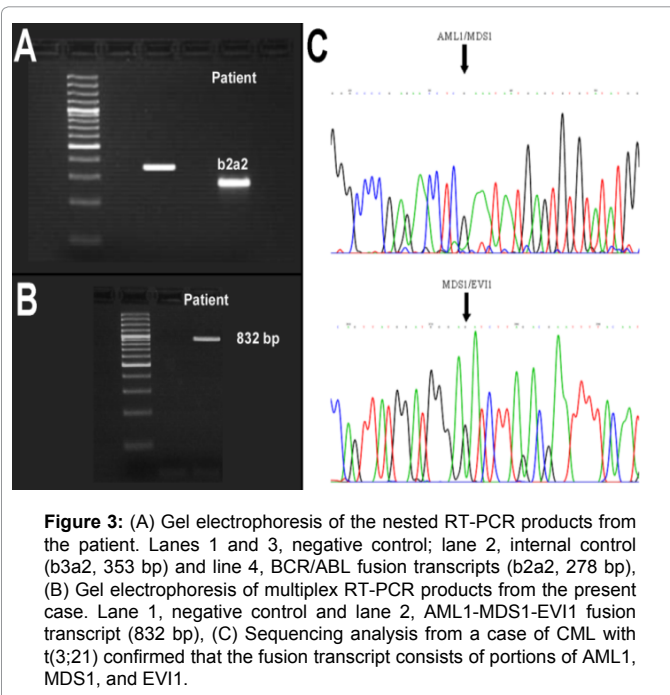
According to the literature, a t (3; 21) (q26; q22) with multiple trisomy is a recurrent cytogenetic abnormality in two similar cases [3,6]. To the best of our knowledge, a karyotype and karyotypic evolution such as seen in the present case with expression of the AME fusion protein has never been described before in AML or CML [7]. Overall, the patient unexpectedly developed an AML-M5 from an initial CML, a development which we could also depict in terms of accompanying (cyto-) genetic changes.

It has been previously demonstrated that in t (3;21)-associated leukemia [2] and the fusion of AML1 with MDS1 may interfere with

Appointment	Phase	Methods	Hematologic parameters	Treatment	Results
1. March 2010	CML chronic phase	GTG, FISH	WBC 149.8×10 <sup>9</sup> /l with 80% neutrophils, 13% lymphocytes, 6% monocytes and 1% eosinophiles. Plts 702×10 <sup>9</sup> /l and Hgb 8.6 g/dl. LDH level was 739 U/l (normal level up to 480 U/l).	hydroxyurea for 1 month	46,XY,t(9;22) (20)
2. Sept. 2010	CML blast phase	GTG, FISH, RT-PCR	WBC of 4×10 <sup>9</sup> /l consisting of 38.7% neutrophils, 50.1% lymphocytes and 11.2% monocytes. plts 90×10 <sup>9</sup> /l and the Hgb 14.3 g/dl.	Imatinib mesylate at 400 mg/day since May 2010	46,XY,t(3;21),t(9;22)(q34;q11.2)(7)/46,XY(13)
3. June 2011	AML-M5	GTG, FISH, RT-PCR immunophenotyping	WBC of 4.3×10 <sup>9</sup> /l consisting of 48.6% neutrophils, 27.7% lymphocytes and 23.7% monocytes. plts 55×10 <sup>9</sup> /l and Hgb 10.1 g/dl. LDH level was 1024 U/l and ALP 301 U/l (normal level up to 300 U/l).	Imatinib mesylate at 400 mg/ since May 2010	51,XY,t(3;21)(q26;q22),+8,+9,t(9;22)(q34;q11.2)x2,+10,+12,+22(20)
4. Oct. 2011	AML-M5	FISH, RT-PCR	WBC of 4.4×10 <sup>9</sup> /l consisting of 63% neutrophils, 28.4% lymphocytes and 8.4% monocytes. plts 70×10 <sup>9</sup> /l and Hgb12 g/dl. LDH level was 900 U/l.	Nilotinib at 800 mg/ day since Aug. 2011	49,XY,t(3;21)(q26;q22),+8,t(9;22)(q34;q11.2)x2,+10,+22(16)/46,XY[4]
5. Nov. 2011	The patient passed away under the treatment due to unknown reasons				

**Table 1:** Clinical data of the patient together with the corresponding cytogenetic findings.





normal AML1 function and promote transformation [3]. AME may antagonize native AML1 function by interactions with other core binding complex elements including HDAC and CtBP11; its action may be modulated by acetyltransferases. A recent study suggests that AME also may act to down-regulate another core binding factor (CEBPA) by inhibition of protein translation [3]. Intergenic splicing of MDS1 and EVI1 produces a protein with important effects in normal hematopoiesis and leukemogenesis, and the AME function may also be related to inhibition of the normal role of MDS1-EVI1 in myelopoiesis [3].

In IM therapy, BCR-ABL gene amplification resulting from additional Ph copies has been identified as one of the major mechanisms of drug resistance [8]. Despite the absence of mutations in the drug-binding site, the presence of multiple copies of the BCR-ABL oncogene is indicative of a poor prognosis and higher possibilities for resistance to drug treatment [9]. As under IM therapy the initial one Ph chromosome duplicated, this could also have happened in the present case.

The occurrence of t(3;21) translocation together with amplification of BCR-ABL marks the aggressiveness of disease progression [2]. Animal data demonstrate that bone marrow cells co-transfected with BCR-ABL1 and AME rapidly induce an AML-like malignancy in mice. Therefore, coexistence of an EVI1 translocation and BCR-ABL1 is sufficient to cause evolution of myeloid blast crisis [10]. Murine studies demonstrated that AME cooperated more effectively with BCR-ABL1 than MDS1-EVI1 or EVI1 in causing AML with short latency [11].

Trisomies have an overall adverse prognostic value in hematological malignancies. Trisomy 9 is rarely reported in AML, when present has

intermediate prognosis; it has also been considered as marker for benzene-related leukemogenesis, common in systemic mastocytosis and myeloproliferative disorders [4]. Trisomy 10, as a sole cytogenetic abnormality, has rarely been seen in ALL and MDS. However, it is even less frequent in AML, and has an unclear prognostic impact [5].

In conclusion, here we reported a novel cytogenetically case of a Ph chromosome positive CML evolving to an AML-M5 having multiple trisomies, a double t(9;22)(q34;q11) and AME fusion transcript resulting of t(3;21)(q26;q22). The reported patient did not respond positively to chemotherapy. These findings are indicative that CML patients acquiring a t(3;21)(q26;q22) might be subject to bone marrow transplantation rather than to IM-therapy.

#### Acknowledgement

We thank Prof. I. Othman, the Director General of Atomic Energy Commission of SYRIA (AECS) and Dr. N. Mirali, Head of Molecular Biology and Biotechnology Department for their support.

#### Funding Source

This work was supported by the AECS and in parts by the DAAD, Stefan-Morsch-Stiftung and the Monika-Kutzner-Stiftung.

#### Authors' Contributions

AW performed the cytogenetic studies in the present case and collected the data relative to this case report; WA supervised the cytogenetic analysis; AW, MO, TL did the molecular cytogenetic analysis and interpretation; FM did the molecular biology analysis and interpretation; IA did the flow cytometry analysis and AW and TL drafted the paper and all authors contributed to the finalizing of the manuscript.

#### References

1. De Weer A, Poppe B, Cauwelier B, Carlier A, Dierick J, et al. (2008) EVI1 activation in blast crisis CML due to juxtaposition to the rare 17q22 partner region as part of a 4-way variant translocation t(9;22). *BMC Cancer* 8: 193.
2. Phan CL, Megat Baharuddin PJ, Chin LP, Zakaria Z, Yegappan S, et al. (2008) Amplification of BCR-ABL and t(3;21) in a patient with blast crisis of chronic myelogenous leukemia. *Cancer Genet Cytogenet* 180: 60-64.
3. Yin CC, Cortes J, Barkoh B, Hayes K, Kantarjian H, et al. (2006) t(3;21)(q26;q22) in myeloid leukemia: an aggressive syndrome of blast transformation associated with hydroxyurea or antimetabolite therapy. *Cancer* 106: 1730-1738.
4. Chaubey R, Sazawal S, Dada R, Sharma P, Pathak D, et al. (2010) Trisomy 9 in a Patient with Acute Myelogenous Leukemia FAB Type M2: A Rare Occurrence. *Indian J Hematol Blood Transfus* 26: 103-105.
5. Llewellyn IE, Morris CM, Stanworth S, Heaton DC, Spearing RL (2000) Trisomy 10 in acute myeloid leukemia: three new cases. *Cancer Genet Cytogenet* 118: 148-150.
6. Sacchi N, Nisson PE, Watkins PC, Faustinella F, Wijsman J, et al. (1994) AML1 fusion transcripts in t(3;21) positive leukemia: evidence of molecular heterogeneity and usage of splicing sites frequently involved in the generation of normal AML1 transcripts. *Genes Chromosomes Cancer* 11: 226-236.
7. Mitelman F, Johansson B and Mertens F Mitelman (2009) Database of Chromosome Aberrations in Cancer.
8. Bacher U, Haferlach T, Hiddemann W, Schnittger S, Kern W, et al. (2005) Additional clonal abnormalities in Philadelphia-positive ALL and CML demonstrate a different cytogenetic pattern at diagnosis and follow different pathways at progression. *Cancer Genet Cytogenet* 157: 53-61.
9. le Coutre P, Tassi E, Varella-Garcia M, Barni R, Mologni L, et al. (2000) Induction of resistance to the Abelson inhibitor STI571 in human leukemic cells through gene amplification. *Blood* 95: 1758-1766.
10. Paquette RL, Nicoll J, Chalukya M, Elashoff D, Shah NP, et al. (2011) Frequent EVI1 translocations in myeloid blast crisis CML that evolves through tyrosine kinase inhibitors. *Cancer Genet* 204: 392-397.
11. Cuenco GM, Ren R (2004) Both AML1 and EVI1 oncogenic components are required for the cooperation of AML1/MDS1/EVI1 with BCR/ABL in the induction of acute myelogenous leukemia in mice. *Oncogene* 23: 569-579.