

## Cystic Hygroma of the Neck: Prognostic Factors and Therapeutic Implications

Fatnassi Ridha\*, Mkhinini Ines, Ragmoun Housseem, Hammami Sabra and Saidi Wassim

Department of Gynecology and Obstetrics, Ibn Al Jazzar Hospital Kairouan, Tunisia

### Abstract

The cystic hygroma (CH) of the neck is a rare congenital malformation that is due to an abnormal development of lymphatic system. Its gravity is due to the high frequency of chromosomal anomaly and/ or fetal malformations whom are associated to it.

**Objective of the study:** To precise the prognostic features, as well as to bring forward therapeutic strategy.

**Study design:** It is a retrospective study taking place in Kairouan's hospital at gynecologic department lasting two years, from January 2011 to December 2012. During this period we collected nine cases of CH of the neck diagnosed in antenatality thanks to the obstetrical ultrasonography performed in the second trimester and the diagnosis of which is confirmed by the foetopathological examination.

**Results:** Thanks to ultrasonography, the antenatal diagnosis of CH became easy and possible since the tenth week of pregnancy at 22% of cases. The CH is associated with foetal hydrops in 34% of cases and with a malformative syndrome in 22%. Three fetuses were already dead in utero when diagnosing the CH. Karyotype was realized only in six cases in which 66% had chromosomal abnormalities.

On the therapeutic plan, an uterine evacuation was performed to three patients who present already an in utero fetal death. The medical interruption of the pregnancy was indicated for the other cases. A fetopathological exam was systematically performed and had confirmed the diagnosis. Besides, this exam showed a fetal hydrops in 3 cases and a polymalformatif syndrom in two cases.

**Conclusion:** Cystic hygroma is an early suggestive sign of chromosomal aberration or malformative abnormalities. Prognostic features are well established: hydrops, malformative syndrome and karyotype abnormalities. Once one or several bad prognosis factors are identified, this justify a medical interruption of pregnancy.

**Keywords:** Cystic hygroma; Antenatal diagnosis; Chromosomal abnormality; Foetal hydrop

### Introduction

The cystic hygroma (CH) of the neck is defined as a unique liquid tumour, most commonly bilateral and behind the neck. It is due to abnormalities in the development of the lymphatic system [1-4].

It is a rare malformation which can be isolated or associated either with other lymphatic system abnormalities or with chromosomal aberrations or malformative syndromes. This abnormality can be transitory or persistent [2]. Thanks to the fetal ultrasonography, the antenatal diagnosis of this malformation is already possible in the first trimester of pregnancy.

It is particularly important to discover this abnormality because it can alert early of chromosomal aberrations or foetal structural anomalies [2,3].

This malformation has often a dark prognosis, particularly when it is associated with a foetal hydrops. However in some cases, it resolves spontaneously and the pregnancy evolves until term. This evolutionary disparity and the lack of knowledge of prognosis factors explain the difficulties of management of this affection.

The aim of our study is to identify the pronostic elements and propose a pragmatic therapeutic approach.

### Study Design

It is a retrospective analytic study based on patients' files taking place in Kairouan's hospital at gynecologic department, lasting two years, from January 2011 to December 2012.

During this period we collected nine cases of CH of the neck diagnosed thanks to the ultrasonography in the first two trimesters of pregnancy.

All our patients performed an ultrasonography in the first trimester (between 10 and 14 weeks of amenorrhea) and a morphological ultrasound between 20 and 24 weeks of amenorrhea. We have adopted in our study only the foeti who carry a cystic malformation with septa and retro-cervical localization, that is isolated or associated with other anomalies. The highlighting of a cystic hygroma imposes a specialized ultrasound and a fetal karyotype.

### Exclusion's criteria

- Other cervical tumours such as cystic lymphangioma, increased nuchal translucency
- Malformations in the central neural system such as meningocele and myelomeningocele

\*Corresponding author: Fatnassi Ridha, Department of Gynecology and Obstetrics, Ibn El Jazzar Hospital – Kairouan, 3140 Kairouan, Tunisia, Tel: + 216 98 451 341; E-mail: [ridha.fatnassimohamed@ms.tn](mailto:ridha.fatnassimohamed@ms.tn)

Received November 25, 2015; Accepted December 14, 2015; Published December 22, 2015

**Citation:** Ridha F, Ines M, Housseem R, Sabra H, Wassim S (2015) Cystic Hygroma of the Neck: Prognostic Factors and Therapeutic Implications. Gynecol Obstet (Sunnyvale) 5: 345. doi:10.4172/2161-0932.1000345

**Copyright:** © 2015 Ridha F, et al. This is an open-access article distributed under the terms of the Creative Commons Attribution License, which permits unrestricted use, distribution, and reproduction in any medium, provided the original author and source are credited.

We aim to analyse the elements of the diagnosis and the prognosis of the CH of the neck in order to propose a practical attitude to have facing a CH of the neck.

## Results

The mean age of our patients was 27,1 years with extremes from 19 to 40 years. Most of our patients were pauciparus and 44 % were nulliparus. No women had anterior CH of the neck and only one patient had a former new born suffering from Down's syndrome who died in two days. The CH of the neck was discovered by chance in 6 women and because of decrease in the foetal moves in the other 3 patients. The diagnosis took place in pregnancy of less than 20 weeks of amenorrhea in 7 cases. It was possible from the twelfth week of amenorrhea in 22% of the patients. The diagnosis was late in two cases in the second trimester of pregnancy.

The ultrasonographic aspect was suggestive in all patients with bi or multi parted off liquid retro cervical formation with a waving size (Figure 1a and 1b).

A foetal hydrops was seen in 34 % of the cases. 3 fetuses were already dead in utero when the diagnosis of the CH of the neck was made. The karyotype analysis using amniocentesis was performed in only 5 cases. It was abnormal in 66% of cases: a Down syndrome in two cases and a Turner syndrome in one.

Concerning the outcomes of the pregnancy, the 3 patients with intra uterine foetal death had a uterine evacuation; the other patients were proposed a pregnancy therapeutic interruption. Only one woman refused because of the normality of the karyotype, but the pregnancy prospect was an intra uterine foetal death at 24 weeks of pregnancy. A foetopathological examination was performed in all the cases. It confirmed the diagnosis of CH of the neck in all cases (Figure 2).

A foetal hydrops was associated in 3 fetuses, multiple foetal structural anomalies were diagnosed in 2 cases and a suggestive aspect of monosomy X in one foetus (Table 1).

## Discussion

The CH of the neck is the most screened anomaly during the first trimester of pregnancy. Its prevalence is about 1 % of all the ultrasonographic exams during the first trimester and it represents 10% of all the malformations diagnosed during the second trimester of pregnancy. On term, its frequency is about 17/100 000 births [5]. This decrease in frequency is due to the high rate of spontaneous abortion, intra uterine foetal deaths and of therapeutic pregnancy interruption.

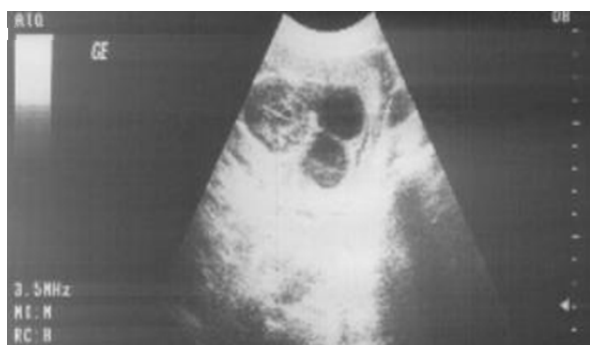

Figure 1a: Obstetrical ultrasonography at 10 WP Bi parted off Cystic Hygroma retro cervical.

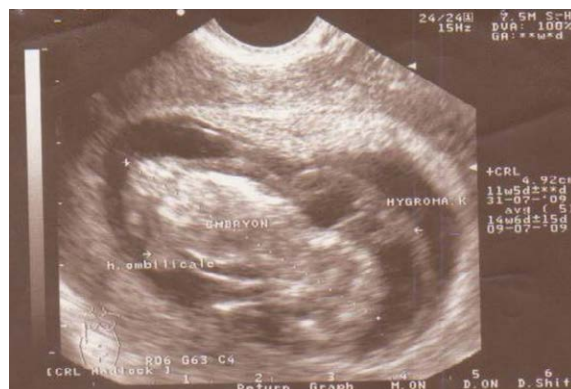

Figure 1b: Obstetrical ultrasonography at 10 WP Enormous nuchal Cystic Hygroma.

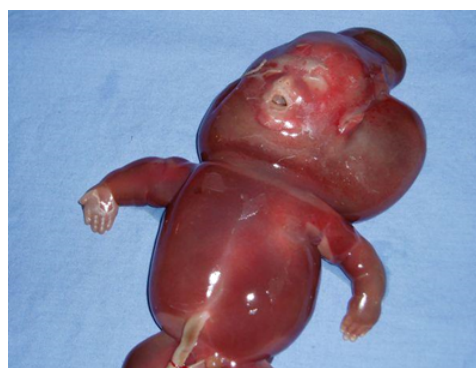

Figure 2: Abortive product cystic hygroma of the neck associated with foetal hydrops.

Contrasting with chromosomal abnormalities, older women are not at a higher risk of CH. In our series, 78% of the patients were young (under 35 years old). By the way, no risk features for CH have been identified in literature.

CH of the neck results from developing abnormalities in the lymphatic system. This system develops from five primitive cistern resulting from budding of the venous system [6].

These cisterns are made of:

- Two bags flanking the internal jugular vein.
- A retroperitoneal bag on the bases of the mesenteric vein.
- Two iliac bags behind the sciatic vein.

These primitive bags connect with eleven other cisterns and undergo budding centrifugal lymphatic system to the device. These lymphatic cisterns are drained by the adjacent venous system. The only constant connection is the lymphatic-jugular one.

The CH occurs by partitioning of these cisterns or lack of communication with the adjacent venous system, in this case the internal jugular. Dilated jugular cisterns lead to fluid cavities. When the blockage is total, CH gradually increases in volume and can lead to compression of the foetal venous return, causing foetal hydrops. At the contrary, when the blockage is partial or if a secondary connection is established with the lymphatic system, the anomaly may regress (Figure 3).

Case N°	Age (year)	G. P.A	ATCDS	circumstances of diagnosis	Term (W.P)	Echo	Caryotype	Foetopathology
1	19	G1P0	0	By chance	13	Multi parted off C.H. dropsy + pleurisy	45 X 0	C.H. + severe foetal hydrops
2	34	G13P4 A9	Abortive illness	By chance	10	C.H.	T21	C.H. +facial dysmorphia + micromélie
3	28	G1	0	By chance	10	Bi parted off C.H.	46 XY	Bilatéral C H
4	27	G2P1	0	Decrease in foetal active moves	15	Multi parted off C.H. C. A. (-)	N.D.	Suggestive aspect of 45 X 0
5	40	G10P9 A1	0	Decrease in foetal active moves	26	Multi parted off C.H. diagnosed as an amniotic band C.A. (-)	N.D.	C.H. + polymalformative syndrome
6	23	G2P1	0	Decrease in foetal active moves	22	Multi parted off C.H. C.A. (-) foetal hydrops	N.D.	CH+Foetal hydrops
7	25	G1	0	By chance	10	C.H.	47XXT18	CH+ polymalformative syndrome.
8	26	G2P1	Trisomie21	Family indexed case	12	Bi parted off C.H.	46 XX	CH+Aorto-aortic coarctation.
9	22	G1	0	By chance	13	Foetal hydrops	T21	Bilatéral C.H. + Foetal hydrops

Table 1: Summarising the observations.

In humans, the formation of these cisterns is usually complete in 8 WP. The progress of ultrasonography are that CH can be diagnosed from the seventh or eighth week of pregnancy [1,2,4].

In addition, 95% of foetal CH develop in the neck [1], their antenatal diagnosis by ultrasonography is easy and fundamental. In fact, CH is an important and early sign of chromosomal anomalies, polymalformative syndromes and genetic anomalies. Antenatal diagnosis of CH of the neck is only ultrasonographic.

The usual aspect is that of a rounded bi parted off cyst, located bilaterally at the back of the neck region. This fluid image often includes a floating partition featured by being bifid at its posterior [7].

The diagnosis is sometimes less obvious because of the volume or the ultra sonic structure of the cyst. a multi parted aspect is rarely reported.

The differential diagnosis arises mainly with occipital meningocele characterized by a lack of continuity in the brain's contour [2,8]. At the opposite, the differential diagnosis with the lymphangiomas, the paraxial teratomas and the hemangiomas arises rarely because of their, generally, heterogeneous ultra sonographic structure and especially by their front cervical or thoracic localization [9,10]. In our study, ultrasonographic images were very suggestive in 8 cases for CH. The 9th case was misdiagnosed as an amniotic band while it was an enormous CH.

The retro cervical CH may be isolated or associated with other malformative anomalies affecting the bones, the heart and the kidneys. In literature, this combination is estimated at 60% of cases [3,11,12]. Thus, CH record imposes a repeated and deepened morphological check up searching for a possible underlying abnormality. In our study,

the ultrasound examination found a polymalformative syndrome in 22% of cases and a generalized hydrops in 3 cases.

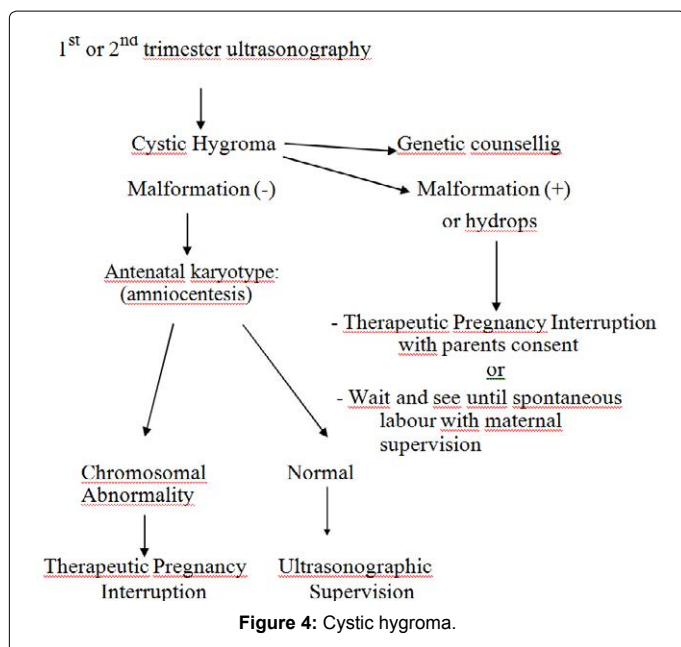
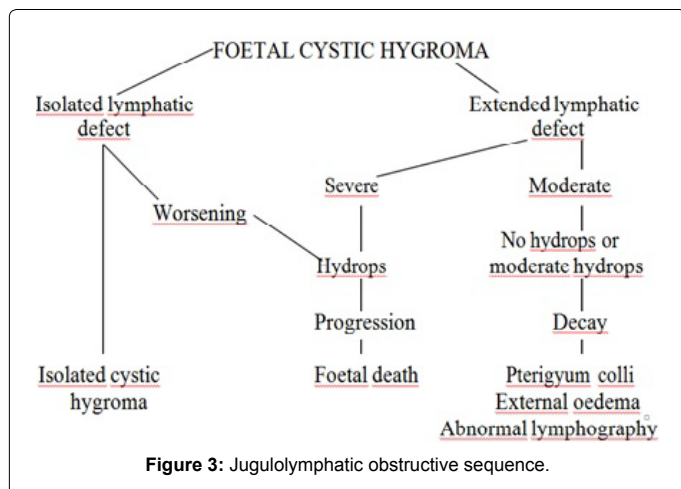
The discovery of a CH always imposes a foetal karyotype . This allows to intervene early in cases of chromosomal abnormalities. At the contrary, the normality of karyotype allows for careful ultrasound morphological monitoring in a referral center. Indeed, even with a normal chromosome formula, the CH of the neck can reveal in 30% of the cases [3,2,13] either a genetic anomaly or a malformative syndrome as the disease of multiple pterygia, Roberts' syndrome or Noonan's syndrome, that is a male Turner's syndrome. In our study, 60 % of the performed karyotypes were abnormal and a malformative syndrome was found in 2 cases. Our study confirm the data of the literature concerning the high rate of chromosomal aberrations and congenital foetal malformations associated to the cystic hygroma. This justify the utility of an etiological evaluation including necessarily a karyotype and a detailed morphological ultrasound.

The prognosis of this malformation is usually dark [3,4,8,14]. It is based on a number of factors: chromosomal abnormalities, associated malformations, foetal hydrops and the regressive nature of the CH.

A Bernard P et al. study [3] based on 190 cases of CH of the neck has largely demonstrated the prognostic value of each criteria cited above:

➤ The karyotype was performed in 149 cases and a chromosomal abnormality was found in 66 % of cases. These anomalies were Turner's syndrome in 66%. Other chromosomal abnormalities are also found: Down's syndrome (15%), trisomy 18 (7.5%), trisomy 13 (13%) [3].

➤ The foetal hydrops has a very dark prognosis. Indeed, the survival rate is only 3.5% of cases without any associated chromosomal



or polymalformative syndrome. In the other hand, without a foetal hydrops, the survival rate is 60% [3].

➤ The spontaneous regression of the CH of the neck is generally regarded as a good prognosis criteria if associated with a normal karyotype [4]. This regression can occur regardless to the size and to the initial presentation of the CH. It does not exclude neither associated chromosomal abnormalities nor severe malformations nor foetal hydrops [3,4].

➤ Besides, it seems that the size and fragmentation of the Hygroma had no prognostic value. Because the size of our sample is reduced, it would thus be impossible to have conclusions nor to confirm or counter the data of the literature in this subject.

The study of the spontaneous evolution of fetuses with CH of the neck is skewed by the high rate (69%) of pregnancy therapeutic interruption [1,4]. In the same study of Bernard [3], he found a rate of 52% of pregnancy therapeutic interruption, 36.5% of spontaneous miscarriages and 4% of neonatal deaths. In our study, a pregnancy therapeutic interruption was performed in 55% cases and in 45% of cases the evolution was to in utero foetal deaths.

The practical attitude to be taken when discovering a CH of the neck during an ultrasound examination depends on the prognosis criteria (Figure 4).

- A normal karyotype is a good prognosis factor. In such cases, it is necessary to insist on the importance of an ultrasound follow-up to look for associated abnormalities.

- A foetal hydrops darkens the prognosis. It requires a deep etiological inquiry. In our series, the diagnosis of an associated foetal hydrops or chromosomal abnormality justified pregnancy therapeutic interruption in 5 cases.

## Conclusion

The CH of the neck is a rare malformation with a dark prognosis. Thanks the progress of the techniques and the machines in the field of ultrasonography, the antenatal diagnosis of CH is easily possible since 10 WP. Because CH of the neck is a very early and suggestive sign of chromosomal or congenital abnormalities, its screening is imperative while performing any ultrasonographic examination. The prognosis factors are clearly established: foetal hydrops, structural in born malformation or chromosomal abnormalities. When present, any of these features, leads most commonly to the therapeutic pregnancy interruption.

## Reference

1. Senat MV, Ville Y (2005) Clarté nucale, nuque épaisse, hygroma kyste au premier trimestre. *Traité d'obstétrique* ed Flammarion 207-213.
2. Aubry MC, Aubry JP (1993) Anomalies de la face et des parties molles. *Echographie des malformations fœtales* ed VIGOT 241-262.
3. Bernard P, Chabaud JJ, Le Guern H, Le Bris MJ, Boog G (1991) [Cystic hygroma of the neck. Antenatal diagnosis, prognostic factors, management. 42 cases]. *J Gynecol Obstet Biol Reprod (Paris)* 20: 487-495.
4. Chervenak FA, Isaacson G, Blakemore KJ, Breg WR, Hobbins JC, et al. (1983) Fetal cystic hygroma. Cause and natural history. *N Engl J Med* 309: 822-825.
5. Ville Y, Lalondrell C, Mulliez N. Hygroma kystique et anomalies de la nuque fœtale. In *papiernik E, Cabrol D. Obstétrique* ed Flammarion, Paris, 375-383.
6. Chervenak FA, Isaacson G, Tortora M (1985) A sonographic study of fetal cystic hygromas. *J Clin Ultrasound* 13: 311-315.
7. Douvier S, Feldman JP, Nivelon-Chevalier A, Degrolard M, Harran MH, et al. (1991) [Retrocervical cystic hygroma: diagnosis, prognosis and management. A series of 13 cases]. *J Gynecol Obstet Biol Reprod (Paris)* 20: 183-190.
8. Abramowicz JS, Warsof SL, Doyle DL, Smith D, Levy DL (1989) Congenital cystic hygroma of the neck diagnosed prenatally: outcome with normal and abnormal karyotype. *Prenat Diagn* 9: 321-327.
9. Leguern H (1986) Images kystiques rétrocervicales fœtales. *Sémiologie échographique, conduite à tenir et discussions. Echo Gynecol obstet* 43: 19-27.
10. Garden AS, Benzie RJ, Miskin M, Gardner HA (1986) Fetal cystic hygroma colli: antenatal diagnosis, significance, and management. *Am J Obstet Gynecol* 154: 221-225.
11. Gellis SS, Feingold M (1978) Picture of the month fetal Turner's syndrome. *Am J Dis Child* 132: 417-418.
12. Poland BJ, Dill F, Paradise B (1980) A Turner-like phenotype in the aborted fetus. *Teratology* 21: 361-365.
13. Redford DH, McNay MB, Ferguson-Smith ME, Jamieson ME (1984) Aneuploidy and cystic hygroma detectable by ultrasound. *Prenat Diagn* 4: 377-382.
14. Rodis JF, Vintzileos AM, Campbell WA, Nochimson DJ (1988) Spontaneous resolution of fetal cystic hygroma in Down's syndrome. *Obstet Gynecol* 71: 976-977.