

## Cutaneous Ulcerations Due To Infection with *Stenotrophomonas Maltophilia*

Aviva C Berkowitz<sup>1</sup>, Caren Waintraub<sup>1</sup>, Alexandra Flamm<sup>1\*</sup>, Catherine Ding<sup>1</sup> and Katy Burris<sup>1,2</sup>

<sup>1</sup>SUNY Downstate, Department of Dermatology, Brooklyn, Newyork, USA

<sup>2</sup>Department of Dermatology, Hofstra North Shore LIJ School of Medicine, Manhasset, Newyork, USA

\*Corresponding author: Alexandra Flamm, SUNY Downstate, Department of Dermatology, 450 Clarkson Ave, Box 46, Brooklyn, NY 11203, USA, Tel: 718-270-1229; Fax: 718-270-2794; E-mail: Alexandra.frydman@downstate.edu

Received date: December 10, 2014, Accepted date: Jan 22, 2015, Published date: Jan 29, 2015

Copyright: © 2015 Berkowitz AC et al. This is an open-access article distributed under the terms of the Creative Commons Attribution License, which permits unrestricted use, distribution, and reproduction in any medium, provided the original author and source are credited.

### Abstract

*Stenotrophomonas maltophilia* is an aerobic gram-negative bacillus that most commonly causes infection in immune-compromised hospitalized individuals, especially those with hematologic malignancy, neutropenia, and history of treatment with broad-spectrum antibiotics. This infection has been known to affect multiple organ systems, but cutaneous involvement has been increasingly recognized over the years, albeit still relatively rare. Here we report a case of ulcerations on the palm and wrist, which were found to be positive for *S. maltophilia*. We also review the various skin and mucocutaneous findings that have been reported with this organism as well as treatment for this often multiple drug resistant organisms.

### Introduction

*Stenotrophomonas maltophilia* is a gram-negative bacillus with both aerobic and anaerobic capabilities and is associated with nosocomial and community-acquired infections [1]. Initially thought to be a relative of *Pseudomonas*, and classified as *Pseudomonas maltophilia*, it was later recognized as its own species of the genus *Stenotrophomonas*. The organism primarily causes infections in immune-compromised patients, frequently via colonization of synthetic devices and machinery [2]. Clinically, *S. maltophilia* can cause bacteremia, endocarditis and respiratory, urinary, ophthalmologic, and central nervous system infections, as well as skin and soft tissue infections, as we describe in the case below [1,3].

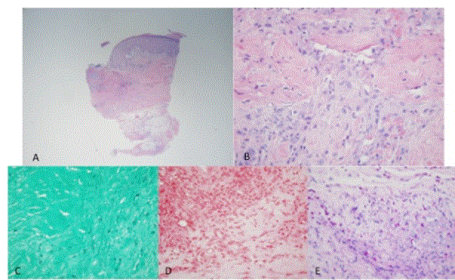
### Case Report

Dermatology was consulted in the inpatient setting to evaluate ulcerations on the wrist of a 68-year-old Panamanian male present for at least one week (Figure 1). The patient had originally been admitted approximately one month prior for dehydration, increasing weakness, diabetic ketoacidosis and acute kidney injury. He was soon after transferred to the intensive care unit due to multiorgan failure and was treated with 3 weeks of linezolid and ceftriaxone for MRSA pneumonia and a urinary tract infection. Past medical history included prostate cancer and diabetes mellitus.

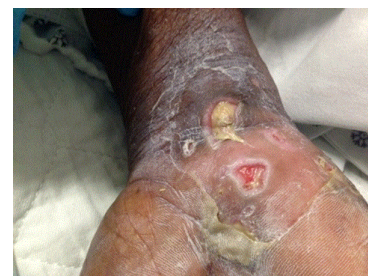

Figure 1: Ulcerations of the right ventral wrist and palm.

Physical examination was notable for several well-demarcated ulcerations with angulated borders and fibrinous yellow exudate on the right ulnar wrist and palmar surface of the right hand. Several rounds, superficial ulcerations were found on the mucosal surface of the lower lip. Viral cultures and biopsies for H&E and tissue culture were performed. Viral cultures were negative for growth, and H&E demonstrated multiple bacterial colonies in the dermis that were negative on gram stain but positive on PAS and GMS (Figure 2). Tissue culture grew *S. maltophilia*, sensitive to ceftazidime and trimethoprim-sulfamethoxazole (TMP-SMX), along with *Staphylococcus aureus*. Urine culture was also positive for *S. maltophilia*. The patient then completed a week course of Bactrim DS with eventual resolution of the cutaneous findings and clearance of urine cultures.



**Figure 2:** Histopathologic findings of right palm ulcer on H&E at 4x (A) and 40x (B). Gram stain, GMS, and PAS at 40x (C-E), shown respectively.

## Discussion

*S. maltophilia* can cause a variety of mucocutaneous findings. Vartivarian described five patients with *S. maltophilia*-related primary cellulitis, mostly associated with catheter use, as well as six patients with metastatic cellulitis [2]. Cellulitis-like lesions of the legs and chest have also been described in three additional patients, likely due to septic emboli [4]. Ecthyma gangrenosum has been reported in association with *S. maltophilia* infection in a patient with a recent allogeneic bone marrow transplantation [5]. Mucocutaneous infections, as seen here, have also been noted, with ulcerations described on the lips, gingiva, and buccal mucosa [2]. Non-healing leg and foot ulcers and digital skin ulcer associated with the pathogen have also been described [6-8].

Hospitalized patients who are immunocompromised are at greatest risk of developing infection with *S. maltophilia*, though cases in immunocompetent individuals have rarely been described [6,8]. Most occur in the setting of malignancy, particularly hematologic cancers being treated with chemotherapy. Other risk factors include administration of broad-spectrum antibiotics and use of intravenous catheters, mechanical ventilation or tracheotomy [3,4,6,9,10].

The route of infection is not entirely known, but it seems that the organism invades via damaged skin and mucous membranes, or colonization of venous catheters, and then spreads hematogenously [2,4,10]. Recovery is dependent upon early recognition of the infection and treatment with effective antibiotics [1,10]. *S. maltophilia* has become resistant to many broad-spectrum antimicrobial agents, including beta-lactams, carbapenems and aminoglycosides; therefore,

the current therapy of choice is TMP-SMX, due to its activity against most strains of the bacterium. Removal of all associated invasive synthetic devices is also critical [2].

It is important that *S. maltophilia* be considered in the differential diagnosis of a skin or soft tissue infection in an immunocompromised patient with malignancy, particularly due to its high resistance to therapy. Our case contributes to the growing body of knowledge regarding skin manifestations attributed to *S. maltophilia* infection, and highlights the need to consider this pathogen when presented with an ulcer of unknown etiology in an immunocompromised patient.

## References

1. Marshall WF, Keating MR, Anhalt JP, Steckelberg JM (1989) *Xanthomonas maltophilia*: an emerging nosocomial pathogen. Mayo Clin Proc 64: 1097-1104.
2. Vartivarian SE, Papadakis KA, Palacios JA, Manning JT Jr, Anaissie EJ (1994) Mucocutaneous and soft tissue infections caused by *Xanthomonas maltophilia*. A new spectrum. Ann Intern Med 121: 969-973.
3. Jang TN, Wang FD, Wang LS, Liu CY, Liu IM (1992) *Xanthomonas maltophilia* bacteremia: an analysis of 32 cases. J Formos Med Assoc 91: 1170-1176.
4. Moser C, Jönsson V, Thomsen K, Albrechtsen J, Hansen MM, et al. (1997) Subcutaneous lesions and bacteraemia due to *Stenotrophomonas maltophilia* in three leukaemic patients with neutropenia. Br J Dermatol 136: 949-952.
5. Son YM, Na SY, Lee HY, Baek JO, Lee JR, et al. (2009) Ecthyma Gangrenosum: A Rare Cutaneous Manifestation Caused by *Stenotrophomonas maltophilia* in a Leukemic Patient. Annals of dermatology 21: 389-392.
6. Nag F, De A, Banerjee K, Chatterjee G (2013) Non healing leg ulcer infected with *Stenotrophomonas maltophilia*: first reported case from India. Int Wound J 10: 356-358.
7. Smeets JG, Lowe SH, Veraart JC (2007) Cutaneous infections with *Stenotrophomonas maltophilia* in patients using immunosuppressive medication. Journal of the European Academy of Dermatology and Venereology: JEADV 21: 1298-1300.
8. Trignano E, Manzo MJ, Fallico N, Maffei M, Marongiu F, et al. (2014) First report of digital skin ulcer with *Stenotrophomonas maltophilia* infection in an immunocompetent patient. In Vivo 28: 259-261.
9. Sakhnini E, Weissmann A, Oren I (2002) Fulminant *Stenotrophomonas maltophilia* soft tissue infection in immunocompromised patients: an outbreak transmitted via tap water. The American journal of the medical sciences 323: 269-272.
10. Teo WY, Chan MY, Lam CM, Chong CY (2006) Skin manifestation of *Stenotrophomonas maltophilia* infection--a case report and review article. Ann Acad Med Singapore 35: 897-900.