

Coronary Spasm Associated with Nitroglycerin Administration – A Case Report and Review of the Literature

Yasmin S. Hamirani* and Mark J. Ricciardi

Division of Cardiology, University of New Mexico School of Medicine, Albuquerque, NM

Abstract

Background: Paradoxical coronary artery vasospasm following the administration of nitroglycerin (NTG) has been described but is exceedingly rare. All prior case reports note post NTG spasm of the proximal most coronary segment after either Sones or Judkins technique selective coronary angiography.

Methods and results: We describe mid left anterior descending artery spasm during coronary angiography using the Judkins technique following administration of sublingual NTG. Subsequent intravascular ultrasound revealed mild fibrofatty plaque in the area in question.

Conclusion: This report is the first to describe NTG-induced coronary spasm in a non-proximal vessel segment and may have implications for assessing severity of coronary stenoses and anecdotal patient complaints of worsening angina with NTG.

Keywords: Nitroglycerin; Coronary vasospasm; Coronary angiography

Introduction

Coronary artery vasospasm following administration of sublingual (SL) nitroglycerin (NTG) was first described in the literature by Feldman and colleagues in 1978 [1]. The frequency of this finding and its clinical significance is unknown; however, it is corroborated by other reports of paradoxical blood pressure elevation after nitroglycerin administration [2] and anecdotally noted rare patient complaints of worsening angina following self administration of SL NTG. Unlike all prior reports where spasm of the proximal vessel spasm, we describe a case of mid vessel coronary spasm following NTG administration documented during coronary angiography using the Judkins technique and provide a review of the literature.

Case Report

A 71 year old man was referred to our laboratory for percutaneous coronary intervention (PCI) of a mid left anterior descending artery (LAD) lesion found on diagnostic angiography. The diagnostic study was performed for recurrent angina and anterior perfusion abnormality nine months after anterior ST elevation MI treated with proximal LAD bare metal stent placement. He had no rest symptoms. He was an active smoker and denied non-prescription drug use. Outpatient medications included ASA 325 mg PO q day, Clopidogrel 75 mg PO q day, Simvastatin 80 mg PO q day, Metoprolol 25 mg PO BID, Lisinopril 10 mg PO q day, Nitroglycerin 0.4 mg S/L prn, Spironolactone 12.5 mg PO BID, Glipizide 5 mg PO q day, Metformin 500 mg PO BID, Coumadin 5 mg PO q day and pantoprazole 40 mg PO q day. He denied allergies or intolerance to medications; in particular he reported no side effects when taking prn SL NTG. On presentation to our laboratory the blood pressure was 111/70 mm Hg in the right upper extremity, 115/70 mm Hg in left upper extremity, pulse 60 beats per minute, temperature 98 degree Fahrenheit, respiratory rate 14 per minute, pulse oximetry 92% on room air. Cardiovascular examination was normal. The EKG showed Q waves in leads V1 and V2 previously also noted on ECG nine months prior. Complete blood count and basic chemistries were normal. Total cholesterol 118 mg/dl, triglyceride 180 mg/dl, high density lipoprotein 25 mg/dl and low density lipoprotein 57 mg/dl. A recent echocardiogram demonstrated mid distal anterior and antero-septal wall hypokinesis and apical

akinesis. A pharmacologic myocardial perfusion stress test revealed reversible perfusion abnormality in the LAD territory. The diagnostic coronary angiogram performed at the referral hospital was reviewed and showed a widely patent proximal LAD stent and a mild severity mid lesion well beyond this stent and just distal to a moderate caliber diagonal branch. It was suspected that the mid LAD disease was contributing to his symptoms and abnormal nuclear stress test and he was sent to our cardiac catheterization laboratory for further evaluation and possible intervention.

Repeat left coronary angiography performed at our center using an 6 French XB 3.5 guide catheter (Cordis Corporation) revealed an ostial eccentric LAD lesion with 30% luminal narrowing, a widely patent proximal stent, and the aforementioned mid lesion beyond the second diagonal artery with 30-40% luminal narrowing (Figure 1 A).

To further assess the lesion and reference segments, NTG 400 mcg was given sublingually. Subsequent angiography performed 1, 3, and 5 minutes after NTG administration showed severe constriction at the site of the previously mild mid LAD lesion with no change in caliber of the remainder of the LAD. (Figure 1 B and C). There was no associated chest pain or electrocardiographic changes and mild decrease in central aortic pressure (Table 1). To further investigate with IVUS, a 0.014 Hi-Torque Floppy guide wire (Abbott Vascular) was placed distal to the lesion. At approximately 6 minutes following NTG, during passage of wire, the lesion appeared less stenotic, which was confirmed with cineangiography (Figure 1 D). At 10 minutes after NTG administration, a second dose of NTG, 200 micrograms,

***Corresponding author:** Yasmin S. Hamirani, Cardiology Fellow, Department of Cardiology, University of New Mexico, Albuquerque, NM, United states, Tel: 443-527-4766; E-mail: yasminshamshuddin@yahoo.com

Received August 20, 2010; **Accepted** September 17, 2010; **Published** September 17, 2010

Citation: Hamirani YS, Ricciardi MJ (2010) Coronary Spasm Associated with Nitroglycerin Administration – A Case Report and Review of the Literature. J Clin Exp Cardiol 1:103 doi:10.4172/2155-9880.1000103

Copyright: © 2010 Hamirani YS, et al. This is an open-access article distributed under the terms of the Creative Commons Attribution License, which permits unrestricted use, distribution, and reproduction in any medium, provided the original author and source are credited.



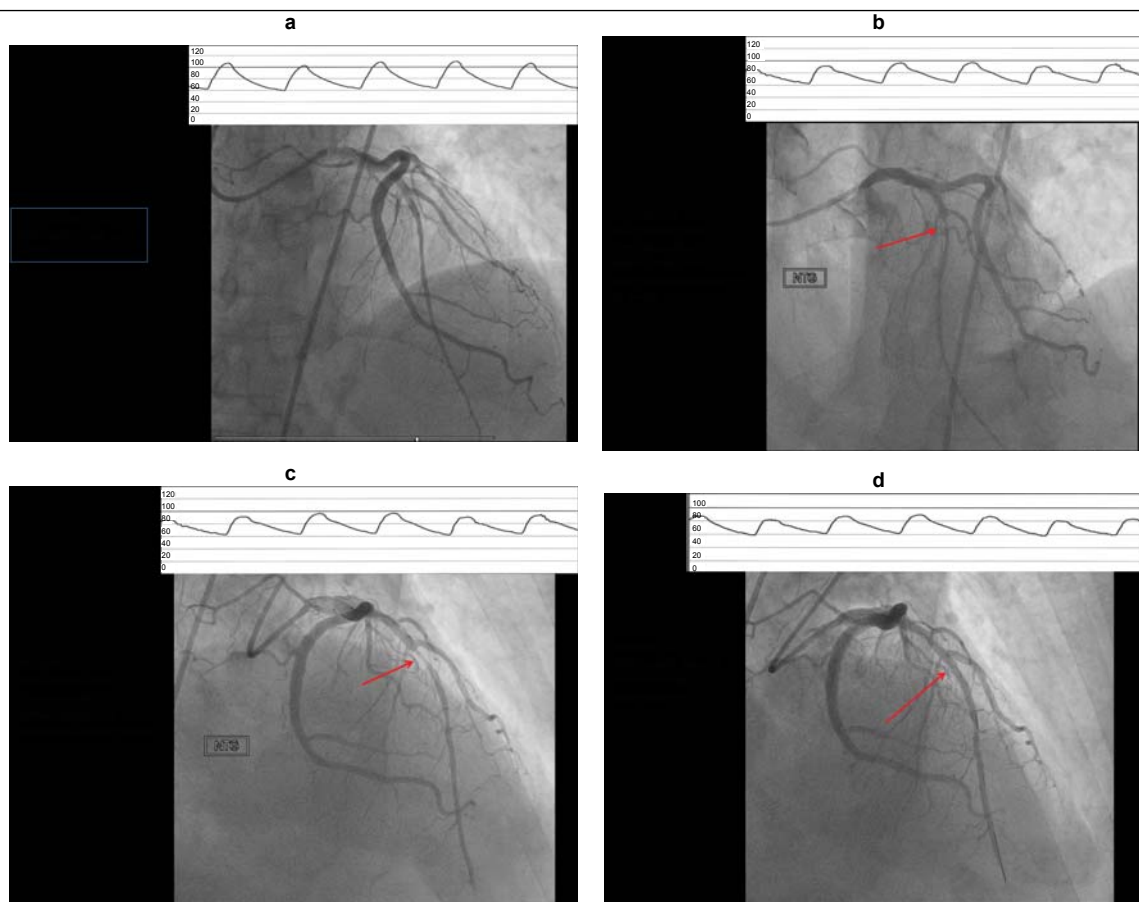


Figure 1: Coronary angiogram RAO and LAO views showing moderate disease of mid LAD (a), severe narrowing of the segment 5 minutes after sublingual NTG administration (b & c) and resolution of severe narrowing 10 minutes after s/l NTG at the time when wire was introduced into the left anterior descending artery for IVUS evaluation. (Aortic pressure (mm Hg) tracings at the time displayed at the top).

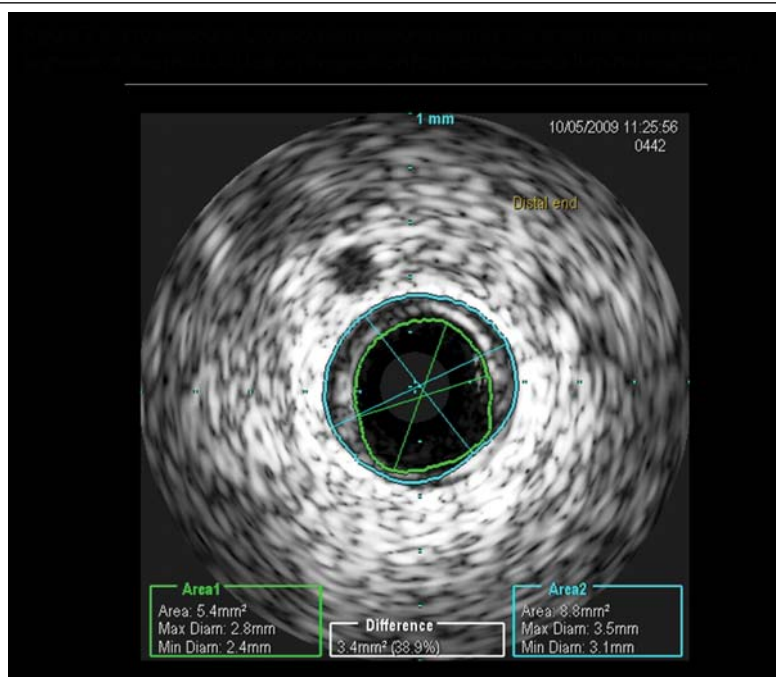


Figure 2: EKG and aortic pressures during coronary angiography in the beginning, after sublingual NTG and after 100 and 200 micrograms of NTG.

| SITE | SYSTOLIC BP | DIASTOLIC BP | MEAN | HEART RATE |
|---------------|-------------|--------------|----------|------------|
| INITIAL AORTA | 122 mm Hg | 67 mm Hg | 90 mm Hg | 59 mm Hg |
| FINAL AORTA | 99 mm Hg | 57 mm Hg | 75 mm Hg | 56 mm Hg |

Table 1: Initial and final aortic pressures and heart rate during coronary angiography (HR: heart rate, BP: Blood pressure).

intracoronary, was administered with no further dilation or spasm noted. IVUS (Volcano Therapeutics, Inc) of the mid LAD showed mild fibrofatty plaque with minimum luminal diameter of 1.9 mm, minimal luminal area of 2.9 mm²; proximal reference minimum luminal diameter and minimum luminal area were 2.4 mm and 5.4mm² respectively (Figure 2). No further interventions were performed. The patient denied chest pain throughout the procedure and EKG monitoring of leads I, III and AVL did showed no ST, T changes. At one year post angiography, the patient had no further cardiovascular events and had experienced no recurrent angina. His medication profile remained unchanged (Table 1).

Discussion

Organic nitrates cause relaxation of vascular smooth muscle producing a vasodilator effect on both peripheral arteries and veins with more prominent effects on the latter. Dilation of the post-capillary vessels promotes peripheral pooling of blood and decreases venous return to the heart, thereby reducing left ventricular end-diastolic pressure. By causing endothelial independent arteriolar smooth muscle relaxation, [3] NTG reduces systemic vascular resistance and arterial pressure. [4] In addition to its effect on arterial blood pressure, heart rate is usually slightly increased with NTG, presumably a reflex response to the fall in blood pressure. Effective coronary perfusion pressure is usually maintained, but can be compromised if blood pressure falls excessively or increased heart rate decreases diastolic filling time. Cardiac index may be increased, decreased, or unchanged. Patients with elevated left ventricular filling pressure and systemic vascular resistance values in conjunction with a depressed cardiac index are likely to experience an improvement in cardiac index. When filling pressures and cardiac index are normal, cardiac index may be slightly reduced. Although the mechanism for angina relief with NTG is incompletely understood, the most commonly accepted hypothesis is its effect on myocardial oxygen consumption and demand by both its arterial and venous effects. The extent to which epicardial coronary dilation contributes to the relief of angina is unclear [5,6].

NTG induced ST segment changes have been reported. Miller et al. [7] described a 57 year old patient with severe three vessel coronary artery disease who developed ST segment elevation in lead I 25 seconds after administration of intracoronary NTG. The ST elevation was potentiated after intravenous propranolol and returned to normal after 3 minutes. Coronary angiogram during ST elevation showed no significant change in epicardial coronary appearance. Prior to this, Dewar and Grimson [8] reported ST depression and angina after sublingual NTG.

Paradoxical NTG induced coronary spasm on coronary angiography has been rarely reported and appears to have been more common in the pre-Judkins era. In 1978, Feldman et al. [1] described two such cases. Both involved the proximal RCA using the Sones technique and were not associated with change in patient clinical status, blood pressure or ECG. Subsequently, coronary spasm following NTG administration using the Judkins technique has been reported in both the proximal RCA [9] and the left main artery [9,10]. Although great

care surely was used to rule out catheter irritation as a contributor to the witnessed vasospasm in all the reported cases, a common feature of all was involvement of the proximal vessel with expected vasodilatation of the remainder of the vessel, suggesting that the proximity of the catheter and its effect on the neighboring vascular endothelium may have played a role. Both spontaneous narrowing and mechanically induced coronary narrowing appear to occur more commonly in the right than in the left coronary artery [11]. Dynamic narrowing induced by a catheter or injection of contrast medium usually occurs at the site of the catheter tip in the proximal part of the coronary artery and is reversed with nitroglycerin [11]. To our knowledge, our case represents the first description of NTG-induced coronary spasm not involving the proximal vessel at a site distant from the catheter tip.

The mechanism by which NTG may cause coronary vasospasm is unclear. While a transient change in underlying vasomotor tone not related to the nitroglycerin administration may account for our finding, there are mechanistic data supporting a true causal relationship between NTG administration and coronary vasospasm. Ninomiya et al. [12] have shown that the percent increase in coronary blood flow and coronary artery diameter induced by acetylcholine (Ach) was significantly less in a group of patients taking chronic nitrates compared to a group on calcium antagonists. In addition, the percent diameter reduction in the region of greatest constrictive response to Ach was significantly greater in the nitrate group compared to the calcium antagonist group. Similarly, Caramori et al. [13] reported greater coronary constriction in response to Ach infusion in patients administered continuous transdermal NTG for 5 days prior to a diagnostic catheterization. Such findings suggest that nitrates may produce less favorable effects on coronary endothelial function in a subset of patients with normal or mildly diseased coronary arteries.

Advanced fibrocalcific changes secondary to inflammation could potentially impair an enhanced nitroglycerin effect in coronary arteries. Quyyumi et al. [14] have demonstrated in human coronary arteries that nitric oxide activity is decreased in patients with coronary risk factors. Itoh et al. [15] found hs CRP and smoking history to be independently associated with coronary spasm using intracoronary Ach. The dilator response to nitroglycerin is shown to decrease independently with increasing age. Both decreased sensitivity of the aging vascular smooth muscle cells and physical abnormality in the aging vessel, including calcification, may prevent dilation [16,17]. The vasodilator response to the smooth muscle relaxant papaverine has also been shown to decrease with increasing age in a group of patients with normal coronary arteries [18]. Myocardial bridge can also lead to localized coronary artery narrowing at the bridged segment during systole while during the diastolic phase, no such contraction is seen. This was not observed in our patient.

Conclusion

Nitroglycerin is a commonly used coronary vasodilator in the cardiac catheterization laboratory. While paradoxical response to NTG has been reported in the proximal coronary artery, we report the first case of vasospasm involving the mid coronary artery after NTG administration.

References

1. Feldman RL, Pepine CJ, Conti CR (1978) Unusual vasomotor coronary arterial responses after nitroglycerin. *Am J Cardiol* 42: 517-519.
2. Phlaum SR, Kern MJ (2000) Paradoxical hypertensive response to Nitroglycerin during Cardiac Catheterization. *Catheter Cardiovasc Interv* 51: 490-493.



3. Harrison DG, Bates JN (1993) The nitrovasodilators. New ideas about old drugs. *Circulation* 87: 1461-1467.
4. Garadah T, Ghaisas NK, Mehana N, Foley B, Crean P, et al. (1998) Impact of intravenous nitroglycerin on pulsed Doppler indexes of left ventricular filling in acute anterior myocardial infarction. *Am Heart J* 136: 812-817.
5. Fam WM, McGregor M (1968) Effect of nitroglycerin and Dipyridamole on regional coronary resistance. *Circ Res* 22: 649-659.
6. Winbury MM, Howe BB, Hefner MA (1969) Effect of nitrates and other coronary dilators on large and small coronary vessels: an hypothesis for the mechanism of action of nitrates. *J Pharmacol Exp Ther* 168: 70-95.
7. Miller JT, Henry RL, Kern MJ (1986) Potentiation of nitroglycerin-induced ST segment elevation by beta-adrenergic blockade. *Am Heart J* 112: 839-841.
8. Dewar HA, Grimson TA (1950) Khellin in the treatment of angina of effort. *Br heart J* 12: 54-60.
9. Curry RC (1980) Coronary vasoconstriction following nitroglycerin. *Cathet Cardiovasc Diagn* 6: 211-212.
10. Dalal JJ, McCans JL, Parker JO (1984) Nitroglycerin-induced coronary vasoconstriction. *Cathet Cardiovasc Diagn* 10: 33-36.
11. Gensini GG (1975) *Coronary Arteriography*. New York, Futura Publishing 420-435.
12. Ninomiya Y, Hamasaki S, Saihara K, Ishida S, Kataoka T, et al. (2008) Comparison of effect between nitrates and calcium channel antagonist on vascular function in patients with normal or mildly diseased coronary arteries. *Heart Vessels* 23: 83-90.
13. Caramori PR, Adelman AG, Azevedo ER, Newton GE, Parker AB, et al. (1998) Therapy with nitroglycerin increases coronary vasoconstriction in response to acetylcholine. *J Am Coll Cardiol* 32: 1969-1974.
14. Quyyumi AA, Dakak N, Andrews NP, Husain S, Arora S, et al. (1995) Nitric oxide activity in human coronary circulation: impact of risk factors for coronary atherosclerosis. *J Clin Invest* 95: 1747-1755.
15. Itoh T, Mizuno Y, Harada E, Yoshimura M, Ogawa H, et al. (2007) Coronary spasm is associated with chronic low-grade inflammation. *Circ J* 71: 1074-1078.
16. Egashira K, Inou T, Hirooka Y, Kai H, Sugimachi M, et al. (1993) Effects of age on endothelium dependent vasodilation of resistance coronary artery by acetylcholine in humans. *Circulation* 84: 77-81.
17. Zeiher AM, Drexler H, Saurbier B, Just H (1993) Endothelium-mediated coronary blood flow modulation in humans: effects of age, atherosclerosis, hypercholesterolemia and hypertension. *J Clin Invest* 92: 652-662.
18. Liao JK, Bettmann MA, Sandor T, Tucker JI, Coleman SM, et al. (1991) Differential impairment of vasodilator responsiveness of peripheral resistance and conduit vessels in humans with atherosclerosis. *Circ Res* 68: 1027-1034.