

Convulsive Seizures Revealing-A Caseous Calcification of the Mitral Annulus (CCMA): A Case Report

Mingou JS^{1*}, Zabalawi A², Plurien F², Delaunay R², Payot L² and Moquet B²

¹Teaching Hospital Aristide Le Dantec, Dakar, Senegal

²Yves Le Foll Hospital in Saint Brieuc, France

Abstract

Caseous necrosis of the mitral valve ring is a process that is all the more frequently encountered as life expectancy is increased, often by accidental discovery, and is considered as a benign condition, with the responsibility for the clinical symptoms leading to its discovery remains difficult. Through this clinical case, we rediscover the clinical polymorphism of this pathology, the diagnosis of which has been confirmed by the CT scan.

Keywords: Caseous necrosis; Stroke; Cardiovascular risk

Introduction

Mitral annular calcification (MAC) is a marker of generalized atherosclerosis that emphasizes its predictive character of coronary or carotid involvement [1,2]. The calcification of the mitral valve ring is a degenerative process that is all the more frequently encountered as life expectancy is increased. This process usually takes place in the insertion zone of the posterior mitral leaflet, suggesting the role of mechanical stresses at this level, sometimes aggravated by chronic pressure overload (high blood pressure, aortic stenosis), abnormal mitral movements (prolapse, obstructive cardiomyopathy with SAM), or repeated microtrauma (ballprosthesis) [3]. Anomalies of phosphocalcic metabolism, as found in chronic kidney failure, also represent an additional risk factor. Anatomically, the infiltration of the mitral valve ring can vary from simple small calcareous nodules to the total ossification of the ring with always a clear posterior predominance.

In Framingham's study after adjusting for all risk factors (age, sex, high blood pressure, diabetes, tobacco, coronary artery disease, heart failure, atrial fibrillation, left atrium size); There is a 2-fold increase in the risk of stroke in cases of calcification of the mitral ring.

We report the clinical observation of a 65-year-old patient with a notion of familial asthma since childhood, with benign prostatic hypertrophy, arterial disease of the lower limbs stage 2 unexplored, Psoriasis and ischemic heart disease since 2012 with two stents (common and circumflex) and a history of epilepsy for one year under lamictal on left encephalo-meningocele with diffuse vascular lesions and narrow lumbar surgery. He has an alcohol consumption of 6 glasses per day. The patient was admitted to the emergency department for seizures revealing a semi-recent ischemic stroke on MRI. The biological check-up was normal. The electrocardiogram (ECG) recorded a sinus rhythm, without disturbance of rhythm or conduction, correct repolarization.

Cardiac ultra sound coupled with trans esophageal ultrasound revealed a voluminous, hyper echoic round mass of homogeneous tissue-like shape with 13 × 12 net contours in the posterior-lateral mitral leaflet compared to P2 without associated mitral valve disease. The electroencephalogram was normal. The Doppler of supra-aortic trunks noted diffuse non-steno sing atherosclerosis of the carotid arteries. The cardiac scan confirms this hypo dense mass partially calcified in favor of a caseous necrosis of the mitral valve ring, without evolution on the coronary network with permeable stents.

Discussion

Caseous calcification of the mitral annulus (CCMA) is often fortuitous discovery; the revealing symptoms are often unrelated. In a series of Harpaz [4], we find 26% revealed by a stroke so far there has not been a correlation between the stroke and the CCMA. Other symptoms such as dyspnea and palpitations [5] or a much more frustrated picture such as acute lung edema; were revealing of the pathology. The cardiac echocardiography, more or less coupled with ETO, being the first examinations to evoke this diagnosis, it is a rounded mass, echogenic with regular contours, in the heterogeneous center, sitting almost exclusively at the level of The posterior mitral ring until then no seat on the anterior ring has been described, mobile mass synchronized with the movements of the posterior mitral leaflet [4,5]. The cardiac CT makes it possible to confirm this diagnosis and to eliminate differential diagnoses, the CCMA being a more or less calcified mass at the periphery with a spontaneously dense center sign of central venous necrosis appended to the posterior mitral ring. MRI can confirm the diagnosis of CCMA, caseous necrosis is an amorphous, non-vascularized substance and therefore devoid of protons and magnetic signal. It thus appears in hypo signal on the sequences weighted in T1 and in T2 [6]. The prognosis of CCMA is considered good, hence simple monitoring is recommended, as surgery is reserved for patients with severe mitral impairment and in whom the diagnosis is not certain in order to eliminate any potentially serious differential diagnosis (Post-traumatic calcified myocardial hematoma, primary or secondary tumors, infectious abscesses and thrombi). One of the main differential diagnoses is post traumatic calcified myocardial hematoma. Myocardial contusions are the most common cardiac lesions in closed chest trauma. The main providers of thoracic trauma are road traffic accidents, which are responsible for direct shock, organ compression in the chest, abrupt deceleration, or indirect increase in intra-thoracic pressures by abdominal compression (Figures 1-3).

*Corresponding author: Mingou JS, Teaching Hospital Aristide Le Dantec, Dakar, Senegal, Tel: 00221775365985; E-mail: mingoujoseph@gmail.com

Received March 13, 2017; Accepted April 13, 2017; Published April 15, 2017

Citation: Mingou JS, Zabalawi A, Plurien F, Delaunay R, Payot L, et al. (2017) Convulsive Seizures Revealing-A Caseous Calcification of the Mitral Annulus (CCMA): A Case Report. J Clin Exp Cardiol 8: 512. doi:10.4172/2155-9880.1000512

Copyright: © 2017 Mingou JS, et al. This is an open-access article distributed under the terms of the Creative Commons Attribution License, which permits unrestricted use, distribution, and reproduction in any medium, provided the original author and source are credited.

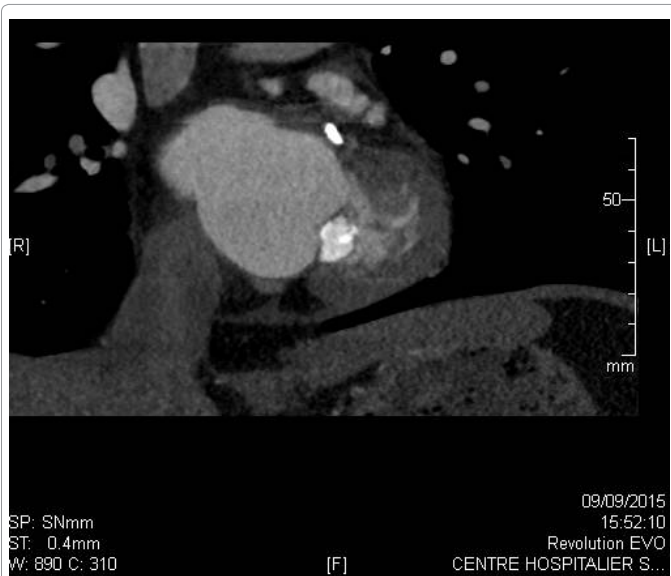

Figure 1: Cups of spiral cardiac computed tomography after injection of contrast agent.

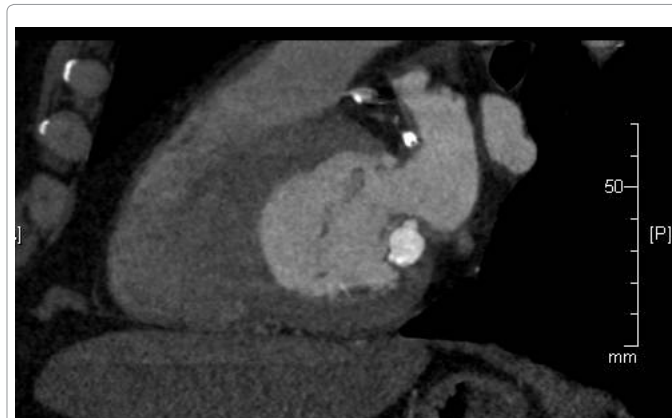


Figure 3: Slices of cardiac spiral computed tomography after injection of contrast agent; Rounded mass with regular contours and the hypo-dense center developed in the posterior mitral annulus at the intra ventricular septum.

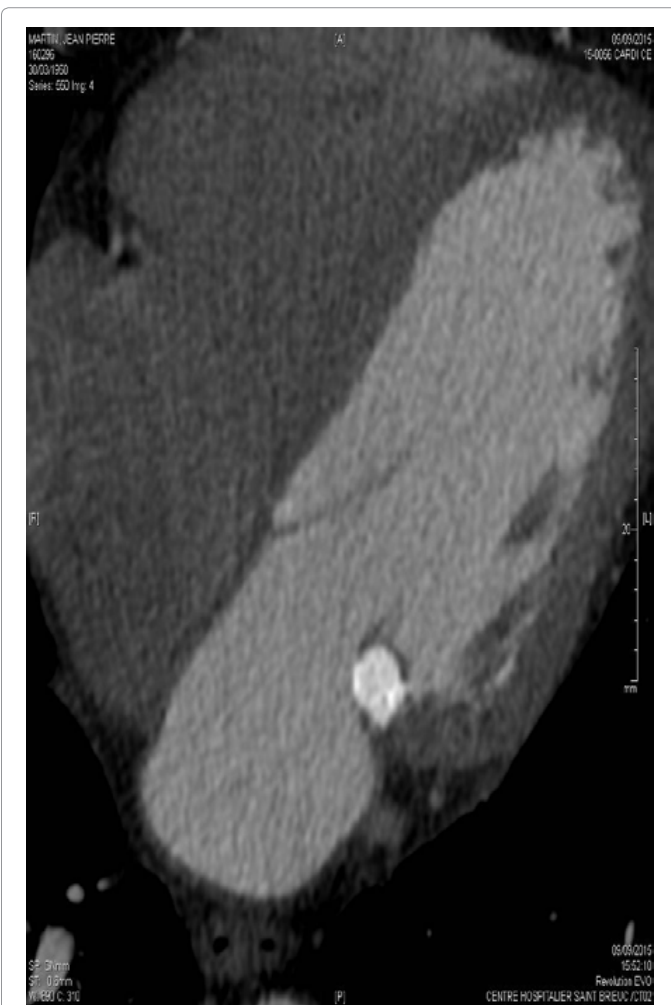


Figure 2: Rounded mass with regular contours at the hypo dense center developed at the posterior mitral ring at the level of ventricular groove.

The heart is also exposed in falls from a high place or in sports accidents [7]. The myocardium is injured when the sternum strikes the heart mass or crushes it against the dorsal spine. During brutal decelerations, the heart violently strikes the sternum.

The association of a myocardial hematoma with myocardial contusion is exceptionally described [7-9]. This is a rare complication of myocardial contusions which should not be underestimated as it is potentially dangerous in the short or medium term. In the long term, the myocardial hematoma becomes engrafted and liquefied. Its wall is calcified. Then appears a calcified mass or cyst. Echocardiography shows a mass with a hyper echoic wall attenuating the ultrasound beam. The cardiac MRI revealed an intra-myocardial mass of variable signal in weightings T1 and T2 according to the importance of the calcified shell. This is not enhanced after injection of gadolinium. CT objectifies the calcified nature of the mass. The acquisition after iodine injection and cardiac rhythm synchronization shows a calcified mass embedded in the ventricular myocardium. In addition, CT scan is used to look for sequelae of an old chest trauma: costal fractures, pericardial calcifications, lung lesions [10-13].

The diagnosis of post-traumatic calcified myocardial hematoma is not easy. Traumatic myocardial hematomas are exceptional and sometimes unrecognized. They can be accidentally discovered several years after the initial trauma, at the calcified stage. In the acute stage, surgical management of the myocardial hematoma is essential; In the chronic, calcified stage, a surgical gesture seems unjustified.

In our case we cannot retain this diagnosis because our patient did not have a history of thoracic trauma.

Regarding the management of the CCAM we wanted to discuss surgery given the context of stroke although there is a significant operative risk in the face of the numerous comorbidities of our patient (Euro high score).

Conclusion

The discovery of CCAM should not be anecdotal but should be considered as evidence of a high cardiovascular risk. The echocardiographic aspect deserves to be known and a trans esophageal ultrasound should be performed in case of suspicion of complication to the type of thrombosis or endocarditis. The CT is the gold standard to confirm the diagnosis.

References

1. Adler Y, Herr I, Vature M (1998) Mitral annular calcium detected by transthoracic echocardiography is a marker for high prevalence and severity of coronary artery disease in patients Undergoing coronary angiography. *Am J Cardiol* 82: 183-186.
2. Benjamin EJ, Plehn JF, D'Agostino RB, Belanger AJ, Comai K, et al. (1992) Mitral annular calcification and the risk of stroke in an elderly cohort. *N Engl J Med* 327: 374-379.
3. PK Fulkerson, Beaver BM, Auseon JC (1979) Calcification of the mitral annulus. Etiology, clinical associations, complications and therapy. *Am J Med* 66: 967-977.
4. Harpaz D, Auerbach I, Vered Z, Motro M, Tobar A, et al. (2001) Caseous calcification of the mitral annulus: a neglected, unrecognized diagnosis. *J Am Soc Echocardiogr* 14: 825-831.
5. Deluca G, Correale M, Ieva R, Del Salvatore B, Gramenzi S, et al. (2008) The incidence and clinical course of caseous calcification of the mitral annulus: a prospective echocardiographic study. *J Am Soc Echocardiogr* 21: 828-833.
6. Gulati A, Chan C, Duncan A, Raza S, Kilner PJ, et al. (2011) Multimodality cardiac imaging in the evaluation of mitral annular caseous calcification. *Circulation* 123: e1-2.
7. Roynard JL, Fosse JP, Cohen Y, Artigou JY, Hoang P, (1995) Left atrial contusion with intramyocardial hematoma after a blunt chest trauma. *Intensive Care Med* 21: 384-385.
8. Traversat J, JF Laine, Slama M (1986) Cardiac contusion with dissecting hematoma of the apex of the heart and interventricular communication. *Arch Mal Coeur Vaiss* 79: 1105-1109.
9. Descat E, Montaudon M, Latrabe V, Surcin B, Morales P, et al. (2002) MR imaging of myocardial haematoma after blunt chest injury. *Eur Radiol* 12 Suppl 3: S174-176.
10. Skov SN, Røpcke DM, Tjørnild MJ, Ilkjær C, Rasmussen J, et al. (2017) The effect of different mitral annuloplasty rings on valve geometry and annular stress distribution. *Interact Cardiovasc Thorac Surg*.
11. Wakaskar RR, Bathena SP, Tallapaka SB, Ambardekar VV, Gautam N, et al. (2015) Peripherally cross-linking the shell of core-shell polymer micelles decreases premature release of physically loaded combretastatin A4 in whole blood and increases its mean residence time and subsequent potency against primary murine breast tumors after IV administration. *Pharm Res* 32: 1028-1044.
12. Ambardekar VV, Wakaskar RR, Sharma B, Bowman J, Vayaboury W, et al. (2013) The efficacy of nuclease-resistant Chol-siRNA in primary breast tumors following complexation with PLL-PEG(5K). *Biomaterials* 34: 4839-4848.
13. Furukawa H, Tamura T, Honda T, Takiuchi H, Kuinose M, et al. (2016) Simple Interrupted Suturing for Redo Mitral Valve Replacement. *J Heart Valve Dis* 25: 685-690.