

Conversion to Steroid-Responsiveness in a Patient with Motor-Dominant Chronic Inflammatory Demyelinating Polyneuropathy

Kataoka H*, Kobayashi Y, Terashima M, Sugie K and Ueno S

Department of Neurology, Nara Medical University, Kashihara, Nara, Japan

Abstract

The subtypes of chronic inflammatory demyelinating polyneuropathy (CIDP) differ in clinical presentation, electrophysiological and laboratory features, and response to treatment. Steroid therapy is now accepted as a first- or second-line treatment for CIDP. Patients with steroid-resistant CIDP have been reported, especially among those with pure-motor or motor-dominant CIDP. The clinical and prognostic features of patients with motor dominant CIDP are poorly understood. We describe a patient with steroid-unresponsive motor dominant CIDP who subsequently responded to steroid therapy and review previously reported patients with motor dominant CIDP. Most patients with motor-dominant CIDP did not respond to steroids, but remarkably improved after treatment with intravenous immunoglobulins. Our findings suggest that some patients with steroid-unresponsive motor-dominant CIDP can subsequently become responsive to steroid therapy.

Keywords: CIDP; Demyelinating neuropathy; Steroid; Motor form; Motor dominant; Pure motor

Introduction

Chronic inflammatory demyelinating polyneuropathy (CIDP) is considered an immune-mediated disorder because it responds to immunotherapy. Steroid therapy is now accepted as a first- or second-line treatment for CIDP. Treatment often begins with daily oral prednisone in a high daily dose of up to 1 mg/kg, which is then slowly tapered [1,2]. Pulsed therapy with intravenous steroids is also effective [1,2]. Patients with steroid-resistant CIDP have been reported, especially in pure-motor or motor-dominant CIDP [3,4]. Such patients require other types of immunotherapy, such as intravenous immunoglobulins (IVIG), plasma exchange, or immunosuppressive agents. However, such treatments are expensive and can cause serious adverse effects such as cerebral or cardiac infarction or renal failure. We describe a patient with steroid-unresponsive motor dominant CIDP who subsequently responded to steroid therapy.

Case Report

In the middle of June 2006, a 58-year-old woman who had undergone a Billroth II gastrectomy for early gastric cancer 1 year previously had difficulty in handling a kitchen knife and placing clothespins on clothes. At the end of June, she noticed difficulty in elevating the upper limbs and in walking. In July, she required assistance in daily activities and presented at our hospital. Symmetrical muscle weakness was evident in all four limbs, and the patient could not stand. Vibratory sensation was mildly disturbed in the lower limbs, but superficial sensations were preserved, with no sensory symptoms. The deep tendon reflexes were absent in all four limbs, with no pathological reflex. There was no ataxia on either side. Cranial nerves and autonomic function were not impaired. The results of routine laboratory blood tests were normal. The results of tests for anti-ganglioside antibodies including anti-GM1 antibodies, monoclonal gammopathy, and various antibodies associated with immune disorders, such as antinuclear cytoplasmic autoantibodies, were negative. Serum concentrations of folic acid, vitamin B12, and vitamin B1 were not lower than the respective lower limits of normal. Cerebrospinal fluid analysis showed 5 (normal lower limit: 5) lymphocytes and a protein concentration of 175 (normal upper limit: 45) mg/dl. The results of contrast-enhanced cervical, thoracic, and lumbar magnetic resonance imaging (MRI) were normal. Motor

nerve conduction studies of the left median, ulnar, peroneal, and tibial nerves showed reduced conduction velocities (30.5 m/s, normal lower limit: 53; 24.9 m/s, normal lower limit: 51; 38.1 m/s, normal lower limit: 42, and 30.8 m/s, normal lower limit: 43.2, respectively) and reduced amplitudes (7.61 mV, normal lower limit: 9.9; 4.58 mV, normal lower limit: 9.5; 2.61 mV, normal lower limit: 4.8; and 8.55 mV, normal lower limit: 9.3, respectively). Distal motor latencies of the left median (4.68 ms, normal upper limit: 3.9), ulnar (4.26 ms, normal upper limit: 3.4), peroneal (7.23 ms, normal upper limit: 5.6), and tibial nerves (6.09 ms, normal upper limit: 4.5) were prolonged. Temporal dispersion and conduction block were evident in the median, ulnar, and tibial nerves (Figure 1). F-wave latencies of the median, ulnar, peroneal, and tibial nerves were absent. Sural, median, and ulnar sensory nerve action potentials were normal; the amplitudes of the action potentials were also normal. At the end of July, she received IVIG (400 mg/kg/day, 5 days) for a suspected diagnosis of demyelinating neuropathy (day 1 in the Figure 2). The effects of treatments were quantified using the neuropathy impairment score [5] as shown in the Figure 2. The severity of disease decreased transiently, but increased again on day 15. Biopsy of the sural nerve showed a marginal reduction in myelin thickness, with no fibrinoid necrosis, inflammatory cell infiltration, or granuloma (Figure 1). CIDP was diagnosed. Intravenous methylprednisolone pulse therapy (1 g/day, 3 days) and oral prednisolone (30 mg) were started on day 29, but the severity of disease intensified. After two courses of IVIG treatment, the disease severity decreased, and the dose of prednisolone (50 mg, 1 mg/kg) was increased. However, motor weakness developed. During immunosuppressive therapy, CIDP recurred. On day 1084, the patient was given two courses of pulse therapy with intravenous

*Corresponding author: Hiroshi Kataoka, Department of Neurology, Nara Medical University, 840 Shijo-cho, Kashihara, Nara 634-8522, Japan, Te: +81-744-29-8860; Fax: +81-744-24-6065; E-mail: hk55@naramed-u.ac.jp

Received July 25, 2013; Accepted August 06, 2013; Published August 08, 2013

Citation: Kataoka H, Kobayashi Y, Terashima M, Sugie K, Ueno S (2013) Conversion to Steroid-Responsiveness in a Patient with Motor-Dominant Chronic Inflammatory Demyelinating Polyneuropathy. J Genet Syndr Gene Ther 4: 166. doi:[10.4172/2157-7412.1000166](https://doi.org/10.4172/2157-7412.1000166)

Copyright: © 2013 Kataoka H, et al. This is an open-access article distributed under the terms of the Creative Commons Attribution License, which permits unrestricted use, distribution, and reproduction in any medium, provided the original author and source are credited.

methylprednisolone, and the severity of disease decreased. After IVIG treatment, oral prednisolone was continued, with no further recurrence (Figure 2). During the disease course, sensory nerve functions on nine sensory nerve conduction studies were preserved as compared with the results of the initial nerve conduction study, and cervical MRI revealed enlargement of the spinal roots and brachial plexus. In April 2012, the dose of oral prednisolone was gradually reduced, regardless of whether the patient was in complete remission or not. The neuropathy score increased from 30 in April 2012 during treatment with prednisolone 5 mg/day to 46 in August (prednisolone 4 mg/day) and 51 in October (prednisolone 3 mg/day). In June 2013, she received oral prednisolone

(2 mg/day), and the neuropathy score was 52. Deep tendon reflexes were absent in all four limbs. Sensorial impairment was absent, with no sensorial symptoms.

Discussion

Most patients who initially have steroid-unresponsive CIDP subsequently respond to steroids. During remission after acute relapse in our patient, muscle strength was regained in association with a decrease in the dose of steroids. Thus, we believe that our patient had altered steroid-responsiveness. Multifocal motor neuropathy (MMN) is an uncommon idiopathic syndrome characterized by asymmetric lower weakness [6]. Clinically, the disease course usually progresses slowly, but can progress in a stepwise fashion [6]. Our patient had bilateral and symmetric weakness of the upper and lower limbs, associated with a relapsing-remitting course and negativity for anti-GM1 antibodies. Thus, the characteristics of our patient with motor-dominant CIDP differed from those associated with MMN.

Sabatelli et al. described four patients who had a pure motor form of CIDP with a relapsing-remitting course, as shown in the Table 1 (Patients 1 to 4) [3]. Recently, Kimura et al. reported on five patients (Patients 5 to 9 in the Table 1) with motor-dominant CIDP [4]. Since our patient showed mild abnormal findings on sural nerve biopsy, we gave the patient a diagnosis of “motor-dominant CIDP”. We considered the pathogenesis of pure-motor CIDP to be similar to that of motor-dominant CIDP. The 9 previously reported patients with motor-dominant CIDP did not respond to steroids and showed clinical remission after IVIG infusion during the acute relapsing phase (Table 1) [3,4]. Electrophysiological examinations in these patients demonstrated that sensory nerve function was well preserved. Rajabally et al. reported on seven steroid-unresponsive patients with sensory-motor CIDP and proposed that a higher mean-sensory-nerve action potential was an electrophysiological predictor of steroid-unresponsive CIDP [7]. Our patient was also free of sensory symptoms and had normal findings on repeated sensory conduction studies and minimal abnormal findings on sural nerve biopsy. These findings are consistent with previous observations of steroid-resistant CIDP with relatively well-preserved sensory function. Moreover, most lesions in patients with motor-dominant CIDP involve the cervical nerve roots and brachial plexus, similar to our patient [4].

None of the previously described patients with motor-dominant CIDP responded to treatment with steroids during the acute phase of relapse. Whether steroid-responsiveness developed is not mentioned for most of these patients [3,4]. Refractoriness to steroids raises the possibility of a peculiar immunologic mechanism underlying this condition. The mechanism of action of steroids is complex and most likely involves multiple effects caused by activation of the glucocorticoid receptor [8]. The receptor binds to glucocorticoid-responsive elements located in the premotor regions of specific genes or to other nuclear transcription factors and can activate or inhibit gene transcription [8]. It remains unclear whether potential causes of altered steroid responsiveness, such as immunosuppressive agents and repeated IVIG treatment, affect host-immune-mediated conditions or if genetic factors or the natural course of steroid-unresponsive CIDP is involved. Similar to our patient, two patients (Patients 5 and 7) treated with only prednisolone has remained in remission for about 2 years after the acute relapsing phase (Table 1) [4]. We could not find a difference between patients with and those without altered steroid-responsiveness, but a patient with motor-dominant CIDP can respond to steroids after acute relapse.

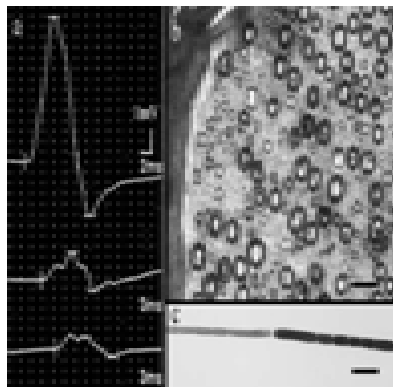


Figure 1: Panel a: Motor nerve conduction studies of the median nerve showed temporal dispersion and conduction block. Panel b: Light microscopic findings of sural nerve specimens stained with toluidine blue. Fibers with remyelination were associated with a slight decrease in myelinated fibers. Axonal degeneration with myelin ovoids was not evident. Panel c: Teased nerve analysis showing segmental demyelination. Myelinated fibers with axonal degeneration were not found. Bars a 15 μ m, b 30 μ m.

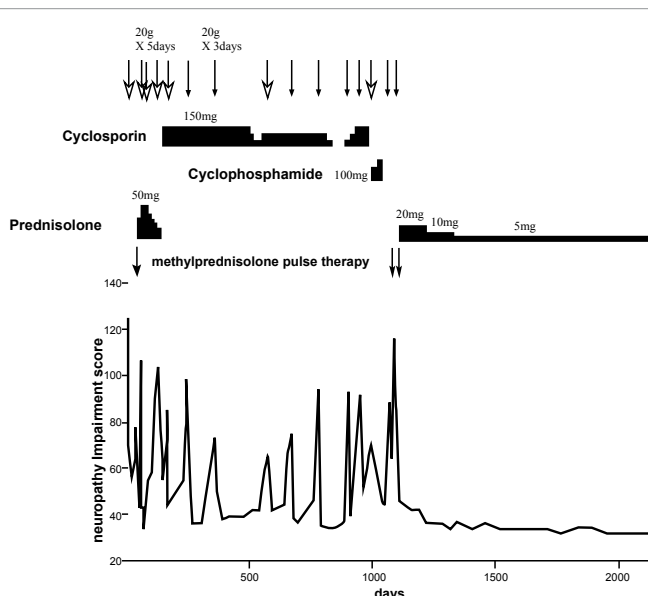


Figure 2: Clinical course of the patient. Day 1 is the day of starting intravenous immunoglobulin therapy. The neuropathy impairment score was based on a report by Dyck et al. [5] and was derived by summing the scores for cranial nerve impairment, muscle weakness, deep tendon reflex impairment, and sensory impairment. The degree of impairment was evaluated according to a 5-grade scale as follows: 0, no deficit; 1, mild deficit; 2, moderate deficit; 3, severe deficit; and 4, complete absence of function or severest deficit.

	Patient 1 ^{ref.3}	Patient 2 ^{ref.3}	Patient 3 ^{ref.3}	Patient 4 ^{ref.3}	Patient 5 ^{ref.4}	Patient 6 ^{ref.4}	Patient 7 ^{ref.4}	Patient 8 ^{ref.4}	Patient 9 ^{ref.4}	Present patient
age/sex	24/M	37/F	33/F	11/M	66/F	62/M	50/F	50/M	46/M	65/F
disease duration (years)	12	12	4	8	3	3	5	1	2	7
clinical course	relapsing	relapsing	relapsing	relapsing	relapsing	relapsing	relapsing	relapsing	relapsing	relapsing
number of relapses	45	10	7	15	5	4	7	4	9	14
paresthesia	-	-	-	-	finger	-	-	finger	finger	-
CSF proteins (mg/dl)	123	60	70	96	42	86	98	113	145	175
sensory conduction velocity										
sural nerve (m/sec)	44	54	43	52	39.4 ^a	42.3 ^a	46.2	52.6	42.7	48.6
other sensory nerves	normal	normal	normal	normal	normal	normal	normal	normal	normal	normal
sural nerve biopsy	normal	normal	normal	-	mild abnormal	mild abnormal	-	-	-	mild abnormal
Response to therapies										
corticosteroids (ST)	No	No	No	No	No	No	No	No	No	No
IVIG	Yes	Yes	Yes	Yes	Yes	Yes	Yes	Yes	Yes	Yes
plasma exchange (PE)	Yes	Yes	-	Yes	-	-	done ^b	-	-	-
cyclosporin A	-	-	-	No	-	-	-	done ^b	-	No
cyclophosphamide	-	-	-	-	-	-	-	-	done ^b	No
azathioprine	Yes	No	No	No	-	-	-	-	done ^b	-
interferon alpha	-	Yes	-	Yes	-	-	-	-	-	-
Outcome										
entered remission	Yes	Yes	Yes	Yes	Yes	Yes	Yes	No	No	Yes
therapy during remission	azathioprine, PE	interferon alpha	IVIG	-	ST	-	ST	ST	ST	ST
remission periods (years)	3	1	1	7	1.8	1.5	1.3	-	-	4
CSF: cerebrospinal fluid, IVIG: intravenous immunoglobulin, M: male, F: female										
^a : authors suggested that sensory nerve conduction slowing was caused by diabetes mellitus.										
^b : the therapy was performed, but the effectiveness was not mentioned.										

Table 1: Clinical features of reported patients with motor-dominant chronic inflammatory demyelinating polyneuropathy.

All patients with motor dominant CIDP showed clinical remission after IVIG treatment during the acute relapsing phase (Table 1) [3,4]. IVIG treatment is considered an initial treatment for motor dominant CIDP by the European Federation of Neurological Societies/Peripheral Nerve Society guidelines [9], but IVIG treatment is expensive, and the duration of effectiveness is sometimes short, as in our patient.

Conclusions

The subtypes of CIDP differ in clinical presentation, electrophysiological and laboratory features, and response to treatment. The clinical features and prognostic features of patients with motor dominant CIDP are poorly understood. Most patients with motor-dominant CIDP did not respond to steroids, but remarkably improved after treatment with IVIG. Our findings suggest that some patients with steroid-unresponsive motor-dominant CIDP can subsequently become responsive to steroid therapy.

References

- Dalakas MC, Engel WK (1981) Chronic relapsing (dysimmune) polyneuropathy: pathogenesis and treatment. *Ann Neurol* 9 Suppl: 134-145.
- Lopate G, Pestronk A, Al-Lozi M (2005) Treatment of chronic inflammatory

demyelinating polyneuropathy with high-dose intermittent intravenous methylprednisolone. *Arch Neurol* 62: 249-254.

- Sabatelli M, Madia F, Mignogna T, Lippi G, Quaranta L, et al. (2001) Pure motor chronic inflammatory demyelinating polyneuropathy. *J Neurol* 248: 772-777.
- Kimura A, Sakurai T, Koumura A, Yamada M, Hayashi Y, et al. (2010) Motor-dominant chronic inflammatory demyelinating polyneuropathy. *J Neurol* 257: 621-629.
- Dyck PJ, O'Brien PC, Oviatt KF, Dinapoli RP, Daube JR, et al. (1982) Prednisone improves chronic inflammatory demyelinating polyradiculoneuropathy more than no treatment. *Ann Neurol* 11: 136-41.
- Nobile-Orazio E (1996) Multifocal motor neuropathy. *J Neurol Neurosurg Psychiatry* 60: 599-603.
- Rajabally YA, Narasimhan M, Chavada G (2008) Electrophysiological predictors of steroid-responsiveness in chronic inflammatory demyelinating polyneuropathy. *J Neurol* 255: 936-938.
- Leung DY, Bloom JW (2003) Update on glucocorticoid action and resistance. *J Allergy Clin Immunol* 111: 3-22.
- Hughes RA, Bouche P, Cornblath DR, Evers E, Hadden RD, et al. (2006) European Federation of Neurological Societies/Peripheral Nerve Society guideline on management of chronic inflammatory demyelinating polyradiculoneuropathy: report of a joint task force of the European Federation of Neurological Societies and the Peripheral Nerve Society. *Eur J Neurol* 13: 326-32.

This article was originally published in a special issue, [Autoimmune Diseases](#) handled by Editor(s). Dr. Kenneth Blum, University of Florida, USA