

Complications of Endovascular Management of Isolated Internal Iliac Artery Aneurysm

Ben Jmaà Hèla^{1*}, Jmal Hassen¹, Cheikhrouhou Hichem², Maalej Aiman³, Elleuch Nizar¹, Masmoudi Sayda¹ and Frikha Imed¹

¹Department of Cardiovascular and Thoracic Surgery, Habib Bourguiba Hospital, Sfax, Tunisia

²Department of Anesthesiology, Habib Bourguiba Hospital, Sfax, Tunisia

³Department of Radiology, Habib Bourguiba Hospital, Sfax, Tunisia

*Corresponding author: Ben Jmaà Hèla, Department of Cardiovascular and Thoracic Surgery, Habib Bourguiba Hospital, Sfax, Tunisia, Tel: 0021696704740; E-mail: helabenjemaa2015@gmail.com

Received date: June 10, 2017; Accepted date: July 07, 2017; Published date: July 11, 2017

Copyright: © 2017 Hèla BJ, et al. This is an open-access article distributed under the terms of the Creative Commons Attribution License, which permits unrestricted use, distribution, and reproduction in any medium, provided the original author and source are credited.

Abstract

The isolated internal iliac artery aneurysm is rare, but can be fatal if non-diagnosed. Endovascular treatment of these aneurysms, ideally with exclusion of the sac from antegrade and retrograde perfusion, provides a minimally invasive alternative that avoids the direct operative morbidity.

We present a case of a patient treated with embolization with coils of an aneurysm of the left internal iliac artery. Then, 6 months after the procedure, the patient suffered from recurrence of abdominal pain. CT scan confirmed patency of the aneurysmal sac. Therefore, he underwent second endovascular exclusion by an external iliac artery stentgraft by ipsilateral femoral access.

In the angiography post-implantation, an endoleak was diagnosed. So, a second distal stentgraft was implanted in the external iliac artery. After implantation, a total exclusion of the aneurysm was obtained. The follow-up is now 3 months. The patient is asymptomatic.

Keywords: Internal iliac artery; Aneurysm; Embolization; Stentgraft; Outcomes

Introduction

Iliac artery aneurysms most often coexist with aortic aneurysms. In contrast, isolated iliac artery aneurysms are rare, and an isolated internal iliac artery aneurysm is particularly rare.

Isolated internal iliac artery aneurysms are defined as an increase in the size of the internal iliac artery without a coexisting aneurysm in another location [1]. They are rare with an incidence of only 0.4% of all aorto-iliac aneurysms [2].

Case Presentation

A 36-year-old man, with Behçet's disease, was suffering from abdominal pain.

Physical examination showed no anomalies.

Abdomino-pelvic duplex ultrasound revealed a sacciform aneurysm of the left internal iliac artery which diameter was 4 cm.

Computed tomography (CT) angiography demonstrated that the aneurysm was located at 3.4 cm from the iliac bifurcation, and measured 4 cm in diameter, without signs of rupture (Figure 1).

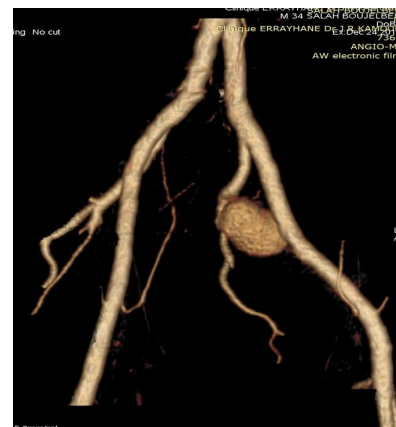

Figure 1: CT scan showing a huge aneurysm of the left internal iliac artery.

So, he underwent antegrade microcatheter transarterial embolization of the aneurysm using pushable coils via contralateral femoral artery puncture.

Post-embolization angiography demonstrated complete aneurysmal occlusion (Figure 2).

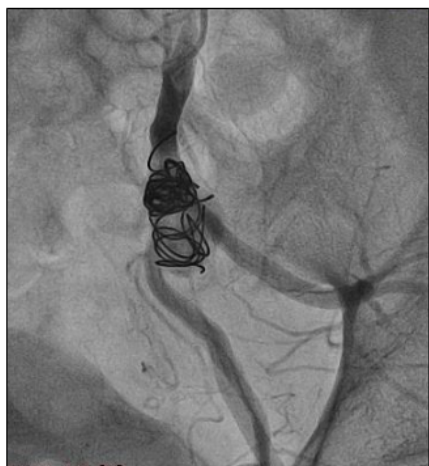

Figure 2: Embolization of the aneurysmal sac with coils.

The patient was discharged home after the second postoperative day. At 1 month follow-up, a noncontrast enhanced CT scan showed that the aneurysm was excluded (Figure 3).

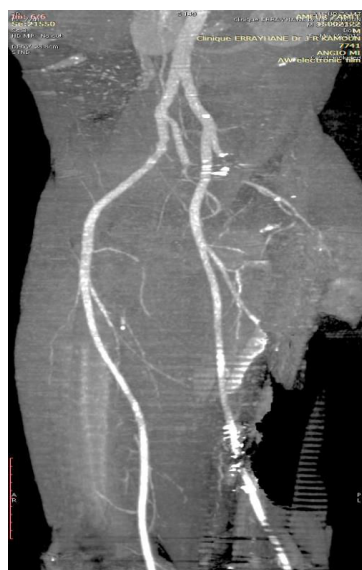

Figure 3: Aneurysm completely excluded in the postoperative CT scan.

Six months later, the patient suffered from recurrence of abdominal pain. CT scan confirmed patency of the aneurysmal sac (Figure 4). So, the patient underwent second endovascular exclusion by an external iliac artery stentgraft type Lifestream® 10 * 38 mm by ipsilateral femoral access (Figures 5 and 6).

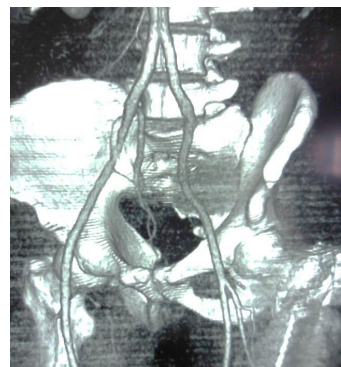


Figure 4: CT scan after 6 months showing patency of the aneurysmal sac (arrow).

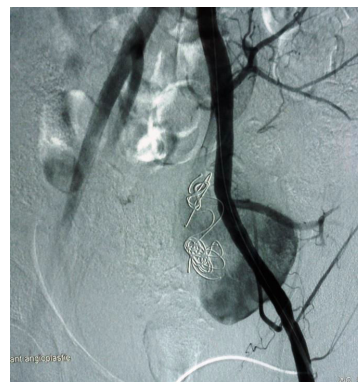

Figure 5: Arteriography showing a patency of the aneurysmal sac 6 months after embolization.

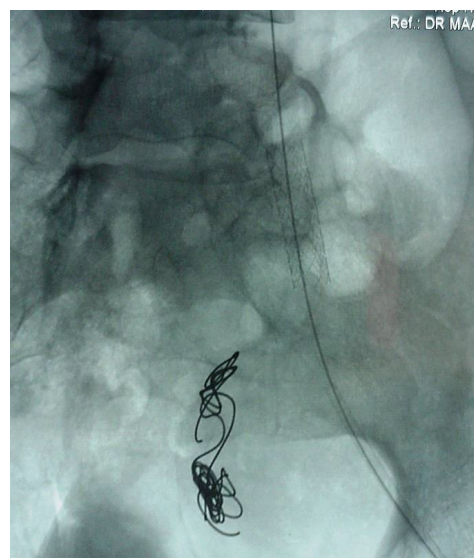


Figure 6: Deployment of left external iliac artery stentgraft.

In the angiography post-implantation, an endoleak was diagnosed. So, a second distal stentgraft 10 * 38 mm was implanted in the external iliac artery (Figure 7).

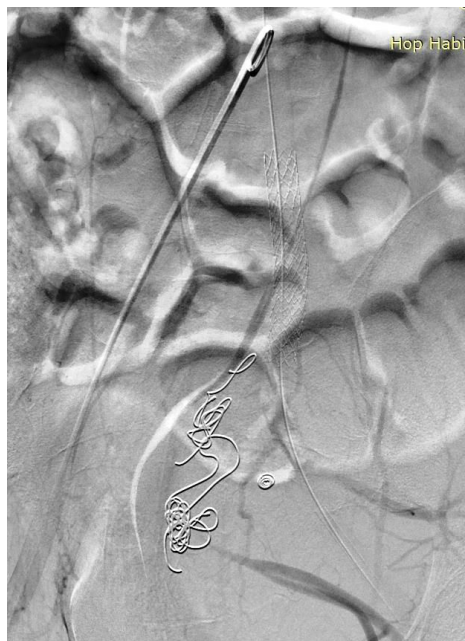

Figure 7: Second stentgraft of the left external iliac artery and exclusion of the aneurysm (arrows).

After implantation, a total exclusion of the aneurysm was obtained.

The follow-up is now 3 months. The patient is asymptomatic.

Discussion

The causes of internal iliac artery aneurysms are atherosclerosis, infection, trauma and disorders of the arterial wall. Connective tissue disorders and diseases of the arterial wall such as Marfan and Ehlers-Danlos syndrome, fibromuscular dysplasia, Takayasu's arteritis, Behcet's disease, and spontaneous dissection have all been reported as rare causes [3].

These aneurysms may be asymptomatic and are diagnosed coincidentally by radiological imaging for other reasons. They may present with symptoms caused by pressure on adjacent organs such as the ureter, the colon, or the small bowel, and the internal iliac vein. So, patients may have renal failure, abdominal or buttock pain, urinary retention [4]. Psoas irritation, paresis, sciatic neuralgia and lumbosacral pain have been reported by several authors [4].

Clinical examination can find a pelvic mass, oedema of the lower limb by compression of iliac vein.

The risk of increasing size and rupture is high [4]. Rupture may be intraperitoneal, retroperitoneal, into the rectum, ureter, and bladder.

Colour flow Doppler studies are useful in establishing the differential diagnosis of other masses of the pelvis and can demonstrate pulsatile flow within the aneurysm [5].

CT and magnetic resonance imaging with contrast demonstrate the aneurysm site, size and relationship to other organs.

Treatment of these aneurysms may be surgical ligation, excision, endoaneurysmorrhaphy, embolisation and endoluminal stenting [4]. Surgery is often technically challenging given the pelvic location of iliac aneurysms.

Unilateral ligation is well tolerated if the contralateral artery is free of disease [6].

Exclusion of the aneurysm seems to be effective in small, localised proximal internal iliac artery aneurysm. But this technique may allow subsequent growth of the aneurysmal sac from retrograde, cross-pelvic collateral flow.

Endoaneurysmorrhaphy has been described: the sac is opened and the ostial branches are oversewn [2].

Endovascular embolization using coils was described by Perdue in 1983 [7]. These endovascular techniques are associated with limited local trauma, rapid recovery, low blood loss, less anaesthetic requirement and reduced in-hospital stay [8].

The deployment of a stentgraft offers also the advantages of immediate isolation.

The majority of endovascular treatments for internal iliac artery aneurysms now involve a combination of coil embolisation and stenting [4]. Cynamon et al [9] performed successful coil embolisation in combination with stenting to occlude an internal iliac artery aneurysm.

Ricci et al. [10] treated successfully a ruptured internal iliac aneurysm in an 81-year-old man with multiple comorbidities with multiple coils and a covered stent.

Long term intensive follow-up of the patients is required. Some cases of enlarging after embolizations with coils were reported such as the case of our patient. The main reason for this enlarging may be a residual filling of the aneurysmal sac [11].

The flow could be antegrade via the origin of the internal iliac artery, or retrograde via the anterior or posterior division or an iliofemoral branch. An internal iliac artery aneurysm enlargement 28 months after the initial procedure related to a distal endoleak was reported [12].

Stent coverage may also be associated with endoleaks. In the series of Papazoglu et al. [13] of 112 patients, there were 7 cases of endoleaks following exclusion of internal iliac artery aneurysm with stentgraft without prior embolisation.

Aneurysmal diameter increase and secondary procedure are not rare and strict follow-up is required [11].

This case illustrates complications of the endovascular management of internal iliac artery aneurysms with coils and stentgraft.

Conclusion

The prognosis of these aneurysms becomes better with surgery and the advent of endovascular treatments. Coil embolization is a minimally invasive technique which excludes aneurysms, and which is associated with fewer early complications and shorter hospital stay compared with open repair.

It is safe in the short and midterm. However, endoleak and aneurysm diameter increases are not rare, such as the case of our

patient. So, yearly post-procedure computed tomography angiography seems appropriate.

References

1. Krupski WC, Selzman CH, Floridia R, Strecker PK, Nehler MR, et al. (1998) Contemporary management of isolated iliac aneurysms. *J Vasc Surg* 28: 1-13.
2. Kasulke RJ, Clifford A, Nichols WK, Silver D (1982) Isolated atherosclerotic aneurysms of the internal iliac arteries: report of two cases and review of the literature. *Arch Surg* 117: 73-77.
3. Atsuta Y, Inaba M, Goh K, Azuma N, Asasaka N, et al. (2003) Isolated iliac artery aneurysm caused by fibromuscular dysplasia: report of a case. *Surg Today* 33: 639-641.
4. Dix FP, Titi M, Al-Khaffaf H (2005) The Isolated Internal Iliac Artery Aneurysm-A Review. *Eur J Vasc Endovasc Surg* 30: 119-129.
5. Hashimoto BE, Kenny K, Kramer D (1992) Duplex and colour Doppler appearance of isolated internal iliac aneurysms. *J Ultrasound Med* 11: 45-47.
6. MacLaren A (1913) Aneurysm of the internal iliac: probably immediately following a severe instrumental delivery. Operation and partial cure. *Ann Surg* 58: 269-270.
7. Perdue GD, Mittenthal MJ, Smith RB, Salam AA (1983) Aneurysms of the internal iliac artery. *Surgery* 243-246.
8. Mori M, Sakamoto I, Morikawa M, Kohzaki S, Makino K, et al. (1999) Transcatheter embolisation of internal iliac artery aneurysms. *J Vasc Interv Radiol* 10: 591-597.
9. Cynamon J, Marin ML, Veith FJ, Bakal CW, Silberzweig JE, et al. (1995) Endovascular repair of an internal iliac artery aneurysm with use of a stented graft and embolization coils. *J Vasc Interv Radiol* 6: 509-512.
10. Ricci MA, Najarian K, Healey CT (2002) Successful endovascular treatment of a ruptured internal iliac aneurysm. *J Vasc Surg* 35: 1274-1276.
11. Millon A, Paquet Y, Ben Ahmed S, Pinel G, Rosset E, et al. (2013) Midterm Outcomes of Embolisation of Internal Iliac Artery Aneurysms. *European Journal of Vascular and Endovascular Surgery* 45: 22-27.
12. Chemelli A, Hugl B, Klocker J, Thauerer M, Strasak A, et al. (2010) Endovascular repair of isolated iliac artery aneurysms. *J Endovasc Ther* 17: 492-503.
13. Papazoglou KO, Sfyroeras GS, Zambas N, Konstantinidis K, Kakkos SK, et al. (2012) Outcomes of endovascular aneurysm repair with selective internal iliac artery coverage without coil embolization. *J Vasc Surg* 56: 298-303.