

Comparative Analysis of Plaque Growth after Arterial Stent Implant with Anti-Inflammatory Chemokine and Serine Protease Inhibitors Treatment

Liyang Liu^{1,2}, Erbin Dai^{1,2}, BaktiarKidwai², Jennifer Davids³, Colin Macaulay⁴, Grant McFadden³, and Alexandra Lucas^{1,2,3*}

¹Division of Cardiology, Department of Medicine, University of Florida, Gainesville, FL, USA

²John P. Robarts' Research Institute, University of Western Ontario, London, ON, Canada

³Department of Molecular Genetics and Microbiology, University of Western Ontario, London, ON, Canada

⁴Viron Therapeutics, London, ON, Canada

Abstract

Rationale - Inflammation is up-regulated at sites of stent implant, whether bare metal or drug-eluting stents (DES), increasing neointimal plaque growth (termed restenosis). Although stent implant, particularly DES, reduces recurrent plaque growth, restenosis still occurs. Inflammatory macrophages and T lymphocytes invade sites with endothelial injury and implanted foreign metal and polymers increase endothelial dysfunction, plaque growth and thrombosis. Chemokines attract inflammatory cells and coagulation pathway serine proteases regulate clot formation, metalloproteases, and inflammation. Large DNA viruses secrete highly active immune modulators that block host defenses, some of which are potent inhibitors of pathways that drive restenosis. We examine here two virus-derived anti-inflammatory proteins as potential anti-restenosis agents in a rabbit angioplasty and stent implant model; 1) M-T7, a chemokine modulator and 2) Serp-1, a serine protease inhibitor (*serpin*). **Results** - Inhibition of inflammatory cell activation by either M-T7 or Serp-1 protein infusions significantly reduced in-stent plaque growth. M-T7 displayed a trend toward more effective inhibition when given at lower doses and for shorter dosage times. **Conclusions** - 1) Inhibition of either chemokine or serine protease pathways effectively reduces inflammation and intimal hyperplasia after balloon angioplasty and stent implant (restenosis) in cholesterol fed rabbits. 2) Chemokine and serine protease pathways provide excellent therapeutic targets for inhibition of restenosis.

Keywords: Chemokines; Inflammatory cell; Serine protease inhibitors

Introduction

Although innate immunity is designed to initiate healing from vascular damage, an excess innate immune response is also proven to accelerate atherosclerotic plaque growth [1,2]. More recent work has reported endothelial dysfunction and inflammatory cell invasion at sites of coronary stent implant, causing increased risk of stent thrombosis [3-7]. Endothelial dysfunction and inflammation are detected with bare metal stents (BMS) and drug eluting stents (DES) with late stent thrombosis. Markers for dysregulation of inflammatory and thrombotic pathways are increased in patients at higher risk of restenosis or thrombotic occlusion [8,9]. DES release drugs that block cell proliferation, and potentially restenosis and inflammation, e.g. rapamycin and paclitaxel, but the foreign polymer and the metal in the stent can also interfere with endothelial regrowth that protects against excess inflammation and thrombosis. This is proposed as a cause for late restenosis and also thrombotic occlusions in DES and BMS. Acute stent thrombosis has high associated morbidity and mortality. While the advent of BMS reduced the incidence of restenosis when compared to balloon angioplasty and coated DES stents further reduced restenosis, both types of stents are associated with persistent risk of restenosis and thrombosis, particularly in the absence of adequate anti-platelet therapy [10].

Monocytes and lymphocytes are attracted to sites of vascular damage by cytokines and then migrate along chemokine gradients formed through attachment of chemokine to glycosaminoglycans (GAGs) at cellular surfaces and in connective tissue layers [11-13]. Chemokines are small 8-12 kDa chemoattractant proteins, classified as C, CC, CXC and CX3C, based upon C terminal sequences. Increased levels of chemokines are seen at sites of vascular injury and mice deficient in selected chemokines (e.g. monocyte chemoattractant

protein, MCP-1) and receptors (CCR2) exhibit reduced plaque growth after injury or in transplants.

Inflammatory cell invasion requires access through tissue connective tissues, necessitating breakdown of collagen and elastin through matrix degrading enzymes (matrix metalloproteinases or MMPs), that are activated by serine proteases. The thrombolytic urokinase- and tissue-type plasminogen activators (uPA and tPA, respectively) as well as plasmin, all coordinately activate pro-MMPs leading to connective tissue breakdown and thus orchestrate cell invasion into damaged vasculature [14-17]. Circulating chemokines, e.g. monocyte chemoattractant protein-1 (MCP-1, MIP1 α , CCR2, CX3CR1) and also the serine (uPA, tPA) and the matrix metalloproteases (MMP2, MMP9) and the serpin plasminogen activator inhibitor-1 (PAI-1) [9,10] are increased in unstable angina, non ST elevation MI (NSTEMI) and immediately after stent implant [18,19]. PAI-1 is seen in both increased and decreased restenosis [19,20]. tPA, uPA, uPA receptor (uPAR), and PAI-1 are generally elevated after injury and local overexpression of uPA accelerates plaque growth in rabbit carotids [14-17,19,21]. Mice

***Corresponding author:** Alexandra Lucas, MD, FRCP(C), Ethel Smith Chair Vasculitis Research, Section Head Vascular Research, Professor of Medicine, Divisions of Cardiovascular Medicine and Rheumatology, University of Florida, 1600 SW Archer Rd, PO BOX 100277, Gainesville, FL, USA, Tel: 32610-0277; E-mail: alexandra.lucas@medicine.ufl.edu

Received September 10, 2013; **Accepted** October 28, 2013; **Published** October 30, 2013

Citation: Liu L, Dai E, BaktiarKidwai, Davids J, Macaulay C, et al. (2013) Comparative Analysis of Plaque Growth after Arterial Stent Implant with Anti-Inflammatory Chemokine and Serine Protease Inhibitors Treatment. J Clin Exp Cardiol 4: 274. doi: 10.4172/2155-9880.1000274

Copyright: © 2013 Liu L, et al. This is an open-access article distributed under the terms of the Creative Commons Attribution License, which permits unrestricted use, distribution, and reproduction in any medium, provided the original author and source are credited.

lacking uPA undergo reduced levels of plaque growth after vascular injury [22].

However, whether the chemokine and serine protease pathways have direct causative impact on stent restenosis not defined, nor is it known which pathways have a greater role in accelerating inflammatory cell invasion and restenosis. Viruses have developed highly active inhibitors that target both uPA/uPAR and chemokine pathways. These inflammatory moderators function at femptomolar to picomolar concentrations when secreted by the originating viruses [23,24]. Two such proteins, Serp-1 that inhibits uPA/uPAR [23-28] and M-T7 [26,29-31] that blocks the C terminal GAG binding domain of C, CC and CXC class chemokines [26,29-31] have been purified individually and studied as anti-inflammatory reagents in a wide range of animal models with demonstrated reduction in inflammatory cell invasion and plaque growth. One protein, Serp-1 has been successfully tested in clinical trial for treatment of patients with unstable coronary syndromes (Unstable angina and NSTEMI) who have received stent implants [26,32]. Serp-1 infusions, administered once a day for three days starting immediately after stent implant, significantly reduced markers of myocardial damage with variable reductions in inflammatory and clotting (D dimer) [26]. These studies were, however, not sufficiently powered to evaluate potential effects on long term plaque growth.

We report here a study examining and comparing the effects of anti-inflammatory protein treatments with Serp-1 and M-T7, given by intravenous injection, on restenosis and local stent inflammatory cell invasion in cholesterol fed rabbits.

Methods

Rabbit arterial injury and stenting

All surgical procedures were approved by the University of Western Ontario/Robarts Research Inst. lab animal care committee and all procedures conformed to University and national guidelines for laboratory animal surgery and research. One hundred and forty one New Zealand White rabbits (weight: 3.1 ± 0.04 kg; mean \pm SEM) were fed a cholesterol rich diet (0.5% cholesterol in 6% peanut oil) for two weeks. Femoral arteriotomy was performed under general anaesthetic (40 mg/kg ketalean, 8 mg/kg xylazene and 0.5 mg/kg acepromazine given by intramuscular injection; Vetrepharm Canada, Inc., London, ON, Canada) and a 4Fr arterial sheath was placed in the femoral artery

(30, ref Lucas Circ 1996 and ChristovKorolPhotPhotbiol). Heparin 400 units were given via the arterial sheath. A 3.0-3.5 mm diameter balloon angioplasty catheter was introduced via the femoral arteriotomy and inflated to nominal pressure (8 atmospheres) in the distal abdominal aorta. Vascular injury was produced by advancing the inflated balloon through the abdominal aorta up to the distal thoracic aorta and withdrawing it three times. Stainless steel stents (AVE (Medtronic, Minneapolis MN), ACS (Abbott, Abbot Park, IL), or NIR Niroyal (Boston Scientific Corporation, Natick, MA) were then placed in the distal abdominal aorta and deployed at 14 atmospheres (Table 1). Catheter and arterial sheath were removed and arteriotomy closed. Rabbits were divided into groups receiving either one day, two days, three days or 11 days of treatment with one of three treatment regimens: saline control 1 ml/day (n=39), Serp-1 at 0.05 μ g/kg, 5 μ g/kg, up to 50 μ g/kg/day (n = 63), and M-T7 at 10 μ g/kg/daily (n = 38) for one to three daily injections and alternate days for 11 day injections (Table 1). M-T7 supplies were smaller than those available for Serp-1 treatments. Injections were initially given immediately after stent implant by intra-arterial injection through the catheter lumen. All subsequent injections were given by intravenous injections via ear vein. All rabbits received Aspirin 40 mg per day orally for 10 days. Cholesterol feeding was continued for another two weeks and rabbits were sacrificed at four weeks following stent implant. Aortas were dissected and specimens obtained for analysis. Sections from each stent specimen were made at two to three levels, fixed and stained with haematoxylin and eosin.

Morphometric analysis

Harvested arterial sections were processed and stained with hematoxylin and eosin (H & E) or Masson's trichrome stains as previously described [25-31,33]. Plaque area, was measured by morphometric analysis using an Olympus CCD color video camera attached to an Olympus microscope, and the ImagePro application program calibrated to the microscope objective [26-31,33]. Both the mean total cross-sectional intimal area and the mean intimal thickness after normalized to the medial thickness were calculated for each arterial section. Specimens isolated from rabbits were cut into three sections and two histology cross sections stained per each of the three artery specimens (6 sections per specimen).

Cross sectional area at each level was measured for three parameters: reference vessel area, measured as area inside of the

Stents Type	Stent size	TreatmentX doses	Rabbit Number	
			Follow up /	Stent Implant
ACS Stent	3.0 X 15mm	Saline x 1	6	6
ACS Stent	3.0 X 15mm	Serp-1 150 μ g (50 μ g/kg) x 1	6	6
ACS Stent	3.0 X 15mm	M-T7 30 μ g (10 μ g/kg) x 1	6	6
AVE Stent	3.5 X 24mm-30mm	Saline x 2	7	10
AVE Stent	3.5 X 24mm-30mm	Serp-1 0.015 μ g (0.005 μ g/kg) x 2	7	8
AVE Stent	3.5 X 24mm-30mm	Serp-1 150 μ g (50 μ g/kg) x 2	8	8
AVE Stent	3.5 X 24mm-30mm	M-T7 30 μ g (10 μ g/kg) x 2	8	9
AVE Stent	3.5 X 24mm	Saline x 3	7	10
AVE Stent	3.5 X 24mm	Serp-1 0.015 μ g (0.005 μ g/kg) x 3	8	9
AVE Stent	3.5 X 24mm	Serp-1 1.5 μ g (0.5 μ g/kg) x 3	9	9
AVE Stent	3.5 X 24mm	Serp-1 150 μ g (50 μ g/kg) x 3	9	9
AVE Stent	3.5 X 24mm	M-T7 30 μ g (10 μ g/kg) x 3	9	9
NIR Stent	3.5 or 4.0X 16mm-32mm	Saline x 11	10	13
NIR Stent	3.5 or 4.0X 16mm-32mm	Serp-1 150 μ g (50 μ g/kg) x 11	11	14
NIR Stent	3.5 or 4.0X 16mm-32mm	Serp-1 150 μ g (50 μ g/kg) x 11	14	14

Table 1: Rabbit Abdominal Aortic Stent Implant Model.

internal elastic lamina; lumen area, measured as area inside of the intima and plaque area measured as area between the internal elastic lamina and the intima. Additionally, plaque thickness was measured at the point of maximum thickness in each section and a mean value calculated for each animal from the measurements for all available sections for that animal. A separate analysis was performed by two of the investigators blinded to treatment. For each animal, a mean plaque area was calculated for all the sections available for that animal. Mean values for all animals are reported for the proximal segments, at the segment with maximum plaque growth and for the mean plaque area in each animal.

Serp-1 and M-T7 expression and purification

Purified Serp-1 protein was provided by Viron Therapeutics Inc. (London, ON, Canada). In brief, Serp-1 was purified from the supernatant of recombinant Chinese hamster ovary (CHO) cell lineage sequential column chromatographic separation as previously described [27,28,32,33]. Serp-1 purity was over 95% as determined by overloaded Coomassie-stained SDS-PAGE gels and reverse-phase HPLC.

M-T7 was isolated from baby green monkey kidney (BGMK) cells infected with vaccinia vector expressing M-T7. M-T1 from vMyxlac-T1gpt infected BGMK cell cultures as previously described [26,29,31]. Concentrated supernatants were fractionated by Mono QHR5/5 anion exchange chromatography followed by gel filtration chromatography using a HiLoadSuperdex 200 column (AmershamPahrmacia Biotech Inc.).

Statistical methods

Data are presented as mean \pm standard error of the mean (SEM), as previously described. Mean measurements for each experimental animal for all morphometric data were assessed for significant changes by analysis of variance (ANOVA) with FLSD (Fisher least squares post hoc) secondary analysis. Mortality was assessed by Chi-square analysis.

Results

Effects of anti-inflammatory treatments on adverse events after balloon angioplasty and stent implant

Although not significant, there was an increase in adverse events in saline treated animals when compared to all M-T7 or Serp-1 treated rabbits after stent implant. For all treated animals the surgical mortality numbers were as follows; for Saline control treatment there were 9 deaths (23.1%) with 2 thromboses, 4 bleeds, 1 peritonitis, 1 traumatic leg fracture and one death for undetermined cause; for Serp-1 treatment there were 5 deaths with 3 thromboses, 1 stent fracture (bend), and 1 paralysis (7.9%); and for M-T7 treatment there was 1 death with 1 thrombosis (2.6%). By Chi square analysis for all adverse events there was a significant decrease in overall adverse events for Serp-1 compared to saline ($P \leq 0.0334$) and reduced thrombosis events for Serp-1 treatment when compared to Saline treatment ($P \leq 0.0071$). There was no hemorrhage detected with Serp-1 treatments. For M-T7 treatments, there was only one adverse event, a thrombotic occlusion of the artery after stent implant with an overall significant reduction in adverse events with M-T7 treatments after angioplasty and stent implant ($P \leq 0.0076$ by Chi square analysis). There was no significant difference detected for adverse events when comparing all Serp-1 and M-T7 treated animals ($P = 0.276$ for all adverse events and $P = 0.7194$ for combined thrombotic and hemorrhagic events). There was 1 paralysis that occurred due to inappropriate securing of the rabbit during an injection resulting in a spine fracture that was unrelated to surgery and is not included in the statistical analyses.

Inhibition of early inflammatory responses reduces late in-stent plaque growth- Histological analysis

Both M-T7 and Serp-1 significantly reduced plaque growth both inside the arterial area covered by the stent and outside the arterial areas covered by stents in areas of angioplasty injury alone. Large, lipid-laden plaques were detected at sites of stent implant with large numbers of invading inflammatory mononuclear cells (Figure 1A and B). M-T7

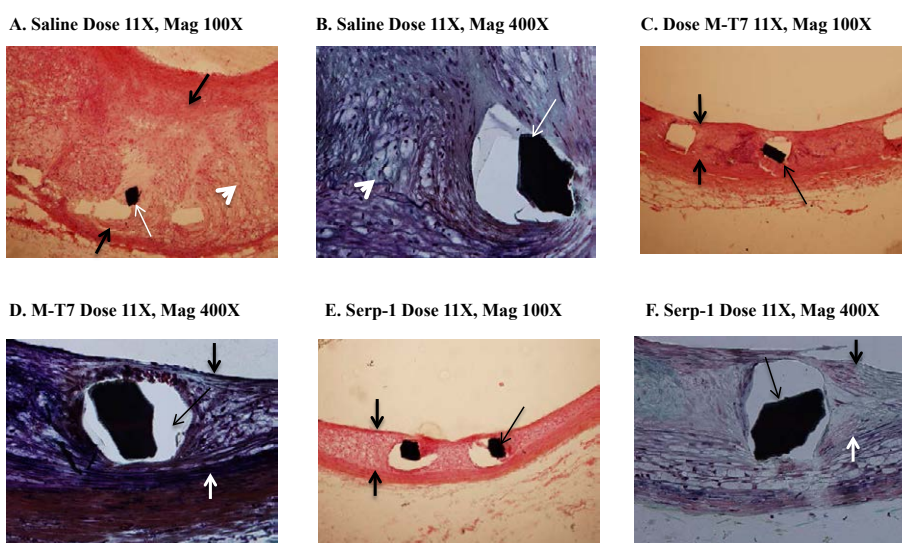


Figure 1: Hematoxylin and eosin stained cross sections of rabbit aorta at sites of stent implant at 4 weeks follow up. Marked inflammatory plaque is detected with saline treatment 4 weeks after balloon angioplasty and stent implant. M-T7 and Serp-1 markedly reduce visible plaque in cross sections at 4 weeks follow up. Saline treated rabbit with 11 daily injections - **A** - Mag 100X, **B** - Mag 400X. M-T7 treated rabbits with 11 daily injections - **C** - Mag 100X, **D** - Mag 400X. Serp-1 treated rabbits with 11 daily injections - **E** - Mag 100X, **F** - Mag 400X.

reduced plaque growth at doses of 10 µg/kg/d (~30 µg per 3 Kg rabbit body weight) (Figure 1C and D) given at the time of stent implant. Serp-1 also produced significant reductions in plaque size with daily injections at doses of 50 µg/kg/d (150 µg) and higher (Figure 1E and F). When rabbits were treated with either Serp-1 or M-T7 there was a reduction in the plaque size as well as in the local invading inflammatory cell infiltrates, e.g. reduced foam cell macrophage invasion at sites of stent strut implants embedded in the artery wall (Figure 1B,D and F). Serp-1 was tested for dose response with two differing dose levels for rabbits with two and with three daily injections. A clear dose response is detected for either two or three daily injections indicating that the reduction in plaque area is not a random response to injection of a foreign protein. It should also be noted that in prior studies the use of mutagenized inactive Serp1- protein has not produced significant reductions in plaque growth.

Quantitative analysis

Treatment with either M-T7 or Serp-1 for two or more days after balloon angioplasty and stent implant demonstrated a significant reduction in mean plaque area (Figure 2B-D) and percentage lumen narrowing (Figure 3B-D) for stented aortic sections. Overall there was greater than 53% reduction for the treatment groups, with greater than two days treatment, when compared to the saline treated control group.

Although demonstrating a trend, neither M-T7 ($P = 0.112$) nor Serp-1 ($P = 0.476$) treatment given for one day only as a single intravenous bolus infusion after balloon angioplasty and stent implant, did not reduce plaque growth significantly when measured either as plaque area (Figure 2A, $P = NS$) or as percentage lumen narrowing (Figure 3A). The mean plaque area was similar at the three stent segments in all groups.

Overall M-T7 and Serp-1 produced comparable reductions in plaque growth after balloon angioplasty and stent implant when given as 2 day (Figure 2B and 3B; $P < 0.005$ and < 0.004 for M-T7 and Serp-1 for plaque area and $P < 0.046$ and $P < 0.011$ for M-T7 and Serp-1 treatment respectively for percentage lumen narrowing), 3 day (Figure 2C and 3C; $P < 0.045$ and $P < 0.0003$ for M-T7 and Serp-1 for plaque area and $P < 0.001$ and $P < 0.0002$ for M-T7 and Serp-1 treatment respectively for percentage lumen narrowing) or 11 day (Figure 2D and 3D; $P < 0.0003$ and $P < 0.001$ for M-T7 and Serp-1 for plaque area and $P < 0.0001$ and $P < 0.0003$ for M-T7 and Serp-1 treatment, respectively for percentage lumen narrowing) injections starting at the day of stent implant. However with a single injection given at the time of stent implant neither M-T7 nor Serp-1 was able to produce a long term reduction in plaque size although M-T7 treatment showed a trend toward reduced plaque growth (Figure 1A and 2A; $P = 0.112$ and $P = 0.476$, for M-T7 and Serp-1 treatment, respectively for plaque area and $P = 0.235$, $P = 0.987$

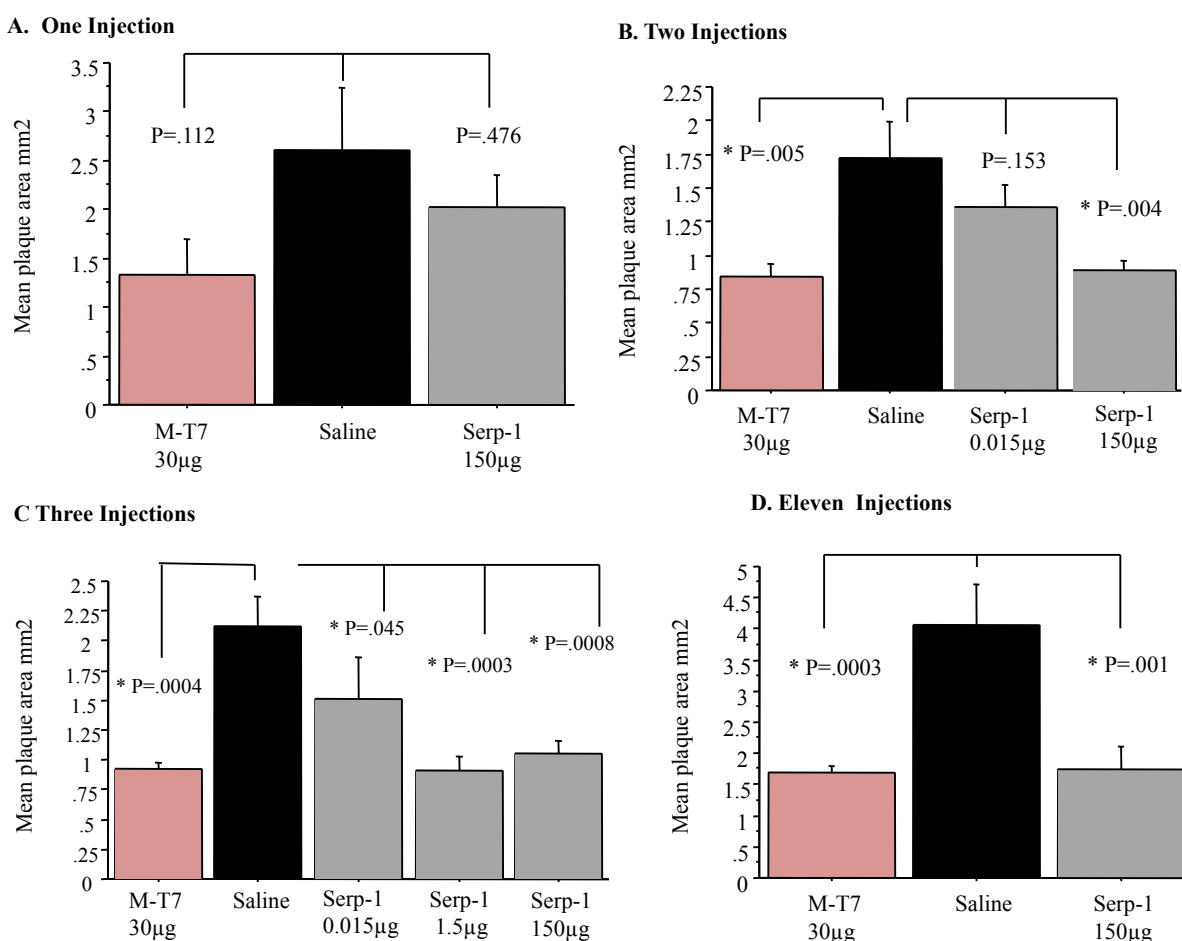


Figure 2: Morphometric analysis of mean plaque area at sites of stent implant demonstrated reduced plaque areas with greater than two injections of M-T7 and with greater than three injections of Serp-1 at 4 weeks follow up. A dose response is seen with Serp-1 given for three daily doses at three differing doses of Serp-1. **A.** Single day injection, **B.** Two daily injections, **C.** Three daily injections, **D.** 11 daily injections.

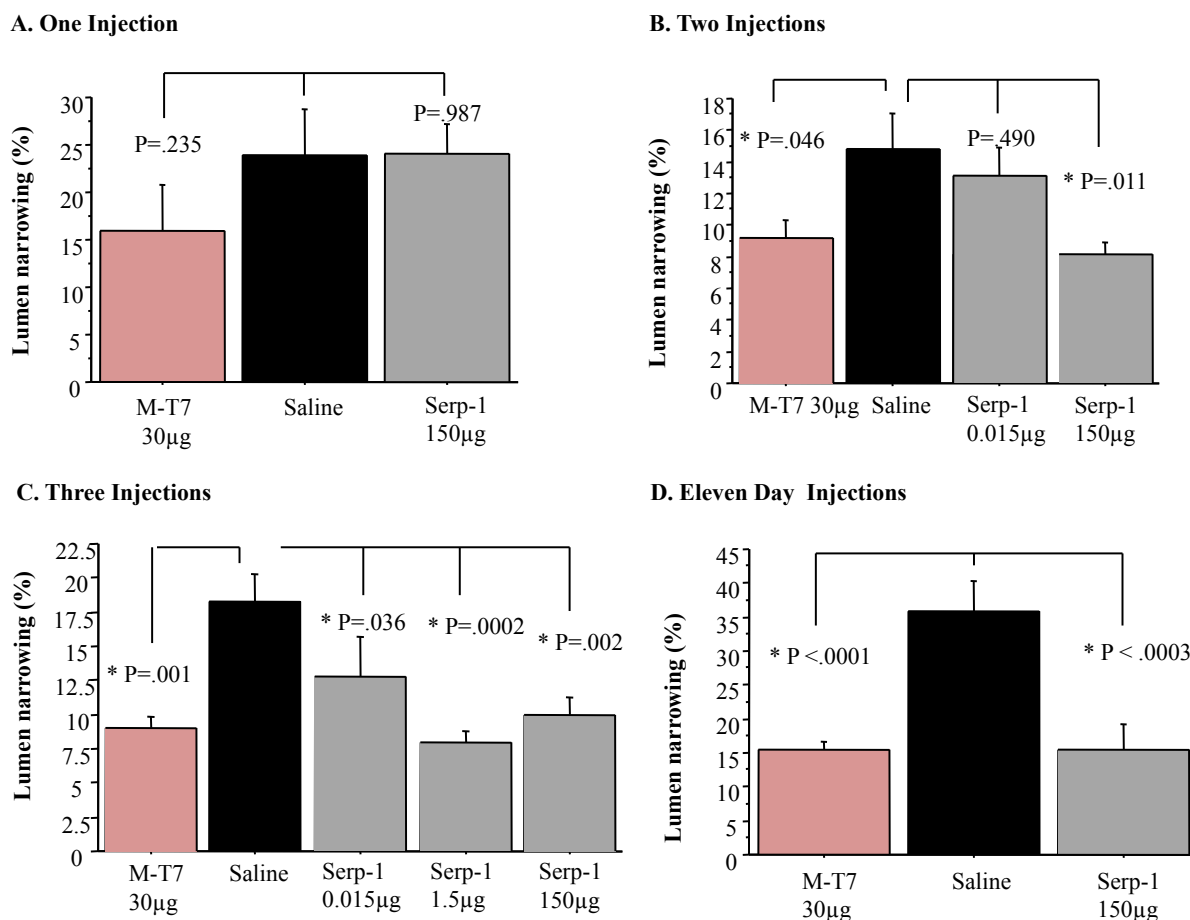


Figure 3: Morphometric analysis of mean lumen percentage narrowing at sites of stent implant demonstrated reduced plaque areas with greater than two injections of M-T7 and with greater than three injections of Serp-1 at 4 weeks follow up. A dose response is seen with Serp-1 given for three daily doses at three differing doses of Serp-1. **A.** Single day injection, **B.** Two daily injections, **C.** Three daily injections, **D.** 11 daily injections.

for M-T7 and Serp-1 treatment, respectively for percentage lumen narrowing).

Measures of intimal to medial thickness ratios, which are used to reduce variations inherent in differing aortic sizes due to natural biological variability, displayed the same significant changes in plaque size with each anti-inflammatory protein treatment. However, in contrast to other measures of plaque growth M-T7 produced a significant reduction in plaque thickness after a single injection given at the time of stent implant (Figure 4; $p < 0.0001$). Serp-1 did not reduce intimal to medial thickness ratios with a single bolus injection given at the time of stent implant (Figure 4).

In summary both Serp-1 and M-T7 treatments given for two or more days were capable of reducing plaque growth in the rabbit aorta at 4 weeks follow up after balloon angioplasty and stent implant. M-T7 by some measures (specifically intimal to medial thickness ratios) reduced plaque size when given at lower doses and with alternate day injections for treatment groups. Thus M-T7 may be more effective at blocking plaque growth long term after stent implant.

Plaque area according to stent length and type

Stents used in these studies were donated by the companies and varied somewhat in length and diameter (Table 1). Thus an attempt was made to ensure that the same stent brands (manufacturing styles of

stents) were used for each treatment and dosing groups. A similar range of stent lengths was used for each treatment and dosing groups. The mean reference stent size and length at deployment are summarized in Table 1. There were no statistically significant differences between the three groups in these parameters for the dosing treatment groups.

Plaque area, when plotted against stent length for all protein treatment groups, did not show a significant correlation ($R^2 = 0.0715$, $P = NS$). There was a negative correlation in the saline group only ($R^2 = 0.454$, $P = 0.03$, Saline group only). There was no significant difference in the mean plaque area between different stent types within any of the groups. However, plaque area was greater for Niroyal stents in the saline treatment group only as compared to the Serp-1 and M-T7 treated rabbits, $p = 0.046$, treatment versus saline.

Mononuclear cellular invasion

Invading inflammatory mononuclear cells (macrophage and T cells) in the intimal, medial, and adventitial layers were counted and cell count compared per treatment group at 4 weeks follow up (Figure 5). As for the comparisons of plaque size, both M-T7 and Serp-1 significantly reduced numbers of invading mononuclear cells in all three layers with greater effects on intimal and adventitial layers. Intimal and adventitial cell counts were significantly reduced for both M-T7 and Serp-1 treatments given for more than three daily

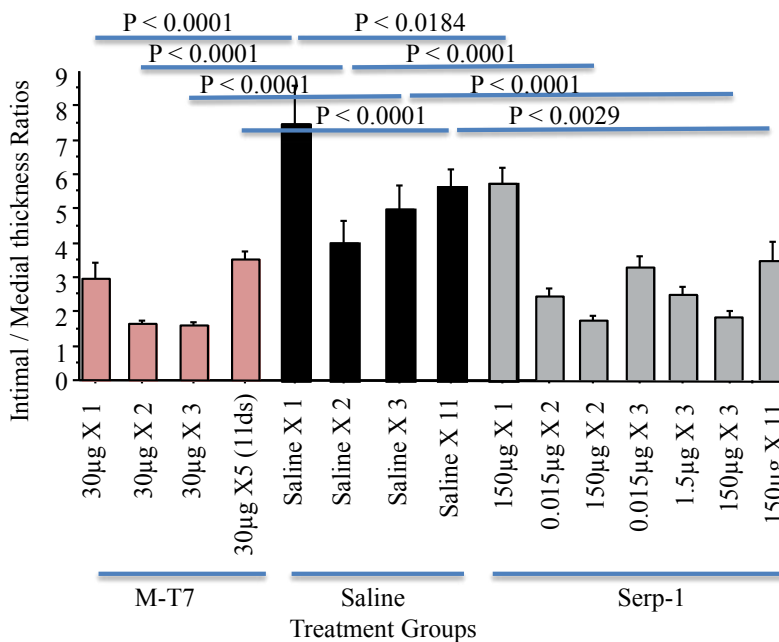


Figure 4: Intimal/medial thickness ratios demonstrated reduced intimal thickness with two or more daily doses of M-T7 and with three or more daily doses of Serp-1 ($P < 0.0001$).

treatments (Figure 5). Of interest, M-T7 reduced intimal mononuclear cell numbers after a two daily doses ($P < 0.029$), while Serp-1 ($P = 0.086$) was ineffective with two doses. However both M-T7 ($P < 0.0001$) and Serp-1 ($P < 0.0001$) reduced invading mononuclear cell counts in the adventitial layers.

Discussion

While advances in medical therapy have been made in the prevention and treatment of native vascular atheroma development and acute thrombosis in unstable angina specifically with lipid lowering agents and anti-platelet or anti-thrombotic agents, treatment for restenosis remains limited. Acute thrombosis is reduced with dual anti-platelet therapy and acute post stent infarction may be reduced with high dose statin therapy [34]. However the most effective treatment, proven to reduce restenosis after angioplasty or stent implant is the use of bare metal stents when compared to balloon angioplasty alone or the use of drug eluting stents when compared to balloon angioplasty or BMS [7-10,35-37]. Multiple studies report correlations between acute and chronic inflammatory cell invasion and activation with restenosis as well as later stent thrombosis [7-10,38,39]. Agents targeting inflammatory reactions have been reported in preclinical animal studies and small clinical trials to alter restenosis after stent implant but this work remains investigational [38-43].

Acute thrombosis of stents remains another significant problem, necessitating prolonged use of dual anti-platelet agents. DES has markedly improved risk of restenosis from 20-30% with BMS to less than 10% with DES, but there are many clinical contraindications for prolonged use of dual anti-platelet therapy. Longer term dual anti-platelet treatment is recommended for DES implant, than for BMS, due to the risk of late stent thrombosis. This need for longer term anti-platelet treatments influences clinical choices between the use of BMS or DES when patients have a history of recent severe bleeding or have planned surgical procedures. Stenosis and thrombotic occlusions of vein grafts is also frequently seen, up to 50% of vein grafts in coronary

artery bypass graft (CABG) patients are occluded within 10 years and or these occlusions 80% occur in the first two years [40,41]. There is a high risk of recurrent graft occlusion after angioplasty and stent implant. Some patients present technically challenging tortuous arteries that necessitate the use of balloon angioplasty alone, e.g. stent implant is not technically possible. Without stent implant the risk of restenosis for balloon angioplasty alone is 30-50%, much higher than with stent implants. The potential to reduce restenosis through anti-inflammatory agent treatment might allow for improved outcomes in patients where balloon angioplasty alone or BMS is necessary. Further the use of anti-inflammatory agents might have the potential to also reduce risk of late stent thrombosis.

A significant reduction in stent thrombosis was demonstrated with treatment with Serp-1 ($P \leq 0.0334$ for all adverse events; $P \leq 0.0071$ for thrombosis and hemorrhage) and M-T7 ($P < 0.0076$ for all adverse events; $P \leq 0.00516$). There was no difference in adverse events when comparing Serp-1 and M-T7 treatments ($P = 0.2746$ for all adverse events; $P = 0.7194$ for thrombotic/ hemorrhagic events). This reduction in adverse events may have been due to the anti-inflammatory activity of each protein and is consistent with prior studies demonstrating reduced adverse events with non-specific inhibitors of inflammation such as dexamethasone coated stent implants, statin coated stents or ghrel in peptide treatment [37,38,42,43]. Serp-1 may also have reduced thrombosis and/or hemorrhage through inhibition of fXa and the plasminogen activators (tPA and uPA), respectively. Excess bleeding was not seen after treatment with either agent. The fact that there was no significant difference in adverse events and specifically thrombotic and hemorrhagic events would support prior studies from other researchers that have linked excess inflammation in stent implant areas with later stent thrombosis [7-10,35-43]. Specific or selective inflammatory cell responses were not examined here and remain to be determined. Prior work has demonstrated that there is modification of both macrophage and T cell responses in animal models of angioplasty or transplant with either Serp-1 or M-T7 treatments, dependent upon

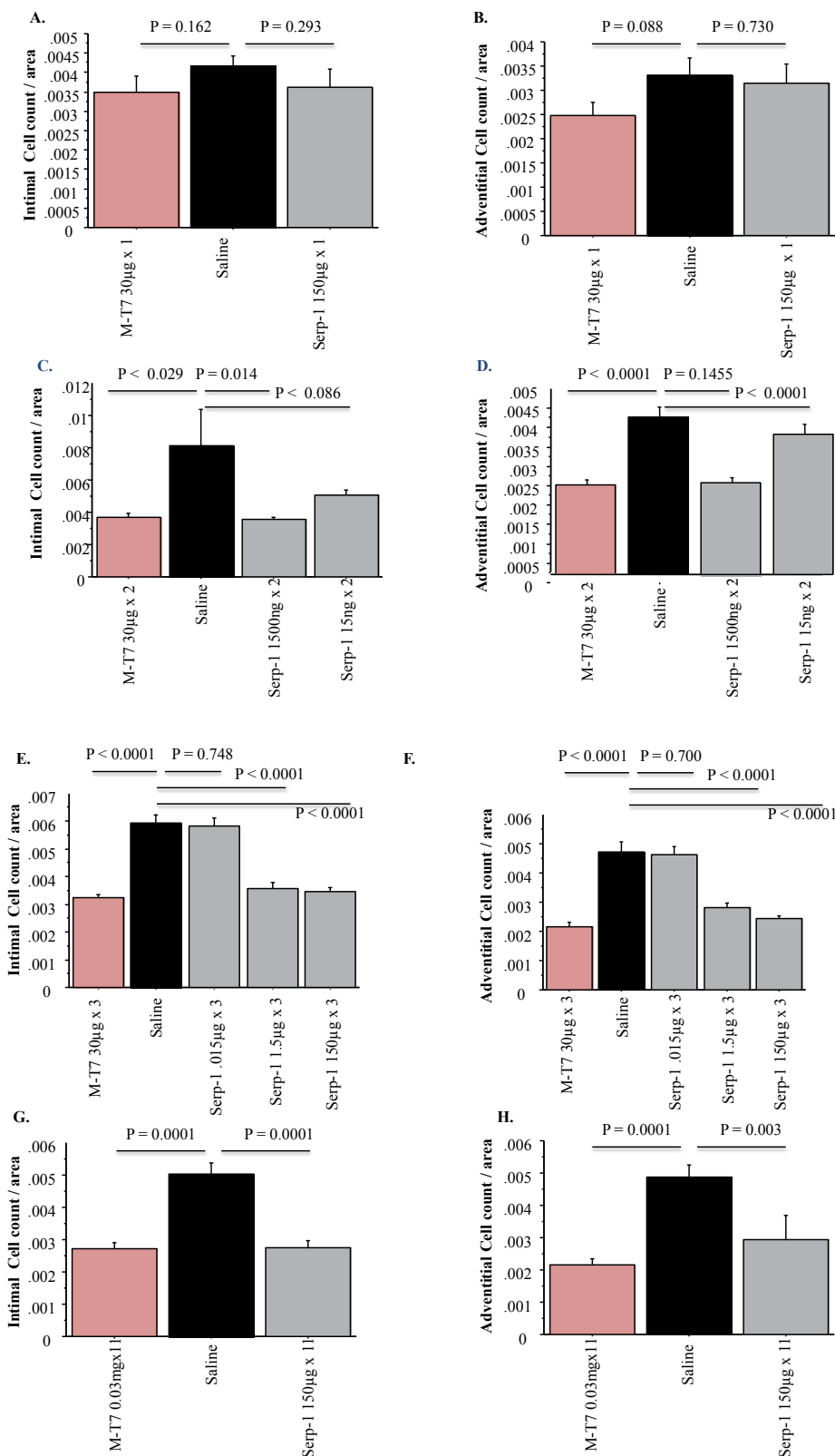


Figure 5: Mean cell counts for intimal and adventitial layer invading mononuclear cells at sites of stent implant at 4 weeks follow up. Cell counts measured in three high power fields using sites with the largest numbers of invading cells for each count. **A.** Intimal cell count one day dosing, **B.** Adventitial cell count one day dosing, **C.** Intimal cell count two day dosing, **D.** Adventitial cell count two day dosing, **E.** Intimal cell count three days dosing, **F.** Adventitial cell count three days dosing, **G.** Intimal cell count 11 days dosing, **H.** Adventitial cell count 11 days dosing.

the animal model studied. Examination of selected cell responses after stent implant and treatment with these anti-inflammatory agents will require further study.

With this study we examine the potential for two anti-inflammatory protein therapeutics, that block differing inflammatory response pathways, to reduce plaque growth in cholesterol fed rabbit model with balloon angioplasty and stent implant. Targeting either of the two differing pathways, either chemokines or coagulation pathway serine proteases, significantly reduced stent plaque and inflammatory cell invasion. We conclude that blockade of inflammation after stent implant has the potential to reduce in stent restenosis and potentially stent thrombosis, providing new and untapped therapeutic approaches to the prevention of restenosis and thrombosis after coronary stent implant.

References

1. Methe H, Weis M (2007) Atherogenesis and inflammation--was Virchow right? *Nephrol Dial Transplant* 22: 1823-1827.
2. Mitchell RN, Libby P (2007) Vascular remodeling in transplant vasculopathy. *Circ Res* 100: 967-978.
3. Otsuka F, Finn AV, Yazdani SK, Nakano M, Kolodgie FD, et al. (2012) The importance of the endothelium in atherothrombosis and coronary stenting. *Nat Rev Cardiol* 9: 439-453.
4. Otsuka F, Nakano M, Ladich E, Kolodgie FD, Virmani R (2012) Pathologic Etiologies of Late and Very Late Stent Thrombosis following First-Generation Drug-Eluting Stent Placement. *Thrombosis* 2012: 608593.
5. Chaabane C, Otsuka F, Virmani R, Bochaton-Piallat ML (2013) Biological responses in stented arteries. *Cardiovasc Res* 99: 353-363.
6. Okura H, Takagi T, Yoshida K (2013) Therapies targeting inflammation after stent implantation. *Curr Vasc Pharmacol* 11: 399-406.
7. Inoue T, Croce K, Morooka T, Sakuma M, Node K, et al. (2011) Vascular inflammation and repair: implications for re-endothelialization, restenosis, and stent thrombosis. *JACC Cardiovasc Interv* 4: 1057-1066.
8. Khouzam RN, Shaheen M, Aziz RK, Ibebuogu UN (2012) The important role of inflammatory biomarkers pre and post bare-metal and drug-eluting stent implantation. *Can J Cardiol* 28: 700-705.
9. Li JJ, Li J, Nan JL, Li Z, Zhen X, et al. (2007) Coronary restenotic reduction of drug-eluting stenting may be due to its anti-inflammatory effects. *Med Hypotheses* 69: 1004-1009.
10. Niccoli G, Montone RA, Ferrante G, Crea F (2010) The evolving role of inflammatory biomarkers in risk assessment after stent implantation. *J Am Coll Cardiol* 56: 1783-1793.
11. Wan W, Murphy PM (2013) Regulation of atherogenesis by chemokines and chemokine receptors. *Arch Immunol Ther Exp (Warsz)* 61: 1-14.
12. Legein B, Temmerman L, Biessen EA, Lutgens E (2013) Inflammation and immune system interactions in atherosclerosis. *Cell Mol Life Sci* 70: 3847-3869.
13. Weber C, Noels H (2011) Atherosclerosis: current pathogenesis and therapeutic options. *Nat Med* 17: 1410-1422.
14. Bobik A, Tkachuk V (2003) Metalloproteinases and plasminogen activators in vessel remodeling. *Curr Hypertens Rep* 5: 466-472.
15. Pawlak K, Pawlak D, MyÅliwiec M (2008) Urokinase-type plasminogen activator and metalloproteinase-2 are independently related to the carotid atherosclerosis in haemodialysis patients. *Thromb Res* 121: 543-548.
16. Kazi M, Zhu C, Roy J, Paulsson-Berne G, Hamsten A, et al. (2005) Difference in matrix-degrading protease expression and activity between thrombus-free and thrombus-covered wall of abdominal aortic aneurysm. *Arterioscler Thromb Vasc Biol* 25: 1341-1346.
17. Chen H, Davids JA, Zheng D, Bryant M, Bot I, et al. (2013) The serpin solution; targeting thrombotic and thrombolytic serine proteases in inflammation. *Cardiovasc Hematol Disord Drug Targets* 13: 99-110.
18. Aukrust P, Halvorsen B, Yndestad A, Ueland T, Øie E, et al. (2008) Chemokines and cardiovascular risk. *Arterioscler Thromb Vasc Biol* 28: 1909-1919.
19. Wexberg P, Jordanova N, Strehblow C, Syeda B, Meyer B, et al. (2008) Time course of prothrombotic and proinflammatory substance release after intracoronary stent implantation. *Thromb Haemost* 99: 739-748.
20. Strauss BH, Lau HK, Bowman KA, Sparkes J, Chisholm RJ, et al. (1999) Plasma urokinase antigen and plasminogen activator inhibitor-1 antigen levels predict angiographic coronary restenosis. *Circulation* 100: 1616-1622.
21. Massey PG, Tanaka S, Buckler JM, Jiang B, McCourtie A, et al. (2009) Constriction of carotid arteries by urokinase-type plasminogen activator requires catalytic activity and is independent of NH(2)-terminal domains. *Thromb Haemost* 102: 983-992.
22. Lijnen HR, Van Hoef B, Lupu F, Moons L, Carmeliet P, et al. (1998) Function of the plasminogen/plasmin and matrix metalloproteinase systems after vascular injury in mice with targeted inactivation of fibrinolytic system genes. *Arterioscler Thromb Vasc Biol* 18: 1035-1045.
23. Lucas A, McFadden G (2004) Secreted immunomodulatory viral proteins as novel biotherapeutics. *J Immunol* 173: 4765-4774.
24. Lucas A, Liu L, Dai E, Bot I, Viswanathan K, et al. (2008) The Serpin Saga; Development of a New Class of Virus Derived Anti-inflammatory Protein Immunotherapeutics in Pathogen-Derived Immunomodulatory Molecules, Edited by Padraic Fallon, Landes Bioscience Pub Date: 10-19.
25. Chen H, Zheng D, Davids J, Barte MY, Dai E, et al. (2011) Viral serpin therapeutics from concept to clinic. *Methods Enzymol* 499: 301-329.
26. Barte MY, Dai E, Liu L, Munuswamy-Ramanujam G, Macaulay C, et al. (2009) 10 M-T7: measuring chemokine-modulating activity. *Methods Enzymol* 460: 209-228.
27. Viswanathan K, Richardson J, Togonu-Bickersteth B, Dai E, Liu L, et al. (2009) Myxoma viral serpin, Serp-1, inhibits human monocyte adhesion through regulation of actin-binding protein filamin B. *J Leukoc Biol* 85: 418-426.
28. Dai E, Guan H, Liu L, Little S, McFadden G, et al. (2003) Serp-1, a viral anti-inflammatory serpin, regulates cellular serine proteinase and serpin responses to vascular injury. *J Biol Chem* 278: 18563-18572.
29. Liu L, Lalani A, Dai E, Seet B, Macaulay C, et al. (2000) The viral anti-inflammatory chemokine-binding protein M-T7 reduces intimal hyperplasia after vascular injury. *J Clin Invest* 105: 1613-1621.
30. Bédard EL, Kim P, Jiang J, Parry N, Liu L, et al. (2003) Chemokine-binding viral protein M-T7 prevents chronic rejection in rat renal allografts. *Transplantation* 76: 249-252.
31. Dai E, Liu LY, Wang H, Mclvor D, Sun YM, et al. (2010) Inhibition of chemokine-glycosaminoglycan interactions in donor tissue reduces mouse allograft vasculopathy and transplant rejection. *PLoS One* 5: e10510.
32. Tardif JC, L'Allier PL, Grégoire J, Ibrahim R, McFadden G, et al. (2010) A randomized controlled, phase 2 trial of the viral serpin Serp-1 in patients with acute coronary syndromes undergoing percutaneous coronary intervention. *Circ Cardiovasc Interv* 3: 543-548.
33. Christov A, Korol RM, Dai E, Liu L, Guan H, et al. (2005) In vivo optical analysis of quantitative changes in collagen and elastin during arterial remodeling. *Photochem Photobiol* 81: 457-466.
34. Mehran R, Baber U, Steg PG, Ariti C, Weisz G, et al. (2013) Cessation of dual antiplatelet treatment and cardiac events after percutaneous coronary intervention (PARIS): 2 year results from a prospective observational study. *Lancet* S0140-6736: 61720-61721.
35. Richardt G, Leschke M, Abdel-Wahab M, Toelg R, El-Mawardy M, et al. (2013) Clinical outcomes of the resolute zotarolimus-eluting stent in patients with in-stent restenosis: 2-year results from a pooled analysis. *JACC Cardiovasc Interv* 6: 905-913.
36. Gutman D, Golomb G (2012) Liposomal alendronate for the treatment of restenosis. *J Control Release* 161: 619-627.
37. Versaci F, Gaspardone A, Tomai F, Ribichini F, Russo P, et al. (2002) Immunosuppressive Therapy for the Prevention of Restenosis after Coronary Artery Stent Implantation (IMPRESS Study). *J Am Coll Cardiol* 40: 1935-1942.
38. Ribichini F, Joner M, Ferrero V, Finn AV, Crimins J, et al. (2007) Effects of oral prednisone after stenting in a rabbit model of established atherosclerosis. *J Am Coll Cardiol* 50: 176-185.
39. Montone RA, Sabato V, Sgueglia GA, Niccoli G (2013) Inflammatory

-
- mechanisms of adverse reactions to drug-eluting stents. *Curr Vasc Pharmacol* 11: 392-398.
40. Wessely R, Marzocchi A, Schwacke H, Bertel O, Laanmets P, et al. (2013) Long-term follow-up of coronary venous bypass graft lesions treated with a new generation drug-eluting stent with bioabsorbable polymer. *J Interv Cardiol* 26: 425-433.
41. Okura H, Takagi T, Yoshida K (2013) Therapies targeting inflammation after stent implantation. *Curr Vasc Pharmacol* 11: 399-406.
42. Shu ZW, Yu M, Chen XJ, Tan XR (2013) Ghrelin could be a candidate for the prevention of in-stent restenosis. *Cardiovasc Drugs Ther* 27: 309-314.
43. Miyauchi K, Kasai T, Yokayama T, Aihara K, Kurata T, et al. (2008) Effectiveness of statin-eluting stent on early inflammatory response and neointimal thickness in a porcine coronary model. *Circ J* 72: 832-838.