

## Colour Vision Defect in Patients with High-Tension Glaucoma

Andrea Saifrtová<sup>1</sup>, Jan Lešták<sup>1,2,3\*</sup>, Jaroslav Tintěra<sup>1</sup>, Zuzana Svatá<sup>1</sup>, Lukáš Ettler<sup>1</sup>, Pavel Rozsival<sup>3</sup> and Zuzana Veselá-Florová<sup>1</sup>

<sup>1</sup>JL Clinic, V Hůrkách 1296/10, Praha, Czech Republic

<sup>2</sup>Czech Technical University in Prague, Faculty of Biomedical Engineering, Czech Republic

<sup>3</sup>Charles University Faculty of Medicine in Hradec Králové, Czech Republic

### Abstract

**Objective:** To prove potential difference between black/white and yellow/blue stimulation when using functional magnetic resonance imaging (fMRI) examination in advanced stages of glaucoma disease.

**Methods and materials:** The authors examined eight patients with various stages of high-tension glaucoma using functional magnetic resonance imaging (fMRI). The group was compared to a group of eight healthy persons. Measurements were performed on the Philips Achieva 3T TX MR system using the BOLD method. Optical stimulation was provided by black/white and yellow/blue checkered patterns alternated with their negatives with a frequency of 2 Hz. Each measurement consisted of a sequence with five 30-second periods of active phase and five resting periods of the same length. The obtained data were processed by SPM8 software and GLM. The difference in the number of activated voxels when using the black/white or yellow/blue stimulations was tested by a t-test. Statistical maps of BW>YB and BW<YB differences for patients and controls were thresholded at the uncorrected threshold of  $p=0.001$  and the number of voxels statistically compared by a t-test.

**Results:** The mean value of the difference in the number of activated voxels when using the BW vs. YB stimulation was 59% for the patients while for the controls it was only 2%. While the BW>YB difference between the control group and the patients differed by the statistically significant 1606 voxels ( $p=0.039$ ), no difference was found for BW<YB ( $p=0.18$ ).

**Conclusion:** The authors showed that in the advanced stages of the glaucoma disease functional changes occurred in the cerebral cortex. The colour vision defect in the patients with high tension glaucoma was more significant than the authors had expected.

**Keywords:** Colour vision; High-tension glaucoma; Visual cortex; fMRI

### Introduction

High-tension glaucoma can be defined as a disease where the progressive loss of ganglion cells of the retina and of the subcortical and cortical centres of the brain, and their axons, manifests itself by changes in the visual field and by the atrophy of the optic nerve disc with excavation.

It has been known since 1883 that, in addition to changes in the visual field, the colour vision defects occur as well [1]. This has been confirmed by more recent studies that specify colour vision defects in high-tension glaucoma into the yellow/blue area of the spectrum [2-5]. Colour vision defect progressed with the progressing glaucoma disease [5,7-9].

Based on our previous study "Changes in the Visual Cortex in Patients with High-Tension Glaucoma" [10], we tried to determine if there is a difference between black/white and yellow/blue stimulations in fMRI examination in the advanced stages of glaucoma disease.

### Group of Patients and Methods

Eight patients with different stages of high-tension glaucoma were enrolled in the group (3 females aged 41 - 65 and 5 males aged 40 - 73 years). This group was compared with a group of eight healthy individuals (2 females aged 23 and 55 and 6 males aged 23 - 65 years).

The mean IOP in glaucoma patients, treated with an antiglaucoma topical local treatment was 14 (SD=2.2) mmHg. In the control group the value was 14 (SD=2.4) mmHg.

A comprehensive ophthalmological examination was supplemented

with the visual field using the glaucoma program in the fast threshold program mode which served to determine the stage of the glaucoma disease and was described in the previous study [10]. Pattern defect (PD) is shown in table 1.

All measurements of the functional MR imaging (fMRI) were performed using the Philips Achieva system with a magnetic field of 3T. Measurements were performed using the standard 8-channel RF head sense coil. For the optical stimulation, the ESys (InVivo) commercial stimulation system was used.

BOLD fMRI was measured using a gradient-echo EPI sequence with the following parameters: TE=30 ms, TR=3 s, flip angle of 90°. The measured volume consisted of 39 contiguous slices with thickness of 2 mm and the size of the measured voxel (spatial resolution) was  $2 \times 2 \times 2$  mm (FOV=208 × 208 mm, matrix 104 × 104, reconstruction matrix 128 × 128, SENSE factor of 1.8). Two fMRI measurements were performed for each examination with different types of optical stimulation: In the active phase of the first measurement, the subjects were exposed to alternations of black/white (BW) checkboard pattern (Figure 1a);

**\*Corresponding author:** Jan Lešták, MD, PhD, JL Clinic, V Hůrkách 1296/10, 158 00 Prague 5, Czech Republic, E-mail: [lestak@seznam.cz](mailto:lestak@seznam.cz)


**Received** March 27, 2012; **Accepted** November 06, 2012; **Published** November 12, 2012

**Citation:** Saifrtová A, Lešták J, Tintěra J, Svatá Z, Ettler L, et al. (2012) Colour Vision Defect in Patients with High-Tension Glaucoma. J Clin Exp Ophthalmol 3:252. doi:10.4172/2155-9570.1000252

**Copyright:** © 2012 Saifrtová A, et al. This is an open-access article distributed under the terms of the Creative Commons Attribution License, which permits unrestricted use, distribution, and reproduction in any medium, provided the original author and source are credited.

Subject	BW	YB	BW>YB	YB>BW	2(BW-YB) (BW+YB)	2(YB-BW) (BW+YB)	PD
Patient 1	7400	5900	720	97	11%	1%	4.91/2.71
Patient 2	3700	3500	52	52	1%	1%	2.35/∞
Patient 3	4400	1100	5200	300	189%	11%	2.19/12.85
Patient 4	12100	10900	620	400	5%	3%	11.55/1.61
Patient 5	8500	3600	2640	0	44%	0%	10.59/18.16
Patient 6	3800	60	4080	386	211%	10%	17.76/2.8
Patient 7	8400	6900	550	0	7%	0%	2.73/2.24
Patient 8	4200	2300	0	0	0%	0%	13.26/3.56
Control 1	3800	3200	0	0	0%	0%	0
Control 2	8300	6600	39	0	1%	0%	0
Control 3	3900	5800	170	110	4%	2%	0
Control 4	17700	10600	550	0	4%	0%	0
Control 5	6900	6900	12	35	0%	1%	0
Control 6	7750	4550	46	0	1%	0%	0
Control 7	7150	6980	8	39	0%	1%	0
Control 8	4200	6200	190	580	4%	11%	0

**Table 1:** Table shows the range of activations represented by the number of statistically significant voxels during stimulation by the black/white (BW) and yellow/blue (YB) checkered patterns. The next two columns show the statistically significant differences between BW and YB stimulations, again expressed by the number of voxels (with tested hypothesis being BW >YB, YB >BW resp). The last two columns show the percentage difference in the number of activated voxels of the statistical difference.



**Figure 1:** Shows the stimulation by black/white (BW) checkered pattern (a) and yellow/blue (YB) checkered pattern (b). During the stimulation, the checkered pattern was alternated with its inversion at a frequency of 2 Hz.

while yellow/blue (YB) checkerboard pattern alternations were used in the second measurement (Figure 1b). This alternation was in the form of colour inversion at a frequency of 2 Hz. During the resting phase, the subjects were shown a static cross hair placed in the middle of the visual field. Each measurement consisted of a sequence with five 30-second periods of active phase (10 dynamic scans) and five resting periods of the same length. Therefore, each measurement consisted of 100 dynamic scans and lasted 5 minutes.

The fMRI evaluation was performed in SPM8 software. During the pre-process, the data were corrected for motion (realignment) and time shift of the slices (slice timing) followed by smoothing using Gaussian filter with FWHM of  $6 \times 6 \times 6$  mm and finally normalized into the MNI\_152 space. A general linear model with canonical HRF (hemodynamic response function) applied to the stimulation periods was used for statistical evaluation of all subjects. Individual statistical maps were thresholded at the level of  $p=0.05$  with FWE correction and the minimum cluster size of 10 voxels. The statistical maps of BW>YB and YB>BW differences were thresholded at the level of  $p=0.001$ , without correction, and the minimum cluster size of 10 voxels.

Group statistics were performed using the paired and unpaired t-test with an uncorrected threshold at  $p=0.005$  and the minimum number of uninterrupted voxels of 60 (8 subjects in each group).

## Results

The resulting activations during the optical stimulation for each subject are presented in table 1. The values shown in the table represent the number of activated voxels in the parietal gyrus during the stimulation by black/white (BW) and yellow/blue (YB) checkerboard patterns.

The average number of activated voxels during BW stimulation was 6 563 (SD=3 037) in glaucoma patient group and 7 462 (SD=4 515) in the control group; the extent of activation did not differ statistically. When activated by YB checkerboard, the activation range decreased on average to 4 282 (SD=3 510) in the patient group and to 6 353 (SD=2 148) in the healthy controls.

It can be seen from the table that the difference in the magnitude of activation of the visual cortex during the BW and YB stimulation is markedly higher in the patients with high-tension glaucoma than it is in the healthy controls. The mean value of the difference in the number of activated voxels using the BW vs. YB stimulation is 59% for the patients while for the controls it is only 2%. Statistical maps of BW>YB and BW<YB differences for the patients and controls were thresholded at an uncorrected threshold of  $p=0.001$  and the numbers of voxels were statistically compared using t-test. While the BW>YB difference between the control group and the patients differed by the statistically significant 1606 voxels ( $p=0.039$ ), no difference was found for BW<YB ( $p=0.18$ ).

The maps of significant differences between the BW and YB stimulations were reconstructed using a paired t-test. The results are presented in figure 2. In the controls the difference in activation is only in a narrow region around the medial centre of the occipital gyrus (coordinates in MNI (2,-80,-6)). In the patients this region is enlarged and, in addition, there is a region of significant difference on the lateral surface of the medial occipital gyrus to the left (-44, -72.2) (Figures 2a and 2b). On the other hand, and only in volunteers, a slightly higher activation during YB stimulation was seen bilaterally in the temporal gyri (Figures 2c and 2d).

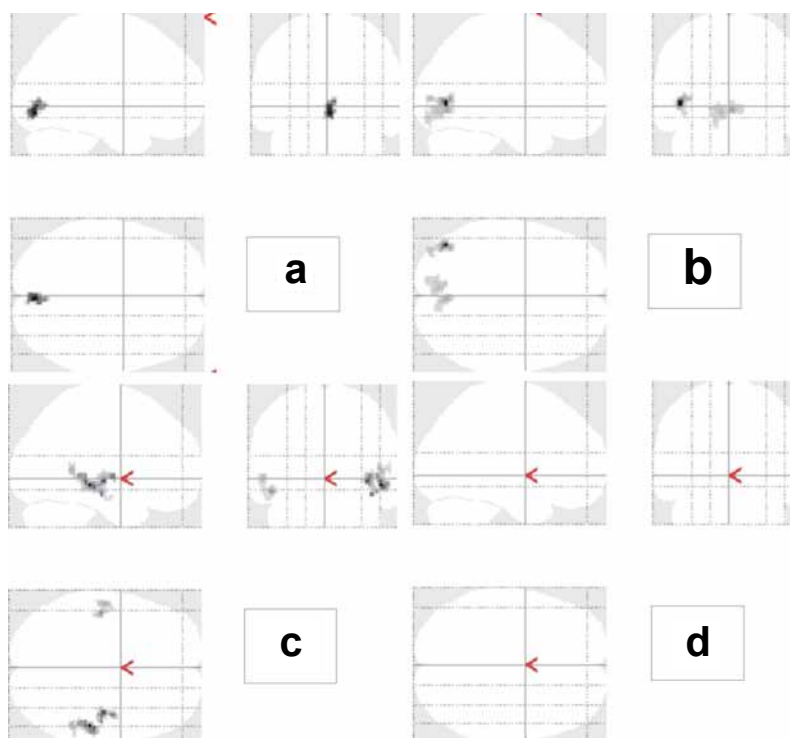
This effect is further supported by the map of the statistical difference between both groups by an unpaired t-test (Figure 3). It shows that particularly the lateral regions of the visual cortex are significantly less activated in patients as compared to controls.

An example of an extreme difference in a patient (patient No. 6) is shown in figure 4. Male, 39 years, VA: 0.3, or 1.0 with correction (-2.0 = -2.5 ax.120 or -1.0 ax.20), IOP 17/13 mmHg (combigan, travatan), c/d = 1.0 or 0.8, visual field pattern defect = 17.76 or 2.8, NFI GDx = 73 or 29. Out of the whole group, this patient exhibited the lowest activation by YB stimulation.

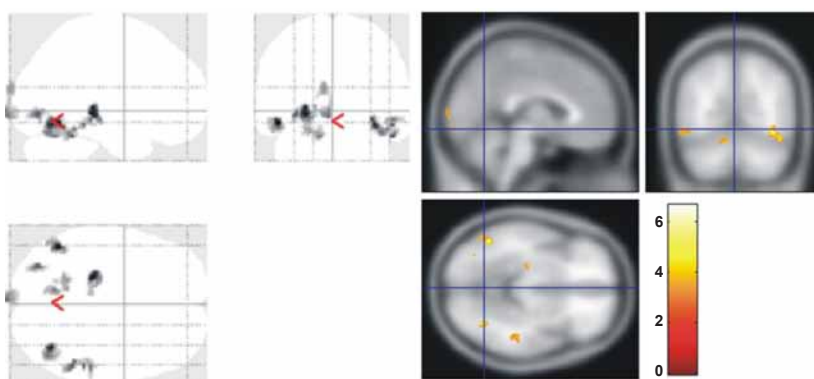
## Discussion

In experimentally induced high-tension glaucoma, the pathology is known to involve the magno-, parvo- and koniocellular pathways [11]. It is unlikely that the glaucoma disease spares any of the cells comprising these pathways. It is the ganglion cells, which are the last in the retina to encode the colour signal.

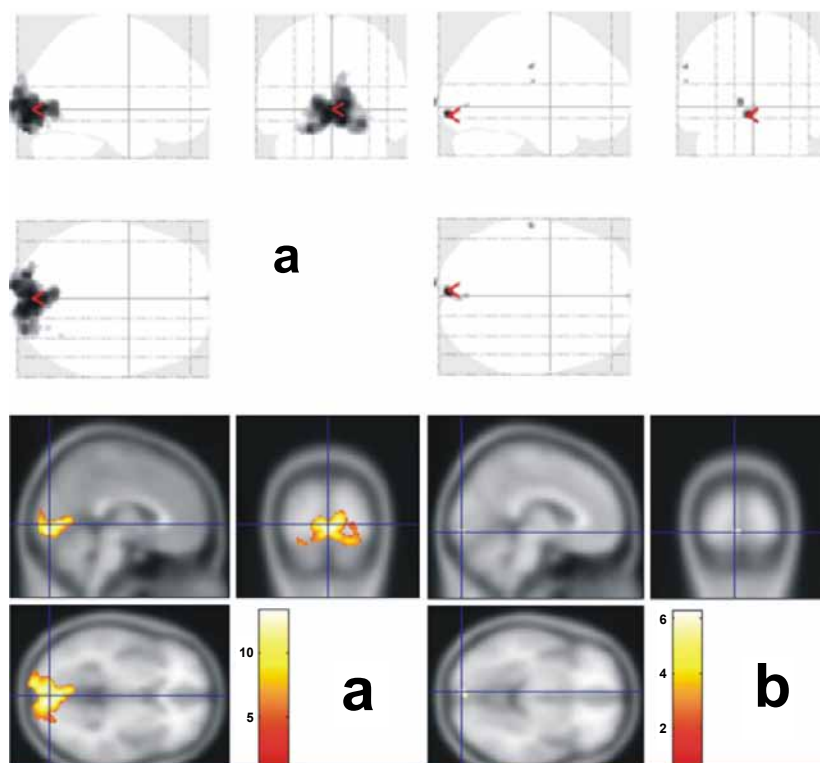
It is not necessary to discuss here the physiology of colour stimuli



**Figure 2:** Shows regions which are activated more significantly during the BW stimulation (top - a, b) and inversely, during the YB stimulation (bottom - c, d). The left column represents results in the controls (a, c) and the right column shows the patients (b, c).



**Figure 3:** Shows regions with statistically more significant activation by YB stimulation in controls versus patients.



**Figure 4:** Patient (No. 6) with the highest difference in the activation range between the BW stimulation (left, a) and YB stimulation (right, b).

processing, from the photoreceptors up to the visual cortex. It is the presence of the pathology in high-tension glaucoma that is of importance.

Therefore, the colour vision defect can be explained by damage or loss of ganglion cells involved in the processing of colour stimuli. The contribution of the L, M and S retinal cones in colour vision defects in high-tension glaucoma remains unclear. The fact that in high-tension glaucoma there may be impairment also at the cone level was shown by Nork [6] who demonstrated an oedema of L/M cones in experimental animals similar to what he observed in human glaucoma retinas. However, the author did not observe any loss of cones. In experimental high-tension glaucoma in monkeys, Greenstein et al. [12] proved that it is primarily the S pathways that are damaged during the early glaucoma changes. The L and M pathways are involved in the process during the more advanced stages of the disease.

We used a yellow/blue checkered pattern to stimulate the colour stimuli processing channels and compared the BOLD results with the black/white structured stimulation (Figure 1).

Blue and yellow colours were chosen intentionally as they include all three opposing colours (red/green the mixing of which results in yellow and yellow-blue). Our results show that the glaucoma process damages the visual cortex more than it is with the black/white pattern stimulation.

There are not many studies dealing with functional magnetic resonance in glaucoma [13,14]. In both studies, the authors showed changes in the visual cortex region in human glaucoma.

In our previous study [10] dealing with patients with various changes in the visual field, we demonstrated not only the damage to

the central nervous system (CNS) in glaucoma but also a correlation between the progression of functional changes in the visual cortex and changes in the visual fields.

It must be emphasised that the measurement of the neuron activity changes using fMRI is not a direct evidence of glaucoma-linked neurodegeneration in CGL or V1. Functional changes in neuron activity in a neuronal disease can be independent of the structural changes of neurons/ axons in the CNS and vice versa. For example, the current fMRI studies have found that neuronal activity in the cortical representation of the fovea centralis persists despite a clear macular retinal pathology with a loss of foveal vision [15,16].

Nevertheless, we believe that, specifically in the high-tension glaucoma, changes in BOLD activity are an evidence of decreased utilisation of oxygen by the reduced number of surviving ganglion cells of the cerebral visual cortex. This assumption is also supported by structural studies by other authors.

Gupta et al. [17] provided a detailed in-depth description of glaucoma pathophysiology along the afferent chain of anatomical changes, from the eye to the superficial layers of the primary visual cortex. Their clinical-pathology case of advanced human glaucoma with loss in the visual fields demonstrated the presence of central neural degeneration at multiple levels of the visual system. Neuropathology in the visual nerves, in the posterior lateral part of CGL and in the visual cortex below calcarine sulcus correlated with the clinical finding as well.

Similar results were also reported by Boucard et al. [18], who examined 8 patients with glaucoma and compared the results with 12 healthy individuals of similar age. They acquired high-resolution



anatomical images of the visual cortex by means of magnetic resonance. Comparison of the grey matter between patients and controls revealed reduction in the density of the visual cortex to which connections entered from retinal lesions. The authors concluded that long-term cortical deprivation resulting from acquired retinal lesions later in life is associated with retinotopic-specific neuronal degeneration of the visual cortex.

## Conclusion

The authors showed that progression of the glaucoma disease is accompanied with functional changes in the visual cortex. Surprisingly, the colour (yellow/blue) stimulation used for fMRI examination revealed far more pronounced changes in the activation of the cortex than the black/white stimulation.

## References

1. Bull O (1883) Bemerkungen über Farbensinn unter verschiedenen physiologischen und pathologischen Verhältnissen. *Albrecht von Graefes Arch Ophthalmol* 29: 71-116.
2. Sample PA, Weinreb RN, Boynton RM (1986) Acquired dyschromatopsia in glaucoma. *Surv Ophthalmol* 31: 54-64.
3. Sample PA, Boynton RM, Weinreb RN (1988) Isolating the color vision loss in primary open-angle glaucoma. *Am J Ophthalmol* 106: 686-691.
4. Drance SM, Lakowski R, Schulzer M, Douglas GR (1981) Acquired color vision changes in glaucoma. Use of 100-hue test and Pickford anomaloscope as predictors of glaucomatous field change. *Arch Ophthalmol* 99: 829-831.
5. Jonas JB, Zäch FM (1990) [Color vision defects in chronic open angle glaucoma]. *Fortschr Ophthalmol* 87: 255-259.
6. Nork TM (2000) Acquired color vision loss and a possible mechanism of ganglion cell death in glaucoma. *Trans Am Ophthalmol Soc* 98: 331-363.
7. Budde WM, Jünemann A, Korth M (1996) Color axis evaluation of the Farnsworth Munsell 100-hue test in primary open-angle glaucoma and normal-pressure glaucoma. *Graefes Arch Clin Exp Ophthalmol* 234 Suppl 1: S180-186.
8. Misiuk-Hojlo M, Nizankowska MH, Regiec P, Raczyska K (2004) [Clinical advantages of colorimetric exploration in the early diagnosis of glaucomatous neuropathy]. *J Fr Ophtalmol* 27: 891-896.
9. Papaconstantinou D, Georgalas I, Kalantzis G, Karmiris E, Koutsandrea C, et al. (2009) Acquired color vision and visual field defects in patients with ocular hypertension and early glaucoma. *Clin Ophthalmol* 3: 251-257.
10. Lešták J, Tintera J, Kyncl M, Svatá Z, Obenberger J, et al. (2011) Changes in the Visual Cortex in Patients with High-Tension Glaucoma. *J Clinic Experiment Ophthalmol*. S4: 002.
11. Yücel YH, Zhang Q, Weinreb RN, Kaufman PL, Gupta N (2003) Effects of retinal ganglion cell loss on magno-, parvo-, koniocellular pathways in the lateral geniculate nucleus and visual cortex in glaucoma. *Prog Retin Eye Res* 22: 465-481.
12. Greenstein VC, Halevy D, Zaidi Q, Koenig KL, Ritch RH (1996) Chromatic and luminance systems deficits in glaucoma. *Vision Res* 36: 621-629.
13. Duncan RO, Sample PA, Weinreb RN, Bowd C, Zangwill LM (2007) Retinotopic organization of primary visual cortex in glaucoma: Comparing fMRI measurements of cortical function with visual field loss. *Prog Retin Eye Res* 26: 38-56.
14. Qing G, Zhang S, Wang B, Wang N (2010) Functional MRI signal changes in primary visual cortex corresponding to the central normal visual field of patients with primary open-angle glaucoma. *Invest Ophthalmol Vis Sci* 51: 4627-4634.
15. Nguyen TH, Stievenart JL, Saucet JC, Le Gargasson JF, Cohen YS, et al. (2004) Cortical response to age-related macular degeneration (Part II). Functional MRI study. *J Fr Ophtalmol*. 27: 3S72-86.
16. Baker CI, Peli E, Knouf N, Kanwisher NG (2005) Reorganization of visual processing in macular degeneration. *J Neurosci*. 25: 614-618.
17. Gupta N, Ang LC, Noël de Tilly L, Bidaisee L, Yücel YH (2006) Human glaucoma and neural degeneration in intracranial optic nerve, lateral geniculate nucleus, and visual cortex. *Br J Ophthalmol* 90: 674-678.
18. Boucard CC, Hernowo AT, Maguire RP, Jansonius NM, Roerdink JB, et al. (2009) Changes in cortical grey matter density associated with long-standing retinal visual field defects. *Brain* 132: 1898-1906.