

# Collaterals from Coronary Artery to Carotid and Subclavian Arteries IN Takayasu's Arteritis: A Rarest Case Report<sup>i</sup>

Gaurav Singhal\* and Vijay Pathak

Department of Cardiology, SMS Medical College and Hospitals, Jaipur, India

## Case Report

Collateral vessel formation is an adaptive response to chronic ischemia with the formation of either new vasculature or the growth of pre-existing small non-significant vessels [1]. It can occur in any vascular bed but it is important especially in coronary ischemia, limb ischemia, and also cerebral ischemia; these collaterals limit the ischemia and play an important role to maintain the blood flow to affected tissue [2]. Cerebral circulation has a unique character with anterior and posterior circulation which meet in the Circle of Willis. Occlusive aortic arch disease is one of the major clinical conditions threatening cerebral circulation. In many cases cerebral circulation is maintained physiologically by posterior circulation to anterior circulation or vice versa. In case of Takayasu arteritis, when severe stenosis occur in aortic arch vessels cerebral ischemia and limb ischemia occurs. Collateral vessels formation starts from one artery to others. However, no case of Takayasu arteritis developing collateral circulation from coronary artery to carotid and subclavian arteries has been reported. Only one case we could find out which was published in 1992 a very long time ago [3]. Since then no such type of case is reported in the literature. Hence we present a case of Takayasu's arteritis with critical carotid stenosis, collaterals from right coronary artery to both carotid arteries and right subclavian artery.

A 19-year-old male was admitted to our hospital with a complaint of recurrent syncope, chronic headache, and gradual bilateral vision loss. He was diagnosed with Takayasu's arteritis 7 months back. Initially patient complained of giddiness, headache which was holocranial, later on patient developed recurrent syncope. Patient also developed blurring of vision on walking which worsened gradually and witnessed gradual vision loss. At the time of presentation he was unable to stand and sit alone and has to remain in supine position to get free from giddiness. There was no history of vomiting, ear ache, and ear discharge. His higher mental functions were normal. All cranial nerves presented normal on examination. Motor and sensory systems were normal. Cerebellar signs were absent, deep tendon reflexes were normal, bilateral planter showed flexion response, no nystagmus present, fundus examination suggestive of bilateral optic atrophy, more in left than right eye. His all routine blood investigations were normal. Hemoglobin was 13.6 gm/dl, serum total proteins, A/G ratio, serum calcium, serum uric acid, serum LDH, serum CPK were within normal limits. On examination, both left and right carotid artery pulsations were absent, all pulses in bilateral upper limb were absent. Blood pressure in both upper limbs was not recordable. no symptoms and signs of limb ischemia. Electrocardiogram was suggestive of left ventricular hypertrophy pattern. Echocardiography showed mild left ventricular hypertrophy, bilateral renal artery Doppler was normal. Carotid-vertebral artery Doppler ultrasonography showed no flow in bilateral common carotid, external carotid and internal carotid arteries and dampened flow (very low monophasic flow) in bilateral subclavian and vertebral arteries. critical stenosis in the carotid arteries and vertebrobasilar system insufficiency. Therefore, Aortography was scheduled. Aortography showed total occlusion of brachiocephalic trunk (Figure 1), left subclavian artery (Figure 2) and the left common

carotid artery (Figure 3) there was also involvement of descending aorta showed some stenosis coronary angiogram was performed to see the effect of vasculitis on coronary beds. There were no coronary stenosis. Surprisingly we found that, there were collaterals from right coronary artery to right carotid and subclavian artery (Figure 4). Hence cerebral circulation was maintained by collaterals originating from right coronary artery. The patient did not describe any anginal symptoms.

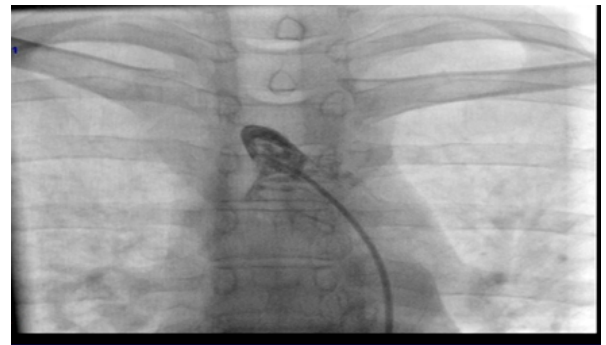

Figure 1: Aortography showing complete occlusion of brachiocephalic trunk.

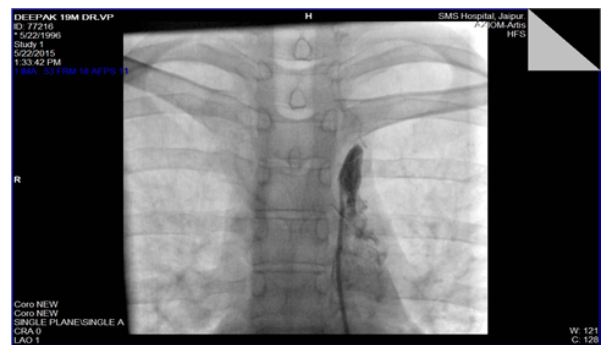

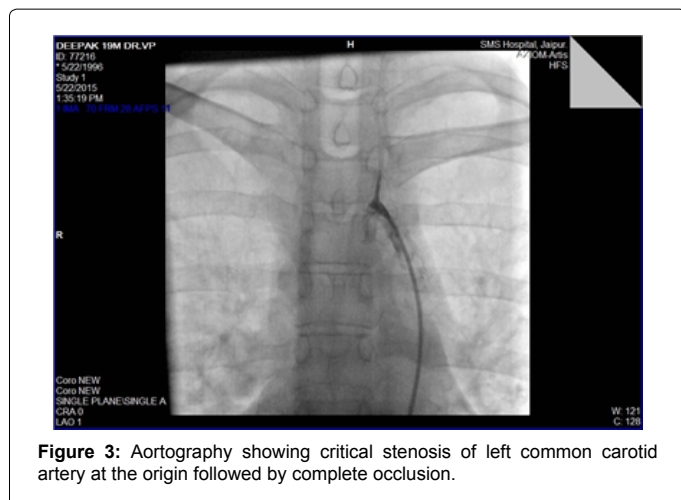
Figure 2: Aortography showing complete occlusion of left subclavian artery from its origin.

\*Corresponding author: Dr. Gaurav Singhal, Department of Cardiology, SMS Hospital, Jaipur, India, E-mail: [dr.garv@gmail.com](mailto:dr.garv@gmail.com)

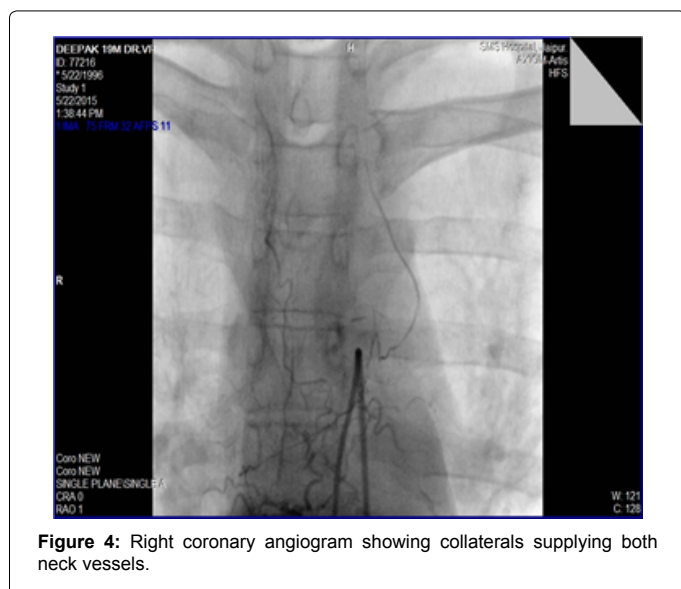
Received August 19, 2015; Accepted August 26, 2015; Published September 02, 2015

Citation: Singhal G, Pathak V (2015) Collaterals from Coronary Artery to Carotid and Subclavian Arteries IN Takayasu's Arteritis: A Rarest Case Report. Angiol 3: 154. doi:10.4172/2329-9495.1000154

Copyright: © 2015 Singhal G, et al. This is an open-access article distributed under the terms of the Creative Commons Attribution License, which permits unrestricted use, distribution, and reproduction in any medium, provided the original author and source are credited.



**Figure 3:** Aortography showing critical stenosis of left common carotid artery at the origin followed by complete occlusion.



**Figure 4:** Right coronary angiogram showing collaterals supplying both neck vessels.

Collateral vessel formation is important in the different clinical conditions including coronary, cerebral, or peripheral vessel occlusive disease. The major triggering factor is chronic ischemia and mediators play a role in the formation of collateral vessels. Collateral vessels supply the ischemic tissue with an alternative circulation pathway and protect the jeopardized tissue [1-3]. Carotid artery stenosis is the major clinical condition that impairs the cerebral circulation. In such cases, posterior circulation via vertebral arteries is the major collateral pathway of cerebral circulation. However, occlusive aortic arch disease affecting subclavian arteries may diminish the posterior cerebral circulation, which may lead to cerebral ischemia. In this condition, collaterals from the abdomen or thoracic vasculature maintain cerebral circulation in some cases. In addition, coronary artery to carotid and subclavian artery collaterals were not reported before.

Takayasu's arteritis is a vasculitis of the great-sized arteries which usually affects the subclavian arteries and carotid system [4]. According to the involvement of vessels, angiographic classification was proposed at the Takayasu conference in 1994 as follows [5]:

**Type 1:** Branches from the aortic arch

**Type 2a:** Ascending aorta, aortic arch, and its branches

**Type 2b:** Ascending aorta, aortic arch, and its branches, thoracic descending aorta

**Type 3:** Thoracic descending aorta, abdominal aorta, and/or renal arteries

**Type 4:** Abdominal aorta and/or renal arteries

**Type 5:** Combined features of types 2b and 4

According to this classification system, involvement of the coronary or pulmonary arteries should be designated as C (+) or P (+), respectively. We classified our patients as type 2b Takayasu's arteritis angiographically, due to involvement of the aortic arch, subclavian arteries, carotid arteries and descending aorta. Collateral circulation was well-developed in the patient with critical stenosis in the involved great arteries. Most of the collateral circulation usually comes from the abdominal vessels, either through internal thoracic arteries or new collaterals from the superior and inferior mesenteric arteries. But in our case there was no collaterals seen from thoracic and mesenteric arteries. Right coronary artery was giving collaterals to both right and left carotid arteries and right subclavian artery. Only one case of direct collateral vessel from coronary circulation was reported in 1992. Thus, our case is probably the second reported case of coronary to carotid and subclavian artery collateral formation associated with Takayasu's arteritis.

In occlusive aortic arch disease, collaterals from different vasculature supplying the neck vessels to maintain the cerebral circulation has been seen but collaterals from coronary artery to neck vessel has not been reported frequently. Hence our case report will act as guide to clinicians and interventionists for detection of such cases and their management.

#### References

1. Hayashi T, Deguchi K, Nagotani S, Zhang H, Sehara Y, et al. (2006) Cerebral ischemia and angiogenesis. *Curr Neurovasc Res* 3: 119–129.
2. Hardman RL, Lepora JE, Cardan RA, Trimmer CK, Josephs SC, et al. (2011) Common and rare collateral pathways in aortoiliac occlusive disease: a pictorial assay. *AJR Am J Roentgenol* 197: 519–524.
3. Hisashi M, Masao Y, Masami n, Shusaku O, Hideo T, et al. (1992) Arteritis With Collaterals Circulation From The Right Coronary Artery to Intracranial vessels-a Case Report. *Angiology* 43: 448–452.
4. Karabulut A, Teskin O (2010) Treatment strategies for coronary lesions in Takayasuarteritis patients – case report and review of the literature. *Kardiol Pol* 68: 1176–80.
5. Moriwaki R, Noda M, Yajima M, Sharma BK, Numano F, et al. (1997) Clinical manifestations of Takayasu arteritis in India and Japan – new classification of angiographic findings. *Angiology* 48: 369–379.